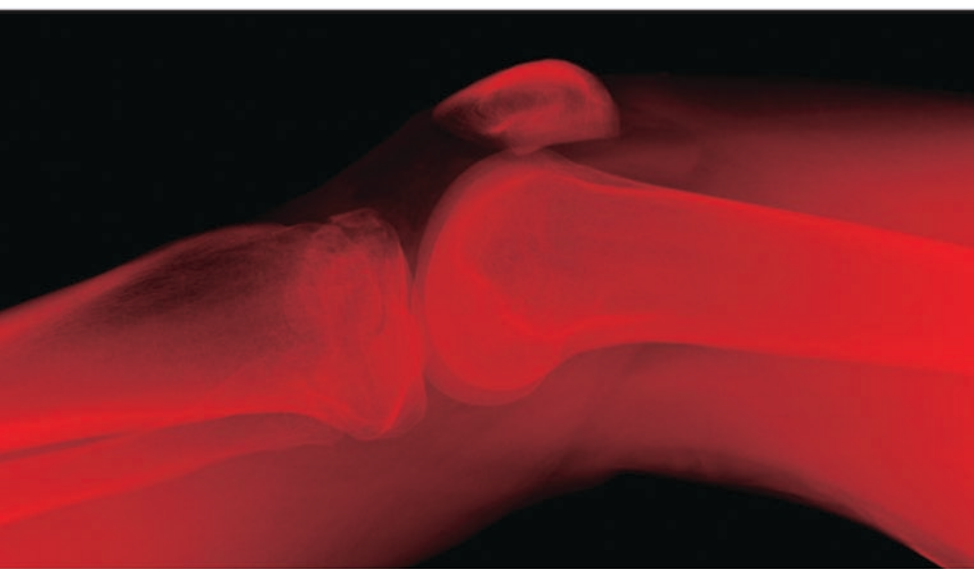


CLARK'S

POCKET HANDBOOK FOR RADIOGRAPHERS

SECOND EDITION



A. STEWART WHITLEY ■ CHARLES SLOANE
GAIL JEFFERSON ■ KEN HOLMES ■ CRAIG ANDERSON



CRC Press
Taylor & Francis Group



CLARK'S

POCKET
HANDBOOK
FOR

RADIOGRAPHERS

SECOND EDITION



Taylor & Francis

Taylor & Francis Group

<http://taylorandfrancis.com>

CLARK'S

POCKET HANDBOOK FOR

RADIOGRAPHERS

SECOND EDITION

A Stewart Whitley, Radiology Advisor
UK Radiology Advisory Services, Preston, Lancashire, UK

Charles Sloane, Principal Lecturer
Department of Medical and Sport Sciences
University of Cumbria, Lancaster, UK

Gail Jefferson, Senior Lecturer/Advanced Practitioner
Department of Medical and Sport Science
University of Cumbria, Carlisle, UK

Ken Holmes, Senior Lecturer
Department of Medical and Sport Sciences
University of Cumbria, Lancaster, UK

Craig Anderson, Clinical Tutor
X-ray Department, Furness General Hospital, Cumbria, UK



CRC Press

Taylor & Francis Group
Boca Raton London New York

CRC Press is an imprint of the
Taylor & Francis Group, an **informa** business

CRC Press
Taylor & Francis Group
6000 Broken Sound Parkway NW, Suite 300
Boca Raton, FL 33487-2742

© 2017 by Taylor & Francis Group, LLC
CRC Press is an imprint of Taylor & Francis Group, an Informa business

No claim to original U.S. Government works

Printed on acid-free paper
Version Date: 20160831

International Standard Book Number-13: 978-1-4987-2699-3 (Paperback)

This book contains information obtained from authentic and highly regarded sources. While all reasonable efforts have been made to publish reliable data and information, neither the author[s] nor the publisher can accept any legal responsibility or liability for any errors or omissions that may be made. The publishers wish to make clear that any views or opinions expressed in this book by individual editors, authors or contributors are personal to them and do not necessarily reflect the views/opinions of the publishers. The information or guidance contained in this book is intended for use by medical, scientific or health-care professionals and is provided strictly as a supplement to the medical or other professional's own judgement, their knowledge of the patient's medical history, relevant manufacturer's instructions and the appropriate best practice guidelines. Because of the rapid advances in medical science, any information or advice on dosages, procedures or diagnoses should be independently verified. The reader is strongly urged to consult the relevant national drug formulary and the drug companies' and device or material manufacturers' printed instructions, and their websites, before administering or utilizing any of the drugs, devices or materials mentioned in this book. This book does not indicate whether a particular treatment is appropriate or suitable for a particular individual. Ultimately it is the sole responsibility of the medical professional to make his or her own professional judgements, so as to advise and treat patients appropriately. The authors and publishers have also attempted to trace the copyright holders of all material reproduced in this publication and apologize to copyright holders if permission to publish in this form has not been obtained. If any copyright material has not been acknowledged please write and let us know so we may rectify in any future reprint.

Except as permitted under U.S. Copyright Law, no part of this book may be reprinted, reproduced, transmitted, or utilized in any form by any electronic, mechanical, or other means, now known or hereafter invented, including photocopying, microfilming, and recording, or in any information storage or retrieval system, without written permission from the publishers.

For permission to photocopy or use material electronically from this work, please access www.copyright.com (<http://www.copyright.com/>) or contact the Copyright Clearance Center, Inc. (CCC), 222 Rosewood Drive, Danvers, MA 01923, 978-750-8400. CCC is a not-for-profit organization that provides licenses and registration for a variety of users. For organizations that have been granted a photocopy license by the CCC, a separate system of payment has been arranged.

Trademark Notice: Product or corporate names may be trademarks or registered trademarks, and are used only for identification and explanation without intent to infringe.

Library of Congress Cataloging-in-Publication Data

Names: Whitley, A. S. (A. Stewart), author. | Sloane, Charles, author. | Jefferson, Gail author. | Holmes, Ken (Kenneth), 1955- author. | Anderson, Craig (Of University of Cumbria), author. | Complemented by (expression): Whitley, A. S. (A. Stewart). Clark's positioning. 13th.
Title: Clark's pocket handbook for radiographers / A. Stewart Whitley, Charles Sloane, Gail Jefferson, Ken Holmes, Craig Anderson.
Other titles: Pocket handbook for radiographers
Description: Second edition. | Boca Raton : Taylor & Francis, 2016. | Accompaniment to Clark's positioning / A. Stewart Whitley [and 5 others]. 13th edition. 2016. | Includes bibliographical references and index.
Identifiers: LCCN 2016039375 | ISBN 9781498726993 (paperback : alk. paper)
Subjects: | MESH: Technology, Radiologic | Patient Positioning | Handbooks
Classification: LCC RC78.4 | NLM WN 39 | DDC 616.07/572--dc23
LC record available at <https://lccn.loc.gov/2016039375>

Visit the Taylor & Francis Web site at
<http://www.taylorandfrancis.com>

and the CRC Press Web site at
<http://www.crcpress.com>

CONTENTS

<i>Preface</i>	ix	Ankle – Antero-Posterior/ Mortise Joint	54
<i>Acknowledgements</i>	xi	Ankle – Lateral	56
Section 1 Key Aspects of Radiographic Practice		Calcaneum – Axial	58
Anatomical Terminology	2	Cervical Spine – Antero- Posterior C3–C7	60
Positioning Terminology	6	Cervical Spine – Antero- Posterior C1–C2	
Projection Terminology	10	‘Open Mouth’	62
Patient Journey and Examination Timeline	14	Cervical Spine – Lateral Erect	64
General Considerations for the Conduct of Radiographic Examinations	17	Cervical Spine – Lateral ‘Swimmers’	66
Patient Identity and Consent	19	Cervical Spine – Lateral Supine	68
Justification for the Examination	21	Cervical Spine – Posterior Oblique	70
Radiation Protection	23	Cervical Spine – Flexion and Extension	72
Medical Exposure and Diagnostic Reference Levels (DRLs)	26	Chest – Postero-anterior	74
Pregnancy	28	Chest – Antero-posterior (Erect)	76
Evaluating Images: The ‘10-point Plan’	30	Chest – Lateral	78
Guidelines for the Assessment of Trauma	34	Chest – Supine (Antero- posterior)	80
Theatre Radiography	36	Chest – Mobile/Trolley (Antero-posterior)	82
Ward Radiography	40	Clavicle – Postero-anterior	84
		Clavicle – Infero-superior	86
		Elbow – Antero-posterior	88
		Elbow – Alternative Antero- posterior Projections for Trauma	90
		Elbow – Lateral	92
		Facial Bones – Occipito-mental	94
		Facial Bones – Occipito-mental 30-degree Caudal	96
		Femur – Antero-posterior	98
		Femur – Lateral	100
Section 2 Radiographic Projections			
Abdomen – Antero-Posterior Supine	47		
Abdomen Antero-Posterior – Left Lateral Decubitus	50		
Acromio-clavicular Joint	52		

Fingers – Dorsi-palmar	102	Lumbar Spine – Lateral	150
Fingers – Lateral Index and Middle Fingers	104	Lumbar Spine – Oblique	152
Fingers – Lateral Ring and Little Fingers	106	Lumbo-sacral Junction (L5–S1) – Lateral	154
Foot – Dorsi-plantar	108	Mandible – Postero-anterior	156
Foot – Dorsi-plantar Oblique	110	Mandible – Lateral Oblique 30-degree Cranial (Supine)	158
Foot – Lateral Erect	112	Orbits – Occipito-mental (Modified)	160
Forearm – Antero-posterior	114	Orthopantomography (OPG/DPT)	162
Forearm – Lateral	116	Pelvis – Antero-posterior	164
Hand – Dorsi-palmar	118	Sacro-iliac Joints – Postero- anterior	166
Hand – Dorsi-palmar Oblique	120	Sacrum – Antero-posterior	168
Hand – Lateral	122	Sacrum – Lateral	170
Hip (Antero-posterior) – Single Hip	124	Scaphoid Postero-anterior with Ulnar Deviation	172
Hip – Lateral Neck of Femur (Trauma)	126	Scaphoid – Anterior Oblique with Ulnar Deviation	174
Hip – Lateral Air-gap Technique	128	Scaphoid – Posterior Oblique	176
Hip – Posterior Oblique (Lauenstein’s)	130	Scaphoid – Postero-anterior, Ulnar Deviation and 30-degree Cranial	178
Hips (Both) – Lateral (‘Frog’s Legs’ Position)	132	Shoulder Girdle – Antero- posterior (15-degree) Erect	180
Humerus – Antero-posterior	134	Shoulder Girdle – Antero- posterior (Glenohumeral Joint) – Modified (Grashey Projection)	182
Humerus – Lateral	136	Shoulder – Supero-inferior (Axial)	184
Knee – Antero-posterior	138	Shoulder – Anterior Oblique (‘Y’ Projection)	186
Knee – Lateral (Basic)	140	Sinuses – Occipito-mental	188
Knee – Horizontal Beam Lateral (Trauma)	142		
Knee – Tunnel/Intercondylar Notch	144		
Knee – ‘Skyline’ Patellar (Supero-inferior)	146		
Lumbar Spine – Antero- posterior	148		

Skull – Occipito-frontal	190	Tibia and Fibula – Lateral	216
Skull – Occipito-frontal 30-degree Cranial (Reverse Towne’s)	192	Toe – Hallux – Lateral	218
Skull – Lateral Erect	194	Toes – Dorsi-plantar	220
Skull – Fronto-occipital (Supine/Trolley)	196	Toes – Second to Fifth – Dorsi-plantar Oblique	222
Skull – Fronto-occipital 30-degree Caudal (Towne’s Projection) (Supine/Trolley)	198	Wrist – Postero-anterior	224
Skull – Lateral (Supine/Trolley)	200	Wrist – Lateral	226
Skull ‘Head’ – CT	202	Zygomatic Arches – Infero-superior	228
Sternum – Lateral	204	Section 3 Useful Information for Radiographic Practice	
Thoracic Spine – Antero- posterior	206	Non-Imaging Diagnostic Tests	232
Thoracic Spine – Lateral	208	Medical Terminology	234
Thumb – Antero-posterior	210	Medical and Radiographic Abbreviations	237
Thumb – Lateral	212	<i>Index</i>	243
Tibia and Fibula – Antero- posterior	214		



Taylor & Francis

Taylor & Francis Group

<http://taylorandfrancis.com>

PREFACE

This second edition of *Clark's Pocket Book for Radiographers* is an accompaniment to the 13th edition of *Clark's Positioning in Radiography*, a comprehensive bench-top guide to radiographic technique and positioning. The authors considered that it is important for radiographers and students to have access to an additional text available in a 'pocket' format that is easily transportable and convenient to use during every day radiographic practice.

Although it has been impossible to include all the radiographic projections from the 13th edition due to restrictions on the size of this book, the authors have included what they consider to be the most commonly used projections. Readers are advised to consult the 13th edition of *Clark's Positioning in Radiography* if they would like guidance in undertaking any projections that have not been included within this book.

The authors have also included a range of additional information that is new to this text. This includes aspects of the patient's journey, ward radiography and the introduction of expected diagnostic reference levels (DRLs), which are based on UK national and regional data.

Following revision, the book includes additional basic information in relation to some non-imaging diagnostic tests, common medical and radiographic terminology and abbreviations. These sections are designed to help readers gain a better understanding of the diagnostic requirements and role of particular imaging procedures from the information presented in diagnostic X-ray imaging requests.

The various projections described in this book have been produced from the 13th edition of *Clark's Positioning in Radiography*. The main changes to the first edition are outlined below.

The title 'Direction and Centring of the X-ray Beam' has been changed to 'Direction and Location of the X-ray Beam' to remind students of the importance of collimating and positioning the beam to include the specific area of interest.

Suggested DRLs have been added to the majority of X-ray examinations as a reminder of the importance of optimisation and keeping a record of patient doses. A basic skull CT examination has been added to reflect the comprehensive role of the radiographer.

The term 'image receptor' implies that either a direct digital detector (DDR), whether portable or fixed, has been used or alternatively images have been acquired using computed radiography (CR) technology with a variety of different CR cassette sizes to match the area of interest. If the radiographer is using CR technology to acquire images, the advice of manufacturers is to undertake one image at a time in the middle of the CR cassette. Failure to do this may result in failure of the image-processing software to correctly identify the region of interest, leading to the production of a sub-optimal image.

Unless otherwise stated, the standard focus-to-receptor distance for all examinations described is 110 cm.

ACKNOWLEDGEMENTS

The authors would like to acknowledge the work of all the authors and the models who posed for the photographs of the 13th edition of *Clark's Positioning in Radiography*.

The book is inspired by the original work and dedication of Kitty Clark and subsequent authors, whose objective was to produce a meaningful and descriptive text for a new generation of radiographers.

Special mention must also be given to: Graham Hoadley, Consultant Radiologist, Blackpool Victoria Hospital; Andrew Shaw, Clinical Scientist, Diagnostic Radiology and Radiation Protection Group, Christie Hospital, Manchester; Dr Marcus Jackson, Associate Professor/Interim Head of School, Kingston University, London; Paul Charnock, Radiation Protection Advisor and Ben Thomas, Technical Officer, both from Integrated Radiological Services (IRS) Ltd., Liverpool; and Angela Meadows, Unit Manager, Alliance Medical Preston PET/CT Centre and BMI Beardwood MRI & CT.

Our thanks also go to Joshua Holmes who ably undertook the new positioning photographs.



Taylor & Francis

Taylor & Francis Group

<http://taylorandfrancis.com>

SECTION 1

KEY ASPECTS OF RADIOGRAPHIC PRACTICE

Anatomical Terminology	2	Medical Exposure and	
Positioning Terminology	6	Diagnostic Reference	
Projection Terminology	10	Levels (DRLs)	26
Patient Journey and		Pregnancy	28
Examination Timeline	14	Evaluating Images:	
General Considerations		The '10-point Plan'	30
for the Conduct of		Guidelines for the	
Radiographic Examinations	17	Assessment of Trauma	34
Patient Identity and Consent	19	Theatre Radiography	36
Justification for the Examination	21	Ward Radiography	40
Radiation Protection	23		

ANATOMICAL TERMINOLOGY

The human body is a complicated structure. Errors in radiographic positioning or diagnosis can easily occur unless practitioners have a common set of rules that are used to describe the body and its movements. All the basic terminology descriptions below refer to the patient in the standard reference position, known as the anatomical position.

Patient Aspect (Figs 1.1a–e)

- Anterior aspect is that seen when viewing the patient from the front.
- Posterior (dorsal) aspect is that seen when viewing the patient from the back.
- Lateral aspect refers to any view of the patient from the side. The side of the head would therefore be the lateral aspect of the cranium.
- Medial aspect refers to the side of a body part closest to the midline, e.g. the inner side of a limb is the medial aspect of that limb.

Planes of the Body (Fig. 1.1f)

Three planes of the body are used extensively for descriptions of positioning both in plain X-ray imaging as well as other cross-sectional imaging techniques. The planes described are mutually at right angles to each other.

- Median sagittal plane divides the body into right and left halves. Any plane parallel to this, but dividing the body into unequal right and left portions, is simply known as a sagittal plane or parasagittal plane.
- Coronal plane divides the body into an anterior part and a posterior part.
- Transverse or axial plane divides the body into a superior part and an inferior part.

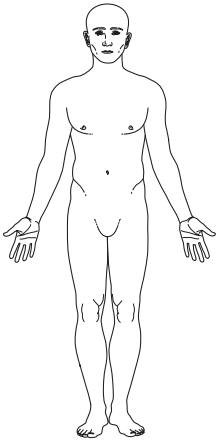


Fig. 1.1a Anatomical position.

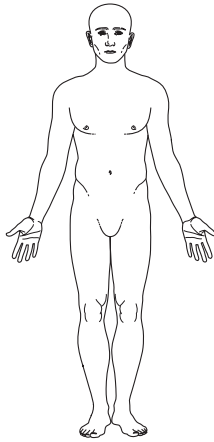


Fig. 1.1b Anterior aspect of body.

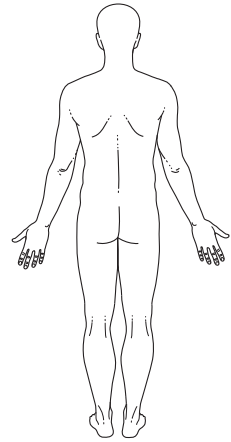


Fig. 1.1c Posterior aspect of body.

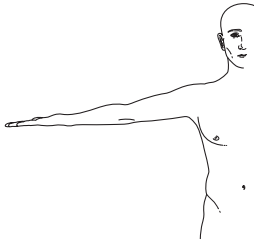


Fig. 1.1d Medial aspect of arm.

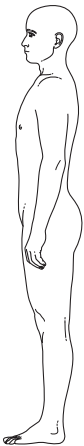

Fig. 1.1e Lateral aspect of body.

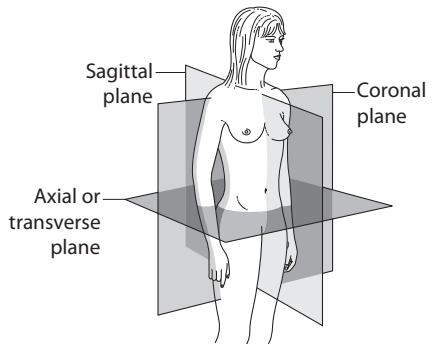


Fig. 1.1f Body planes.

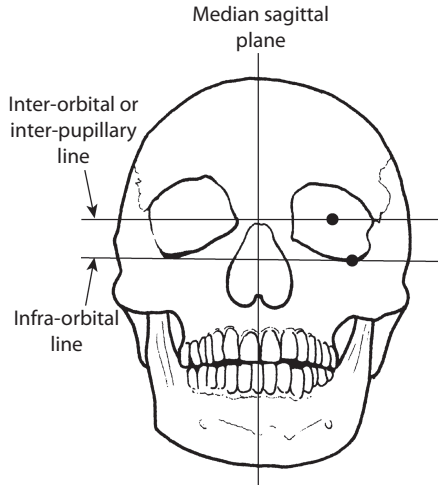
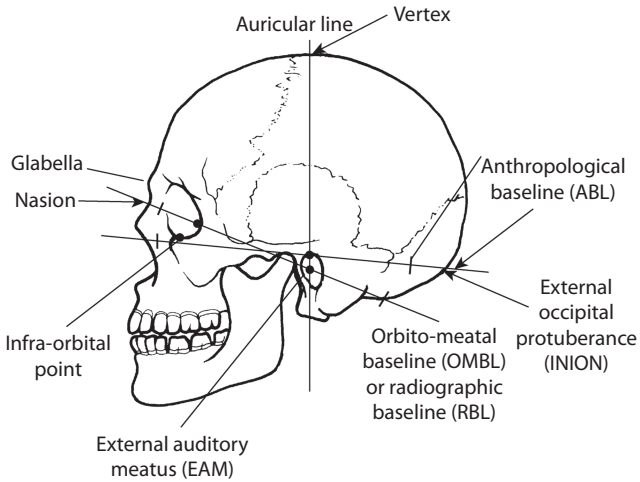
Lines and Landmarks Used in Radiography of the Skull (Figs 1.2a, b)

Landmarks

- Outer canthus of the eye: the point where the upper and lower eyelids meet laterally.
- Infra-orbital margin/point: the inferior rim of the orbit, with the point being located at its lowest point.
- Nasion: the articulation between the nasal and frontal bones.
- Glabella: a bony prominence found on the frontal bone immediately superior to the nasion.
- Vertex: the highest point of the skull in the median sagittal plane.
- External occipital protuberance (inion): a bony prominence found on the occipital bone, usually coincident with the median sagittal plane.
- External auditory meatus: the opening within the ear that leads into the external auditory canal.

Lines

- **Inter-orbital (inter-pupillary) line:** joins the centre of the two orbits or the centre of the two pupils when the eyes are looking straight forward.
- **Infra-orbital line:** joins the two infra-orbital points.
- **Anthropological baseline:** passes from the infra-orbital point to the upper border of the external auditory meatus (also known as the Frankfort line).
- **Orbito-meatal baseline (radiographic baseline):** extends from the outer canthus of the eye to the centre of the external auditory meatus. This line is angled approximately 10 degrees to the anthropological baseline.



Figs 1.2a, b Lines and landmarks of the skull.

POSITIONING TERMINOLOGY

This section describes how the patient is positioned for the various radiographic projections described in this text.

Erect: the projection is taken with the patient sitting (Fig. 1.3a) or standing:

- with the posterior aspect against the image receptor; or
- with the anterior aspect against the image receptor (Fig. 1.3b); or
- with the right (Fig. 1.3e) or left side against the image receptor.

Decubitus: the patient is lying down. In the decubitus position, the patient may be lying in any of the following positions:

- **prone (ventral decubitus):** lying face down (Fig. 1.3c);
- **supine (dorsal decubitus):** lying on their back (Fig. 1.3d);
- **lateral decubitus:** lying on their side: right lateral decubitus – lying on right side; left lateral decubitus – lying on left side (Fig. 1.3f).

Semi-recumbent: the patient is reclining, part way between supine and sitting erect.

All the positions may be more precisely described by reference to the planes of the body. For example, ‘the patient is supine with the median sagittal plane at right angles to the table top’ or ‘the patient is erect with the left side in contact with the image receptor and the coronal plane perpendicular to the image receptor’.

When describing positioning for upper limb projections, the patient will often be ‘seated by the table’. Figure 1.3a shows the correct position to be used for upper limb radiography, with the coronal plane approximately perpendicular to the short axis of the table top. The legs will not be under the table, therefore avoiding exposure of the gonads to any primary radiation not attenuated by the image receptor or table.

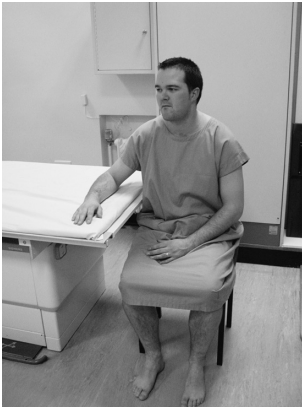

Fig. 1.3a Position for extremity radiography.

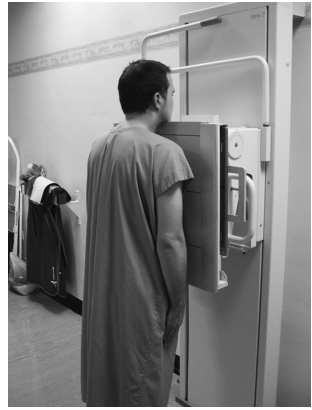

Fig. 1.3b Erect, anterior aspect against Bucky.

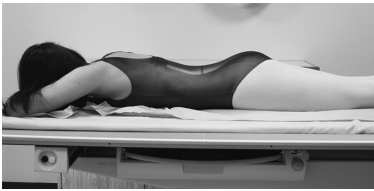


Fig. 1.3c Prone.

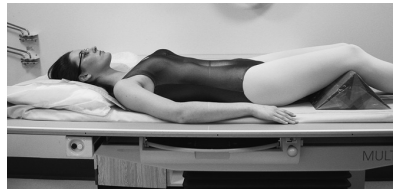

Fig. 1.3d Supine.

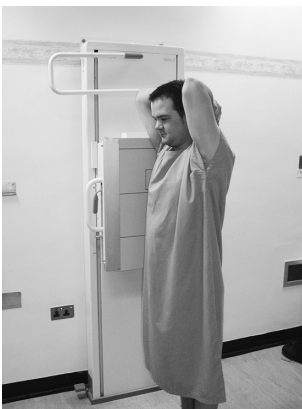

Fig. 1.3e Right lateral erect.

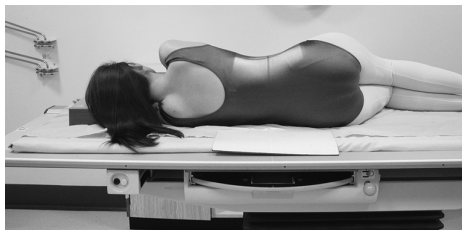


Fig. 1.3f Left lateral decubitus.

Terminology Used to Describe the Limb Position (Figs 1.4a–h)

Positioning for limb radiography may include:

- a description of the aspect of the limb in contact with the image receptor;
- the direction of rotation of the limb in relation to the anatomical position, e.g. medial (internal) rotation toward the midline or lateral (external) rotation away from the midline;
- the final angle to the image receptor of a line joining two imaginary landmarks;
- movements and degree of movement of the various joints concerned.

Extension: when the angle of the joint increases.

Flexion: when the angle of the joint decreases.

Abduction: refers to a movement away from the midline.

Adduction: refers to a movement towards the midline.

Rotation: movement of the body part around its own axis, e.g. medial (internal) rotation towards the midline, or lateral (external) rotation away from the midline.

Supination: a movement of the hand and forearm in which the palm is moved from facing posteriorly to anteriorly (as per the anatomical position).

Pronation: the reverse of supination.

Other movement terms applied to specific body parts are described in the diagrams below.

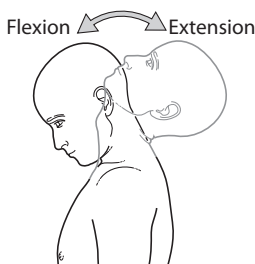


Fig. 1.4a Neck flexion and extension.

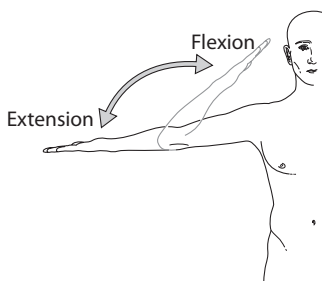


Fig. 1.4b Elbow flexion and extension.

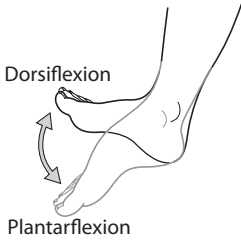


Fig. 1.4c Foot: dorsi- and plantar flexion.

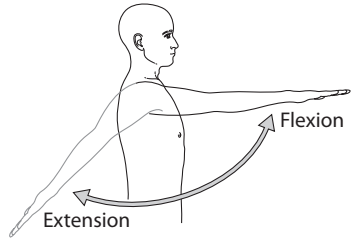


Fig. 1.4d Shoulder flexion and extension.

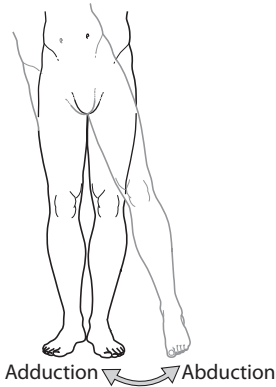

Fig. 1.4e Hip adduction and abduction.

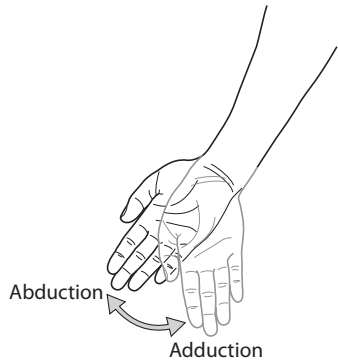


Fig. 1.4f Wrist adduction and abduction.

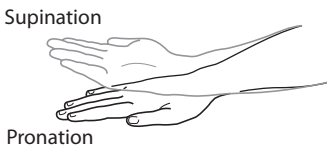


Fig. 1.4g Hand pronation and supination.

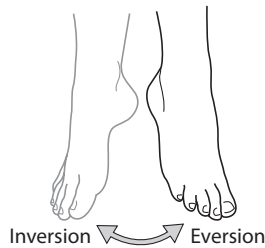


Fig. 1.4h Foot inversion and eversion.

PROJECTION TERMINOLOGY

A radiographic **projection** is described by the direction of the central ray relative to aspects and planes of the body.

Antero-posterior (Fig. 1.5a)

The central ray is incident on the anterior aspect, passes along or parallel to the median sagittal plane and emerges from the posterior aspect of the body.

Postero-anterior (Fig. 1.5b)

The central ray is incident on the posterior aspect, passes along or parallel to the median sagittal plane and emerges from the anterior aspect of the body.

Lateral (Fig. 1.5c)

The central ray passes from one side of the body to the other along a coronal and transverse plane. The projection is called a right lateral if the central ray enters the body on the left side and passes through to the image receptor positioned on the right side. A left lateral is achieved if the central ray enters the body on the right side and passes through to an image receptor that is positioned parallel to the median sagittal plane on the left side of the body.

In the case of a limb, the central ray is either incident on the lateral aspect and emerges from the medial aspect (latero-medial) or is incident on the medial aspect and emerges from the lateral aspect of the limb (medio-lateral). The terms 'latero-medial' and 'medio-lateral' are used where necessary to differentiate between the two projections.

Beam Angulation

Radiographic projections are often modified by directing the central ray at some angle to a transverse plane, i.e. either caudally (angled towards the feet) or with a cranial/cephalic angulation (angled towards the head). The projection is then described as, for example, a lateral 20-degree caudad or a lateral 15-degree cephalad.

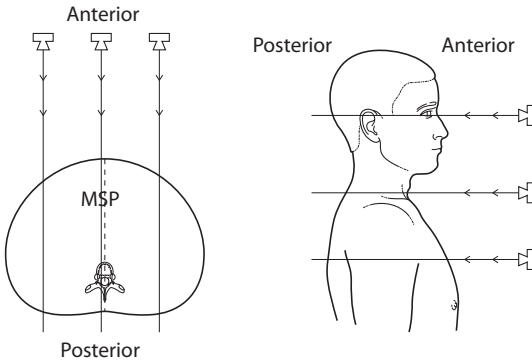


Fig. 1.5a Antero-posterior (AP) projection.

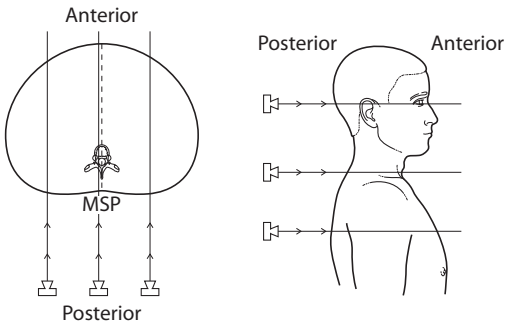


Fig. 1.5b Postero-anterior (PA) projection.

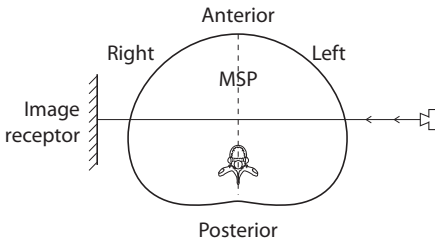


Fig. 1.5c Right lateral projection.

Oblique

The central ray passes through the body along a transverse plane at some angle between the median sagittal and coronal planes. For this projection, the patient is usually positioned with the median sagittal plane at an angle between 0 and 90 degrees to the receptor, with the central ray at right angles to the receptor. If the patient is positioned with the median sagittal plane at right angles to or parallel to the receptor, the projection is obtained by directing the central ray at some angle to the median sagittal plane.

Anterior Oblique (Fig. 1.6a)

The central ray enters the posterior aspect, passes along a transverse plane at some angle to the median sagittal plane and emerges from the anterior aspect. The projection is also described by the side of the torso closest to the cassette. In the figure, the left side is closest to the cassette so the projection is described as a left anterior oblique.

Posterior Oblique (Fig. 1.6b)

The central ray enters the anterior aspect, passes along a transverse plane at some angle to the median sagittal plane and emerges from the posterior aspect. Again the projection is described by the side of the torso closest to the receptor. The figure shows a left posterior oblique.

Oblique Using Beam Angulation (Fig. 1.6c)

When the median sagittal plane is at right angles to the receptor, right and left anterior or posterior oblique projection may be obtained by angling the central ray to the median sagittal plane. NB: This cannot be done if using a grid unless the grid lines are parallel to the central ray.

Lateral Oblique (Fig. 1.6d)

The central ray enters one lateral aspect, passes along a transverse plane at an angle to the coronal plane and emerges from the opposite lateral aspect.

With the coronal plane at right angles to the receptor, lateral oblique projections can also be obtained by angling the central ray to the coronal plane. NB: This cannot be done if using a grid unless the grid lines are parallel to the central ray.

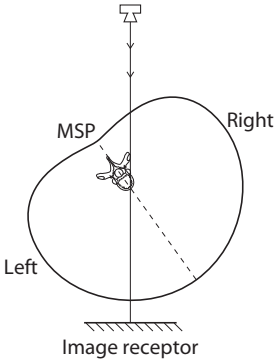


Fig. 1.6a Left anterior oblique projection.

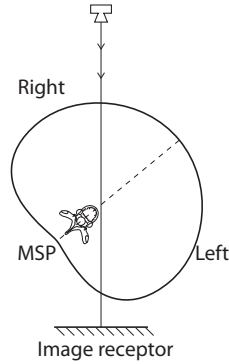


Fig. 1.6b Left posterior oblique projection.

NB: All diagrams are viewed as if looking upwards from the feet.

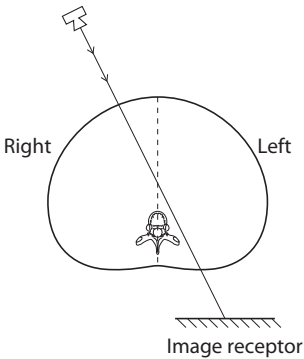


Fig. 1.6c Left posterior oblique obtained using an angled beam.

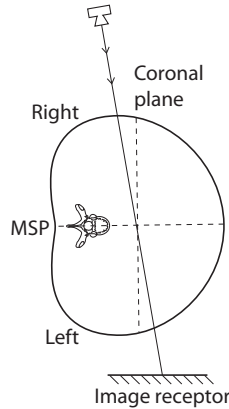


Fig. 1.6d Left lateral oblique projection.

PATIENT JOURNEY AND EXAMINATION TIMELINE

Successful radiography depends on many factors, uppermost of which is the patient's experience during their short journey and encounter with the diagnostic imaging department. The radiographer has a duty of care to the patient and must treat them with respect and ensure their dignity is maintained.

It is essential that the radiographer establishes a rapport with the patient and carers. The radiographer must introduce themselves to the patient/carer and inform them of their role in the examination. They must make sure the request form is for the patient being examined and that the clinical details and history are accurate. Before the radiographer starts the examination, the radiographer must request consent from the patient, and the patient must give consent for the examination.

The flow chart demonstrates a systematic way of undertaking an X-ray examination (Fig. 1.7, page 16). The purpose of the flow chart is to ensure that the patient journey is patient focused and that mistakes are eliminated. The key aspects are:

- effective communication with patients and carers;
- the ability to follow a logical framework to be able to perform the X-ray examination proficiently and effectively;
- efficient use of technology to produce diagnostic images at the first attempt;
- evaluation of the radiographic image using the '10-point plan'.

Stages of an X-ray Examination

There are three stages to undertaking an X-ray examination: preparation, the X-ray examination itself and aftercare, i.e. follow-up of the procedure undertaken. Each of these stages can be further subdivided as shown below.

Preparation for the Examination

- The request form.
- The X-ray room.
- The patient, including consent for the examination and identity checks.

Undertaking the Examination

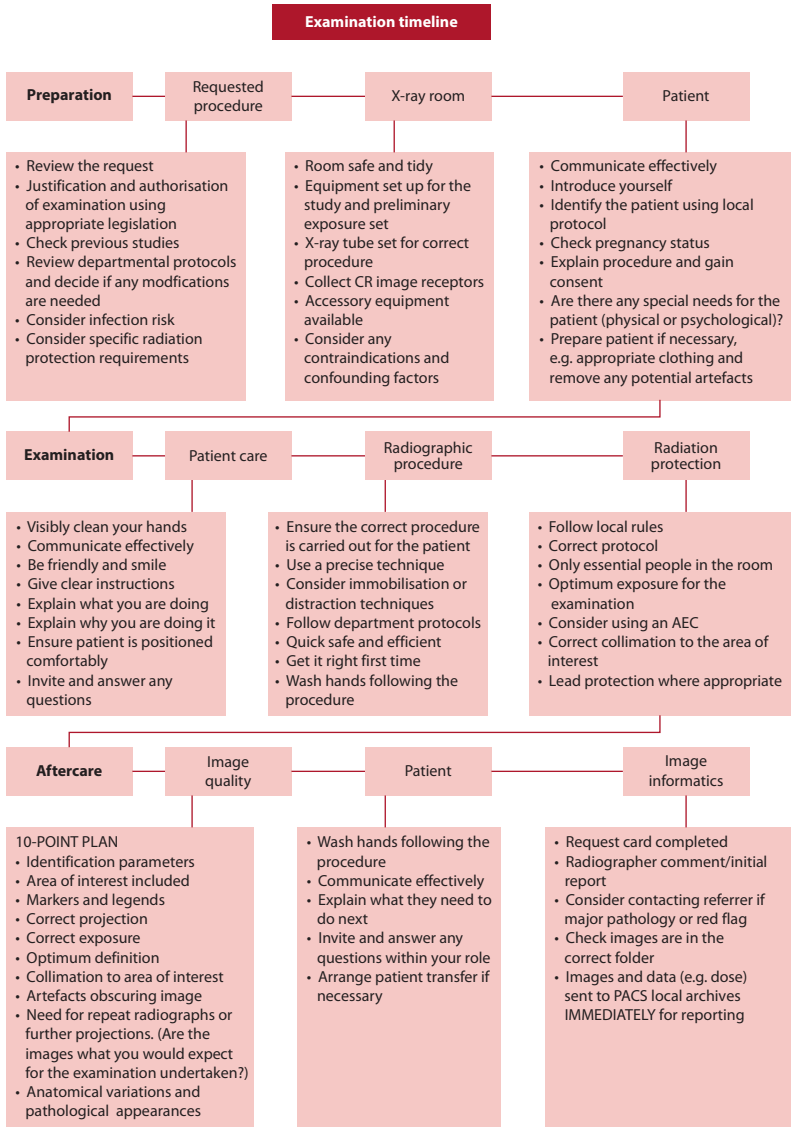
- Patient care.
- Radiographic procedure.
- Radiation protection.

Aftercare and Post-examination

- Image quality.
- Patient aspects.
- Imaging informatics.

Although the algorithm contains several 'main headings', it is essential to emphasise that the primary focus is the patient and their interaction within the process. Effective communication encompasses a myriad of interactions that include being 'open and friendly' to the patient, telling them who you are and what you are intending to do, gaining consent and also inviting and answering any questions patients may have about the examination.

Key Aspects of Radiographic Practice



AEC, automatic exposure control; CR, computed radiography

Fig. 1.7 Flow chart of the patient journey.

GENERAL CONSIDERATIONS FOR THE CONDUCT OF RADIOGRAPHIC EXAMINATIONS

Patient Considerations

- Always introduce yourself to the patient and state your profession.
- Explain the procedure and the patient's role.
- Rehearse any breathing manoeuvres (or similar) if the patient has a limited ability to cooperate.
- Check whether the patient has complied with any preparation instructions, e.g. removal of relevant clothing or jewellery.
- Ask if the patient has any questions or concerns.
- After the examination, inform the patient what they should do next and check they have understood the advice given.

Procedural Considerations

- Always prepare the X-ray room for the procedure prior to the patient entering the room.
- Follow departmental protocols for the examination, e.g. the object-to-receptor distance is normally 110 cm unless otherwise stated.
- If using computed radiography (CR):
 - do not take multiple projections on one receptor/plate as this will confuse image processing algorithms;
 - use the smallest receptor size consistent with size of the body part to maximise resolution.
- Always collimate to the area of interest as excessive field sizes reduce image quality and increase patient dose.
- It is best practice to apply anatomical side markers at the time of the examination and avoid electronic markers when post-processing the image.

Imaging Informatics

In respect to imaging informatics, it is important that the acquired images are viewed carefully using optimised conditions, i.e. that department/manufacture recommendations regarding specific algorithms associated with a body part have been followed, and that any further post-processing has been carefully considered before the images are sent to the picture archiving and communication system (PACS).

The exposure index must have an optimum value to evaluate the patient's exposure and ensure there is minimal or no noise on the image. Exposure details, dose reading and number of images taken are recorded.

PATIENT IDENTITY AND CONSENT

Introduction

It is essential that the radiographer establishes a rapport with the patient and carers. The radiographer must first introduce themselves and inform the patient/carer what to expect during the examination. Then they must make sure the request form is for the patient being examined and the clinical details and history are accurate. The patient/carer's consent must be requested before the examination starts.

Request Form

The radiographer checks the request form to ensure the examination is justified according to:

- ionising radiation regulations;
- department protocols, making sure that the form contains all the required details, i.e. patient demographics, examination requested, authorised signature for the examination and rationale for the examination.
- An explanation of the examination requested is provided.

Patient Identity and Consent

- The patient's identity is established using the departmental protocol, which usually asks the patient to state their full name, address and date of birth. These are then cross-referenced with the request form. The examination must not proceed unless the radiographer is sure of the identity of the patient.
- The procedure is explained to the patient in easy-to-understand terms avoiding medical jargon.

The patient is asked:

- if they have undertaken any required preparation for the examination;
- if they understand the nature of the examination and if they have any questions prior to proceeding;
- for verbal permission to proceed with the examination;
- for written consent if an examination incurs a higher risk, e.g. angiography.

Key Aspects of Radiographic Practice

To be able to give consent (an adult or child), the patient should meet the following criteria, in that they should:

- understand the risk versus benefit;
- understand the nature of the examination and why it is being performed;
- understand the consequences of not having the examination;
- be able to make and communicate an informed decision.

If these conditions are not fulfilled, other individuals, e.g. the parents, may be able to give consent, or in an emergency situation the examination may proceed if it is considered in the best interest of the patient (refer to the hospital's policy).

JUSTIFICATION FOR THE EXAMINATION

Upon receiving a request for an X-ray examination, the radiographer needs to carefully consider whether it is appropriate to undertake the requested examination. In other words – is the examination justified?

The radiographer should consider several questions when assessing any request for imaging:

- **Will the examination change the patient's clinical management?**
Although this can be a contentious area, the radiographer should consider whether the requested examination will be of benefit to the patient and whether the findings will affect the patient's treatment or management.
- **Does the completed request comply with local protocols?**
For example, has the request card been completed in a legible manner? Are the patient demographics correct? Is the requested examination in line with the departmental protocol? Is the referrer identified and working within their referral protocol?
- **Are details of previous operations or other relevant recent imaging included?**
This may have a bearing on the projections taken or the validity of the requested examination.
- **What are the risks and benefits of the examination?**
Even low X-ray doses can cause changes to cell DNA, leading to an increased probability of cancer occurring in the years after the exposure. Although in many cases the probability of this occurring is low, the risk (Table 1.1, page 22) should always be balanced against the benefits to the patient of undergoing the examination. This is often acutely emphasised when seriously ill patients undergo frequent X-ray examinations, so it is very important to carefully consider each request. Consultation with radiological colleagues is often required if there is any doubt over the legitimacy of any request.
- **Does the request comply with government legislation?**
Legislation varies between countries; however, the request should comply with national legislation where applicable.

Key Aspects of Radiographic Practice

In the UK, the underlying legislation is known as the Ionising Radiation (Medical Exposure) Regulations (IR(ME)R) 2000 and IR(ME)R Amended Regulations 2006/2011.

These pieces of legislation are intended to protect patients by keeping doses 'as low as reasonably practicable'. The regulations set out responsibilities for those who refer patients for an examination (referrers), those who justify the exposure taking place (practitioners) and those who undertake the exposure (operators). Radiographers frequently act as practitioners and as such must be aware of the legislation, along with the risks and benefits of the examination, to be able to justify it.

■ Is there an alternative imaging modality?

The use of an alternative imaging modality that may provide more relevant information, or give the required information at a lower radiation dose, should be considered. The use of non-ionising imaging modalities, such as ultrasound and MRI, should also be considered where appropriate.

Table 1.1 Radiation risk for X-ray examinations to an average adult.

Examination	Typical effective dose (mSv)	Risk*
Hand/foot	0.01	1 in a few million
Chest	0.02	1 in 1 000 000
Mammography	0.06	1 in 300 000
Abdomen	0.7	1 in 30 000
Lumbar spine	1.3	1 in 15 000
CT head	2	1 in 10 000
Barium enema	7.2	1 in 2800
CT body	9	1 in 2200

*Additional lifetime risk of fatal cancer.
CT, computed tomography.

RADIATION PROTECTION

The radiographer has a duty of care to ensure that the exposure delivered to the patient conforms to the departmental optimisation policy. This ensures that the 'as low as reasonably practicable' principle has been applied. The radiographer also is responsible for their own protection and that of staff and others involved in the use of ionising radiation.

The following is a list of general principles that can be followed to minimise the dose to patients and staff at various stages of the radiological examination.

Patient

- Explain to the patient the procedure and the need to keep still.
- Make the patient comfortable.

Other Staff and Carers

- Only the required staff should be in the X-ray room.
- If supporting the patient, use lead protection.

Radiographer

- Justify the request.
- Optimise the exposure.
- X-ray the correct patient: check two forms of identification.
- X-ray the correct body part: check against the body part given on the request card and against the patient history.
- Collimate to the area of interest.
- Use a careful technique (no repeated examinations).
- Use optimum exposure factors (diagnostic reference levels [DRLs] are a legal requirement of practice).
- The optimum beam energy (kV) must be used for the examination and imaging system.
- Stand behind the radiation barrier.
- Do not point the X-ray tube in the direction of the radiation barrier or doors (which must be closed).

Additional Considerations

- Prepare the room and set a preliminary exposure before inviting the patient into the X-ray room.
- Always explain what you are trying to achieve and what is expected of the patient.
- Equipment must have regular quality assurance checks to ensure it is working at the optimum level.
- If a patient is worried about the radiation dose they might receive, the following statements can help to put the risk into context:
 - 'You have more chance of drowning in the bath in the next year than you have of getting cancer from a chest/extremity X-ray.'
 - 'An abdominal X-ray carries about the same risk of death as playing a game of football.'
 - 'A computed tomography (CT) head examination carries approximately the same risk of death that the average UK road user faces per year.'

Optimisation of the Exposure

The IR(ME)R regulations state that: 'The practitioner and the operator, to the extent of their respective involvement in a medical exposure, shall ensure that doses arising from the exposure are kept as low as reasonably practicable consistent with the intended purpose.' The regulations also state that the operator shall select equipment and methods to ensure that, for each medical exposure, the dose of ionising radiation ([Table 1.2](#)) to the individual undergoing the exposure is as low as reasonably practicable and consistent with the intended diagnostic or therapeutic purpose. In doing so, the operator must pay special attention to:

- careful and precise technique to minimise repeat examinations;
- quality assurance of the equipment;
- optimisation of exposure factors to provide a diagnostic image within the DRL set for each procedure;
- agreed exposure charts;
- clinical audits of procedures and exposures.

It is therefore important that special attention is paid to these relevant issues to ensure that patient doses are kept to a minimum.

Table 1.2 Radiation dose quantities.

Dose quantities	Unit	Definition
Absorbed dose	Gy	Energy absorbed in a known mass of tissue
Organ dose	mGy	Average dose to specific tissue
Effective dose	mSv	Overall dose weighted for sensitivity of different organs; indicates risk
Entrance surface dose	mGy	Dose measured at beam entrance surface; used to monitor doses and set DRLs for radiographs
Dose–area product	Gy per cm ²	Product of dose (in air) and beam area; used to monitor doses and set DRLs for examinations

DRL, diagnostic reference level.

MEDICAL EXPOSURE AND DIAGNOSTIC REFERENCE LEVELS (DRLS)

Employers have a duty under IR(ME)R to establish DRLs for radiodiagnostic examinations. European reference levels should be considered when setting DRLs. In the UK, such levels have been based on an ongoing series of national patient dose surveys, the latest being *Doses to Patients from Radiographic and Fluoroscopic X-ray Imaging Procedures in the UK 2010 Review* (HPA-CRCE-034), which was published by the Health Protection Agency in June 2012.

The recommended DRLs for the procedures published are based on rounded third-quartile values of the mean patient doses observed for common X-ray examinations in a nationally representative sample of X-ray rooms.

The doses are expressed as the entrance skin dose (mGy), the dose-area product ($\text{Gy}\cdot\text{cm}^2$) or both. The focus is usually on the most frequent or relatively higher dose examinations. [Table 1.3](#) summarises Table 28 of the report with respect to plain radiographic examinations. The report also includes recommended national DRLs for fluoroscopic and interventional procedures.

The DRLs quoted should be used as a reference for comparison with local DRLs. These should be regularly reviewed in light of national guidance or changes in technique and procedures. Additionally, there is a requirement for the employer to undertake appropriate reviews whenever diagnostic levels are consistently exceeded and ensure that corrective action is taken where appropriate. This means that there should be a regular review of patient doses. The operator, i.e. the radiographer, has a legal requirement to optimise the radiation dose, and although individual exposures may vary around the DRL, the average for standard patients should comply with the established level.

In this edition of *Clark's Pocket Handbook for Radiographers*, we quote DRLs (highlighted in red) for the majority of adult individual radiographs described using the currently recommended UK national DRLs ([Table 1.3](#)). For examinations where doses are not listed in the

Medical Exposure and Diagnostic Reference Levels (DRLs)

national table, DRLs (highlighted in grey), which have been calculated on a regional basis by means of electronic X-ray examination records courtesy of Integrated Radiological Services (IRS) Ltd, Liverpool, have been added to individual sections.

Paediatric DRLs are addressed in the paediatric chapter of *Clark's Positioning in Radiography*, 13th edition (Whitley et al, 2016). These DRLs are given as a guide, and readers are referred to their local protocols and procedures, for which where relevant local DRLs should be in place. Dose monitoring on a national level enables DRLs to be established, as well as dose burdens to the population as a whole to be calculated.

Table 1.3 Recommended national reference doses for individual radiographs on adult patients. Table 28 from Health Protection Agency (2012).

Radiograph	ESD per radiograph (mGy)	No. of rooms	DAP per radiograph (Gy cm ²)
Abdomen AP	4	167	2.5
Chest AP	0.2	53	0.15
Chest LAT	0.5	47	
Chest PA	0.15	285	0.1
Cervical spine AP			0.15
Cervical spine LAT			0.15
Knee AP	0.3	40	
Knee LAT	0.3	32	
Lumbar spine AP	5.7	192	1.5
Lumbar spine LAT	10	185	2.5
Pelvis AP	4	204	2.2
Shoulder AP	0.5	34	
Skull AP/PA	1.8	21	
Skull LAT	1.1	21	
Thoracic spine AP	3.5	104	1.0
Thoracic spine LAT	7	104	1.5

AP, antero-posterior; DAP, dose–area product; ESD, entrance skin dose; LAT, lateral; PA, postero-anterior.

PREGNANCY

Avoiding Exposure in Pregnancy

All imaging departments should have written procedures for managing the small but significant radiation risk to the fetus. Radiographers should refer to their departmental working procedures and apply them as part of their everyday working practice. The flow chart (Fig. 1.8) has been constructed using joint guidance from the Health Protection Agency, the College of Radiographers and the Royal College of Radiologists (2009). Most departmental procedures will follow a similar procedure, although practices may vary between departments according to specific circumstances.

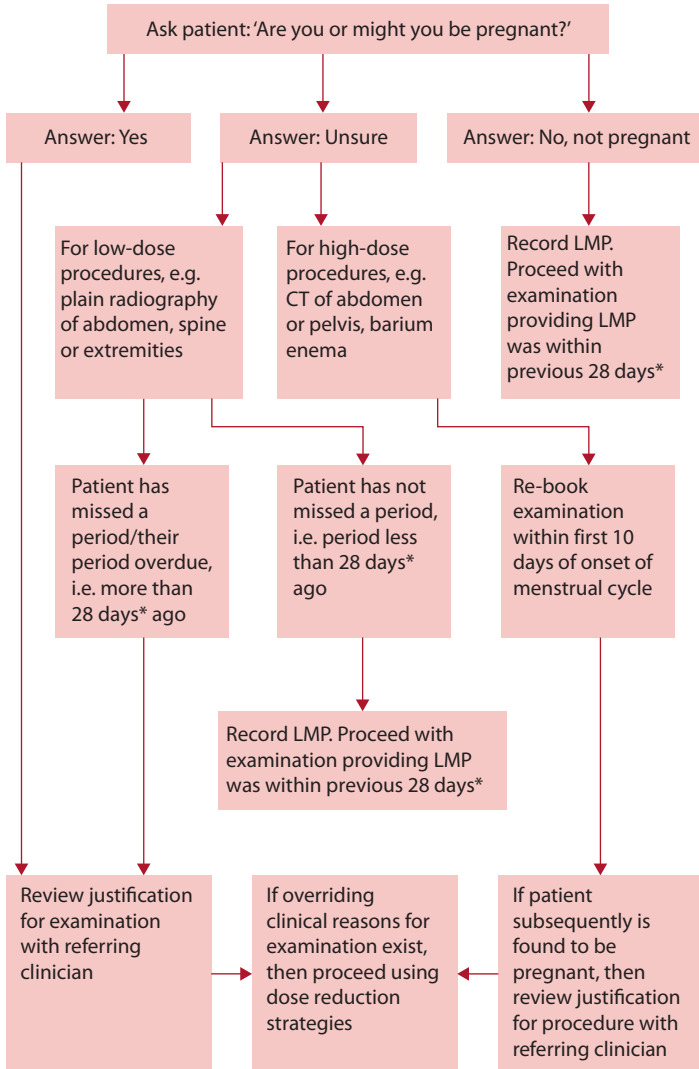
The procedure for pregnancy is usually applied to examinations that include the primary beam exposing the pelvic area. Examinations of other areas can be undertaken as long as the radiographer ensures good beam collimation and employs the use of lead protection for the pelvis.

Evaluating and Minimising Radiation Risks in Pregnancy

A decision to irradiate a pregnant woman will be made in conjunction with the referring clinician, who will have decided that there are overriding clinical reasons to undertake the examination. In such cases, the relatively small radiation risk to the patient/fetus will be outweighed by the benefit of the diagnosis and subsequent treatment of potentially life-threatening or serious conditions. These could present a much greater risk to both parties if left undiagnosed.

To minimise the risks when examining pregnant women, the radiographer should adopt the following strategies:

- use of the highest imaging speed system available, e.g. 800 speed or equivalent settings for computed radiography/direct digital radiography;
- limiting collimation to area of interest;
- use of shielding (can the uterus be shielded without significant loss of diagnostic information?);
- use of the minimum number of exposures to establish a diagnosis;
- use of projections that give the lowest doses;
- use of pregnancy tests if doubt exists.



CT, computed tomography; LMP, last menstrual period

Fig. 1.8 A typical 'pregnancy rule' for women of child-bearing age.

*Some women have menstrual cycles of more or less than 28 days or have irregular cycles.

EVALUATING IMAGES: THE '10-POINT PLAN'

It is imperative that radiographic images are properly evaluated to ensure that they are fit for purpose, i.e. they must answer the diagnostic question posed by the clinician making the request. To do this effectively, the person undertaking the evaluation must be aware of the radiographic appearances of potential pathologies and the relevant anatomy that needs to be demonstrated by a particular projection.

Points to Consider when Evaluating the Suitability of Radiographic Images

1 Patient identification

Do the details on the image match those on the request card and those of the patient who was examined? Such details will include patient name and demographics, accession number, date of examination and name of the hospital.

2 Area of interest

Does the radiograph include all the relevant anatomical areas? The anatomy that needs to be demonstrated may vary depending on the clinical indications for the examination.

3 Markers and legends

Check that the correct anatomical side markers are clearly visible in the radiation field. Ensure the marker that has been used matches the body part on the radiograph and that this in turn matches the initial request from the clinician. Ensure the correct legends, e.g. prone/supine, have been included if they have not been stated in the examination protocol. It is poor practice not to include a marker within the radiation field when making an exposure.

4 Correct projections

Does the acquired image follow standard radiographic technique as outlined throughout the book, with the patient being correctly positioned and the tube being appropriately angled?

It is important to consider the pathology in question and the clinical presentation of the patient. When debating whether

a projection is acceptable, always consider whether the 'diagnostic question' has been answered.

5 Correct exposure (Fig. 1.9)

The evaluation of suitability of the exposure factors used to produce a radiograph will depend on the equipment and medium used to acquire and capture the image.

Conventional film/screen-based imaging

- *Image density*: the degree of image blackening should allow the relevant anatomy to be sufficiently demonstrated, thus allowing diagnosis.
- *Image contrast*: the range of useful densities produced on the radiographic image should correspond to the structures within the area of interest. Each anatomical area should be of sufficient contrast to allow relevant anatomical structures to be clearly visualised.

Digital image acquisition systems

- Given the wide exposure latitude of digital systems, the primary task in image evaluation is to assess for over- or underexposure. The imaging equipment will usually give a numerical indication of the exposure used – the exposure indicator. The reading is compared with a range of exposure limits provided by the manufacturer to see if it is above or below recommended values. At the time of writing a standardised method to compare exposures across different manufacturers has not been fully adopted.

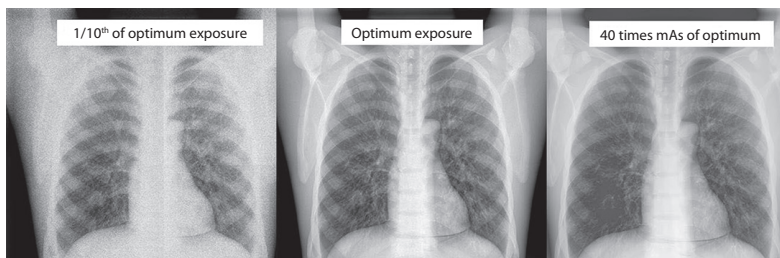


Fig. 1.9 Underexposed image (left), optimum image (middle) and overexposed image (right).

Key Aspects of Radiographic Practice

Underexposure: images that are underexposed will show unacceptable levels of 'noise' or 'mottle' even though the computer screen brightness (image density) will be acceptable (Fig. 1.9, left)

Overexposure: image quality will actually improve as exposure increases due to lower levels of noise. Once a certain point is reached, however, further increases in exposure will result in reduced contrast. Eventually, a point is reached at which the image contrast becomes unacceptable (Fig. 1.9, right).

NB: There is considerable scope for exposing patients to unnecessarily high doses of radiation using digital imaging technologies. When evaluating images, it is important to always use the lowest dose that gives an acceptable level of image noise. The exposure indicator must be in the appropriate range and must fall within national and local DRLs.

6 Optimum definition

Is the image sharp? Look at the bone cortices and trabeculae to ensure movement or other factors have not caused an unacceptable lack of image sharpness.

7 Collimation

Has any of the area of interest been overlooked due to over-zealous collimation? Check the relevant soft tissues have been included. Also look for signs of collimation to evaluate the success of the collimation strategy used. This can then be referred to in future when performing similar examinations. Collimation outside the area of interest will increase the both radiation dose and image noise (due to increased scattered photons).

8 Artefacts

Are there any artefacts on the image? These may be from the patient, their clothing, the equipment or the imaging process. Only repeat the examination if the artefact is interfering with diagnosis.

9 Need for repeat radiographs or further projections

A judgement is made from evaluations 1–8. If one or more factors has reduced the diagnostic quality to a point at which a diagnosis cannot be made, the image should be repeated. Would any additional projections enhance the diagnostic potential of the examination, e.g. radial head projections in relation to an elbow radiograph. If a repeat examination is required, it may be

appropriate to image only the area where there was uncertainty in the initial image.

10 Anatomical variations and pathological appearances

Note anything unusual such as normal variants or pathology that may influence your future actions (see point 9) or aid diagnosis. For example, if an old injury is seen, it may be worth questioning the patient about their medical history. This could then be recorded to aid diagnosis.

GUIDELINES FOR THE ASSESSMENT OF TRAUMA

Background

Radiographers are well placed to offer opinions on plain radiographic images after trauma and can assist the referring clinician with the identification of fractures, dislocations and associated 'signs', such as fluid levels. In the UK, the practice of 'red-dotting' is well established and involves the radiographer placing a red dot or similar marker on the image to indicate the presence of an abnormality.

Developments in the Role of the Radiographer

In the UK, the basic system of placing a red dot has developed into a three-tier system of radiographer opinion:

- 1 **Red dot:** a basic system of flagging a possible abnormality, such as a fracture.
- 2 **Comment system:** the radiographer attaches a simple comment to the image to explain their concern.
- 3 **Clinical report:** trained radiographers produce a detailed report, usually some time after the examination, that is sent to the referring clinician.

Most radiographers, especially newly qualified practitioners, will be working to develop their skills related to the 'red-dot' and 'commenting' systems.

Suggestions for Successful Image Interpretation

- 1 **Gain an oral clinical history:** obtaining a clinical history from the patient can be especially helpful for the radiographer to produce the correct projections that will demonstrate the injury and provide a greater understanding of the area to check for injury. Modern PACSs also allow the radiographer to convey any relevant clinical history to the person providing the final radiological report.

- 2 **Produce high-quality radiographs:** poor images are especially difficult to interpret, diminishing the ability to exclude fractures with confidence.
- 3 **Use a logical system for checking:** many different approaches to evaluating radiographs are suggested in the radiology literature, e.g. looking at the alignment, then the bones, followed by the cartilage, etc. Many useful lines and measurements are used to check for abnormalities, e.g. 'McGrigor's three lines' for evaluating the facial bones. Whichever system is used, try to apply it consistently and logically; this should reveal many subtle injuries.
- 4 **Utilise a system of pattern recognition:** carefully trace the cortical outlines of each bone, looking for any steps, breaks or discontinuities. Radiographers are used to seeing a large number of 'normal' examinations and as such are well placed to use this knowledge to identify any changes in the normal 'pattern' of bones and joints. After checking the cortical margins, carefully assess the cancellous components of the bones, looking for discontinuities in the trabecular pattern that might indicate a fracture.
- 5 **Pay attention to 'hot-spots':** these are frequent sites of bony injury, e.g. the neck of the fifth metacarpal, the base of the fifth metatarsal, the dorsal aspect of the distal radius and the supracondylar region of the humerus in children. The way the patient presents or reacts to positioning frequently gives strong clues as to the position of the injury.
- 6 **Be aware of the indirect signs of a fracture:** for example, be able to identify and recognise the significance of an elbow joint effusion or a lipohaemarthrosis (fat–blood interface within the knee or shoulder joint), both of which can be associated with an underlying fracture.
- 7 **Look for the second fracture:** there is an old saying, 'if you spot one fracture, look for another', and a common mistake is to identify a fracture but miss a second by not checking the entire image. Be aware of principles such as the 'bony ring rule', which states that if a fracture or dislocation is seen within a bony ring (e.g. the pelvis), a further injury should be sought as there are frequently two fractures.

THEATRE RADIOGRAPHY

Introduction

Theatre radiography plays a significant role in the delivery of surgical services. The radiographer may be required for emergency procedures or planned surgery in both trauma and non-trauma procedures.

Considerations for the radiographer include the following.

Key Skills for Theatre

Key skills for the radiographer in theatre are:

- how to use the equipment correctly;
- effective communication;
- personal preparation;
- safe practice;
- production of diagnostic images;
- radiation protection of staff and patients;
- infection control;
- teamworking.

Effective use of the Equipment

A mobile X-ray unit or mobile fluoroscopy unit is selected depending on the requirement of the radiographic procedure. Thus, a mobile X-ray unit may be used for plain chest radiography, while a mobile fluoroscopy unit may be used for the screening of orthopaedic procedures such as hip pinning.

Before use in the procedure, a mobile fluoroscopy unit should be assembled and tested to ensure it is functioning effectively prior to patient positioning.

Effective Communication

The radiographer must contact the theatre manager upon arrival and maintain a close liaison with all individuals performing the operation, consequently working as part of the multidisciplinary team.

The radiographer must be familiar with the layout and protocols associated with the theatre to which they are assigned, demonstrate a working knowledge of the duties of each person in the operating theatre and ascertain the specific requirements of the surgeon who is operating.

Personal Preparation

Personal preparation is the first concern of the radiographer before entering an aseptic controlled area.

The radiographer must remove their uniform (and any jewellery) and replace it with theatre wear. The hair is covered completely with a disposable hat. Theatre shoes or boots are worn, and a face mask is put on. In addition, a radiation-monitoring badge is pinned to the theatre garments.

Special attention is made to washing the hands using soap, ensuring that they are washed before and after each patient. Skin abrasions should be covered with waterproof dressings.

Image receptor holders, stationary grids and other imaging devices should be cleaned and checked if required.

Contrast media, if required, should also be supplied to the theatre staff.

Time Out

It is now common practice in operating theatres to call a 'time out' with the operating team before the operation starts. This is used to stop errors being made in the procedure and to discuss any issues or anticipated safety concerns, e.g. patient allergies or anticipated complications. The areas listed below are checked in the presence of the surgeon, operating nurse, anaesthetist and radiographer. It is usual to have the signed consent form from the patient and a wristband on the patient as a reference point. Preoperative checks include:

- patient identification;
- signed consent for the procedure;
- the operation being undertaken and the relevant anatomical side;
- a check for methicillin-resistant *Staphylococcus aureus* (MRSA);
- a pregnancy check if appropriate;
- a review of previous radiographic images stored on the PACS.

PACS Connectivity

In many theatre suites, it is customary for the X-ray equipment to be housed within the suite, and a PACS/digital imaging and communications in medicine link should be established to facilitate image capture and the retrieval of previous examinations. Patients need to be accessed via the PACS prior to the procedure to allow the images to be stored in the correct files.

Radiation Protection

Radiation protection is the responsibility of the radiographer operating the X-ray equipment. Therefore, the radiographer should ensure that radiation monitoring badges, lead protective aprons and thyroid shields are worn by all staff when in the controlled area (2 m from the X-ray tube). Furthermore, as soon as the imaging equipment is switched on, a controlled area exists (IRR'99 Regulation 17). Therefore all doors that provide access to the controlled area must display radiation warning signs, and personnel who are not required must leave the theatre.

- The patient's identity must be confirmed with either the anaesthetist or an appropriate member of the theatre team, or with the patient if they are awake, before starting image acquisition.
- The radiographer should not be surprised if the surgeon wants to screen while rotating the limb or during a dynamic screwing. Fluoroscopy is a dynamic process, and if plain images are adequate it is better to use a digital mobile X-ray unit as the image quality is better.
- Intelligent collimation to the area of interest when using fluoroscopy will reduce radiation dose and scatter, improving image quality.
- The inverse square law principle must be applied in the theatre environment. Therefore, staff must be standing at the maximum distance from the source of radiation and outside the path of the radiation field during exposure.
- The radiographer must minimise the dose to the patient and staff by using dose-saving facilities (a half-dose or pulsed beam) and minimising fluoroscopy times. Fluoroscopy should be undertaken only when the surgeon indicates that it is required and when some intervention has been made on the patient since the previous screen.

- Before any exposures are made, the radiographer must give clear instructions to the staff regarding their role in order to reduce the risk of accidental exposure.
- It is a legal requirement to record the screening time and radiation dose for each patient examination. This should be regularly monitored to ensure the doses are as low as is reasonably practicable.

Sterile Procedures/Infection Control

Equipment used in operating theatres must be kept clean and stored in the theatre environment. It must be cleaned regularly and prior to and after every case. The radiographer should dress in scrubs and wear approved footwear, theatre hat and mask if required. Not all theatre cases require full sterile protection so the equipment should be appropriately protected and covered to shield the patient from infection and the equipment from damage.

If a sterile procedure is required and in all invasive procedures where the skin is pierced, the mobile fluoroscopy unit must be appropriately covered with sterile plastic coverings or drapes. Sterile procedures are an everyday occurrence for the theatre staff so they can easily provide help and guidance.

The radiographer should avoid contaminating sterile areas. Ideally, equipment should be positioned before any sterile towels are placed in position and care should be taken not to touch sterile areas when positioning the C-arm or moving equipment during the operation, unless it is draped.

WARD RADIOGRAPHY

Radiography using mobile X-ray equipment should be restricted to the patient whose medical condition is such that it is impossible for them to be moved to the X-ray department without seriously affecting their medical treatment and nursing care.

Key Skills for Mobile/Ward Radiography

- How to use the equipment correctly.
- Effective communication.
- Red flags.
- Radiation protection of staff and patients.
- Infection control.
- Personal preparation.
- Safe practice.
- Production of diagnostic images.
- Teamworking.

General Comments

Examinations are normally complicated by a variety of situations:

- the need to communicate effectively to complete the examination without harming the patient's progress/recovery and with minimum disruption to the ward;
- the patient's medical condition, degree of consciousness and level of cooperation;
- the patient's treatment and restrictions due to life-support systems, drips and chest or abdominal drains;
- traction apparatus;
- physical restrictions because of room size and the ability to move mobile or portable X-ray equipment in confined spaces;
- the need to monitor the patient and life-support equipment.

Correct Use of the Equipment

- A mobile X-ray unit is selected depending upon the requirement of the radiographic procedure. For example, a mobile X-ray unit may be

situated permanently in an area that undertakes mobile examinations on a routine basis, or may need to be transported to a ward which infrequently undertakes such examinations.

- To prevent infection, the unit selected and image detectors should be cleaned and dried before and after each patient.
- Patient demographics may be entered into the radiology information system (RIS)/PACS, and the exposure parameters adjusted to those required for the examination. The radiographer must be able to assume total control of the situation and should enlist the help, cooperation and advice of nursing and medical staff before embarking on an examination. A thorough knowledge of the ward is necessary so that problems or difficulties can be resolved with the minimum of fuss.
- X-ray requests should first be checked to ensure that it is necessary to examine on the ward and that the correct equipment and detectors are obtained for transfer to the ward.
- Patient identification protocols should be correctly applied.
- Detectors used must be clearly marked to avoid double exposure if more than one patient needs to be examined on the ward.
- Advice regarding the patient's medical condition should be sought before moving or disturbing the patient. Any disturbance of traction, ECG leads or drains should be undertaken only with the permission and assistance of the medical staff. Positioning of the image receptor and movement or lifting of seriously ill patients should be undertaken with the cooperation of and under supervision by nursing staff.

Effective Communication

The radiographer must communicate effectively with the ward staff before, during and after the mobile X-ray examination. The key to a stress-free experience is preparation. It is essential that there is a mechanism for ward staff to communicate effectively and give the radiographer as much notice as possible for all mobile requests. This enables the radiographer to use their time more effectively and not be kept waiting due to the patient's or ward's management.

The radiographer needs to be informed of the:

- justification for the examination to be undertaken using mobile equipment;

Key Aspects of Radiographic Practice

- urgency of the request;
- patient's condition and whether they are being nursed on life support;
- infection status (Control of Infection).

Following the procedure, the radiographer must ensure the ward staff and referrer know when the image will be available on the PACS and when a report will be available. All exposures require an evaluation under the IR(ME)R 2000 regulations.

Red Flags

If the patient's X-ray examination demonstrates a 'life-threatening' or unexpected appearance, e.g. a nasogastric tube positioned in the lung rather than the stomach, the radiographer has a duty of care to the patient and the referrer. The ward and clinician should be informed immediately.

Radiation Protection

This is of paramount importance when mobile radiography is undertaken:

- The radiographer is responsible for ensuring that there is a controlled area of 2 m during the exposure and that local rules are adhered to during the examination.
- On arriving on the ward, the radiographer must liaise clearly with the ward staff and issue verbal instructions in a clear and distinct manner to staff and patients to avoid accidental exposure to radiation.
- Anyone assisting in an examination must be protected adequately from scatter radiation by the use of personal protective equipment. The inverse square law should be applied to ensure that staff stand outside the controlled area and as far away as possible from the X-ray unit.

The patient should also receive appropriate radiation protection. Protective lead shields may be used as a precautionary measure to limit the radiation field when using a horizontal beam, e.g. when the absorption nature of room-dividing walls is unknown. Exposure factors used in the examination should be recorded, enabling optimum results to be repeated. Patients tend to be X-rayed frequently when under intensive care.

Control of Infection

Infection control plays an important role in the management of all patients, especially after surgery and for premature babies.

To prevent the spread of infection, local established protocols, e.g. hand-washing before and after every patient, should be adhered to by staff coming into contact with patients. In addition, detectors and X-ray equipment used for radiographic examination must be cleaned before, between and after each examination. Patients with a known highly contagious infection, and those with a compromised immune system and a high risk of infection, will be isolation-nursed (barrier-nursed; see below). In such circumstances, it is important that local protocols to prevent the spread of infection are followed.

The X-ray equipment used in ICU, cardiac surgery units and special care baby units should, ideally, be dedicated units that are kept on site. If shared with other areas in the hospital, they should be cleaned with disinfectant solution before being moved into infection-controlled units. Equipment must be wheeled over dust-absorbent mats at the entrance of such units.

Radiographers should wear gowns or disposable plastic aprons, face masks and overshoes before entering these areas. Disposable gloves must be worn when touching the patient.

Image receptors should be cleaned and covered with plastic sheets or clean pillowcases or towels before use. After use, image receptors and all equipment should be cleaned with antiseptic solution.

MRSA and *Clostridium difficile* are hospital-acquired bacterial infections that readily spread from an infected patient to others, usually via hand contact. MRSA is resistant to methicillin and many other antibiotics and is a particular threat to vulnerable patients. It causes many symptoms, including fever, wound and skin infections, inflammation and pneumonia.

When healthcare workers deal with potentially infected patients, the bacteria may transfer to their hands and can then be passed on to vulnerable patients.

Patients therefore need to be isolation/barrier-nursed. Controls such as effective hand-washing, wearing of gloves and aprons, and cleaning of the environment and equipment are necessary to prevent the spread of the bacteria.

Key Aspects of Radiographic Practice

When undertaking radiography on more than one barrier-nursed patient on a ward or ICU, it is important that disposable aprons are changed and operators' hands washed between patients to prevent the spread of infection. Some specialty wards use differently coloured aprons for each patient bay as a prompt to confine the use of aprons to a specific patient.

Isolation/Reverse Barrier Nursing

Isolation nursing is required to reduce the risk of spreading certain infections or antibiotic-resistant germs to other patients and staff. It is also applied to protect patients from infection if they have a compromised immune system as a result of disease, transplant surgery or certain drugs.

- **Isolation nursing:** the patient is placed in a single room or side room.
- **Barrier nursing:** this occurs when the patient is kept in a bay and extra precautions are implemented to prevent spread of infection.

NB: To prevent the spread of infection in relation to patients being isolation/barrier-nursed, there are specific protocols using two members of staff to undertake the X-ray.

SECTION 2

RADIOGRAPHIC PROJECTIONS

Abdomen – Antero-posterior Supine	47	Clavicle – Infero-superior	86
Abdomen Antero-posterior – Left Lateral Decubitus	50	Elbow – Antero-posterior	88
Acromio-clavicular Joint	52	Elbow – Alternative Antero- posterior Projections for Trauma	90
Ankle – Antero-posterior/ Mortise Joint	54	Elbow – Lateral	92
Ankle – Lateral	56	Facial Bones – Occipito-mental	94
Calcaneum – Axial	58	Facial Bones – Occipito- mental 30-degree Caudal	96
Cervical Spine – Antero- posterior C3–C7	60	Femur – Antero-posterior	98
Cervical Spine – Antero- posterior C1–C2 ‘Open Mouth’	62	Femur – Lateral	100
Cervical Spine – Lateral Erect	64	Fingers – Dorsi-palmar	102
Cervical Spine – Lateral ‘Swimmers’	66	Fingers – Lateral Index and Middle Fingers	104
Cervical Spine – Lateral Supine	68	Fingers – Lateral Ring and Little Fingers	106
Cervical Spine – Posterior Oblique	70	Foot – Dorsi-plantar	108
Cervical Spine – Flexion and Extension	72	Foot – Dorsi-plantar Oblique	110
Chest – Postero-anterior	74	Foot – Lateral Erect	112
Chest – Antero-posterior (Erect)	76	Forearm – Antero-posterior	114
Chest – Lateral	78	Forearm – Lateral	116
Chest – Supine (Antero- posterior)	80	Hand – Dorsi-palmar	118
Chest – Mobile/Trolley (Antero-posterior)	82	Hand – Dorsi-palmar Oblique	120
Clavicle – Postero-anterior	84	Hand – Lateral	122
		Hip (Antero-posterior) – Single Hip	124
		Hip – Lateral Neck of Femur (Trauma)	126
		Hip – Lateral Air-gap Technique	128

Radiographic Projections

Hip – Posterior Oblique (Lauenstein's)	130	Shoulder Girdle – Antero-posterior (15-degree) Erect	180
Hips (Both) – Lateral ('Frog's Legs' Position)	132	Shoulder Girdle – Antero-posterior (Glenohumeral Joint) – Modified (Grashey Projection)	182
Humerus – Antero-posterior	134	Shoulder – Supero-inferior (Axial)	184
Humerus – Lateral	136	Shoulder – Anterior Oblique ('Y' Projection)	186
Knee – Antero-posterior	138	Sinuses – Occipito-mental	188
Knee – Lateral (Basic)	140	Skull – Occipito-frontal	190
Knee – Horizontal Beam Lateral (Trauma)	142	Skull – Occipito-frontal 30-degree Cranial (Reverse Towne's)	192
Knee – Tunnel/Intercondylar Notch	144	Skull – Lateral Erect	194
Knee – 'Skyline' Patellar (Supero-inferior)	146	Skull – Fronto-occipital (Supine/Trolley)	196
Lumbar Spine – Antero-posterior	148	Skull – Fronto-occipital 30-degree Caudal (Towne's Projection) (Supine/Trolley)	198
Lumbar Spine – Lateral	150	Skull – Lateral (Supine/Trolley)	200
Lumbar Spine – Oblique	152	Skull 'Head' – CT	202
Lumbo-sacral Junction (L5–S1) – Lateral	154	Sternum – Lateral	204
Mandible – Postero-anterior	156	Thoracic Spine – Antero-posterior	206
Mandible – Lateral Oblique 30-degree Cranial (Supine)	158	Thoracic Spine – Lateral	208
Orbits – Occipito-mental (Modified)	160	Thumb – Antero-posterior	210
Orthopantomography (OPG/DPT)	162	Thumb – Lateral	212
Pelvis – Antero-posterior	164	Tibia and Fibula – Antero-posterior	214
Sacro-iliac Joints – Postero-anterior	166	Tibia and Fibula – Lateral	216
Sacrum – Antero-posterior	168	Toe – Hallux – Lateral	218
Sacrum – Lateral	170	Toes – Dorsi-plantar	220
Scaphoid Postero-anterior with Ulnar Deviation	172	Toes – Second to Fifth – Dorsi-plantar Oblique	222
Scaphoid – Anterior Oblique with Ulnar Deviation	174	Wrist – Postero-anterior	224
Scaphoid – Posterior Oblique	176	Wrist – Lateral	226
Scaphoid – Postero-anterior, Ulnar Deviation and 30-degree Cranial	178	Zygomatic Arches – Infero-superior	228

ABDOMEN – ANTERO-POSTERIOR SUPINE

Position of Patient and Image Receptor (Fig. 2.1a)

- The patient lies supine on the imaging table with the median sagittal plane at right angles and coincident with the midline of the table.
- The pelvis is adjusted so that the anterior superior iliac spines are equidistant from the table top.
- If a computed radiography (CR) cassette is selected, it is placed longitudinally in the cassette tray (if patient habitus allows) and positioned so that the region below the symphysis pubis is included on the lower margin of the image.
- The centre of the image receptor will be approximately at the level of a point located 1 cm below the line joining the iliac crests. This will ensure that the region inferior to the symphysis pubis is included on the image.

Direction and Location of X-ray Beam

- The collimated vertical beam is directed to the centre of the image receptor to include the lateral margins of the abdomen.
- Using a short exposure time, the exposure is made on arrested respiration. Ideally, respiration should be arrested on full expiration to allow the abdominal contents to lie in their natural position; however, depending on the patient's height, respiration may need to be arrested on full inspiration to include the whole abdomen.

Essential Image Characteristics (Fig. 2.1b)

- The bowel pattern should be demonstrated with minimal lack of sharpness.

Additional Considerations

- In the case of a large abdomen or apron, an immobilisation/compression band may be applied to reduce the dose to the patient as well as the negative effects of scatter on image quality.
- If required, the examination may be undertaken taking two images in landscape mode to ensure coverage.
- When using an automatic exposure control device, the central and right chambers may be selected simultaneously to avoid the risk of underexposure due to the beam passing through regions containing mainly bowel gas.

Expected DRL: DAP 2.5 Gy·cm², ESD 4 mGy*

* DAP, dose–area product; DRL, diagnostic reference levels; ESD, entrance skin dose.

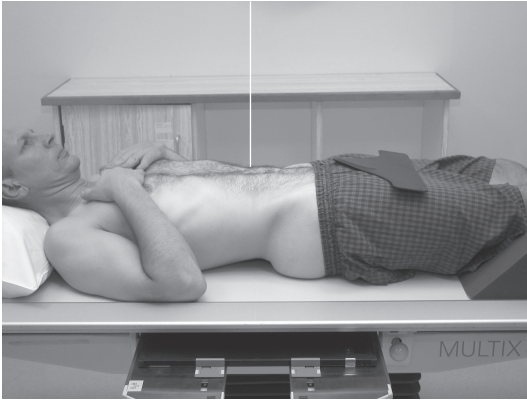

Fig. 2.1a Positioning for antero-posterior supine projection of the abdomen.

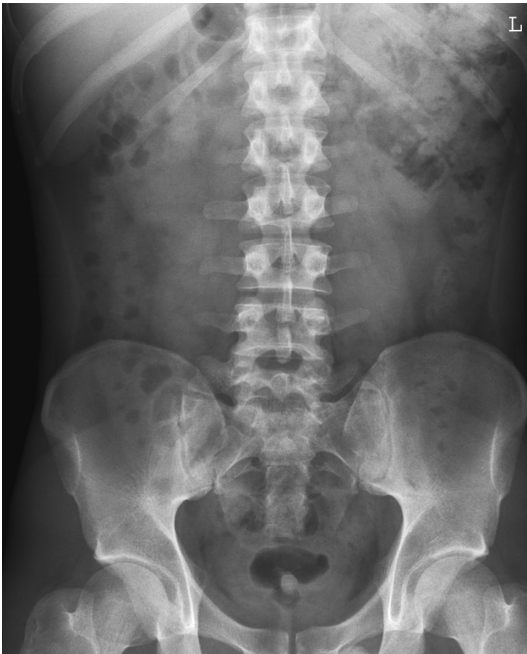

Fig. 2.1b Example of an antero-posterior supine radiograph of the abdomen.

ABDOMEN ANTERO-POSTERIOR – LEFT LATERAL DECUBITUS

This projection is used if the patient cannot be positioned erect for a chest X-ray and is required to confirm the presence of sub-diaphragmatic air. It should only be undertaken as a specific request when other modalities such as ultrasound and CT cannot be used. It may also be used for confirming a bowel obstruction.

With the patient lying on the left side, free gas will rise to be located between the lateral margin of the liver and the right lateral abdominal wall. To allow time for the gas to collect, the patient should remain lying on the left side for a short period (e.g. 10 minutes) before the exposure is made.

Position of Patient and Image Receptor (Fig. 2.2a)

- The patient lies on their left side on a trolley or bed, with their elbows and arms flexed so that the hands can rest near the patient's head.
- The patient is positioned with the posterior aspect of the trunk against a vertical Bucky direct digital radiography (DDR) system with the upper border of the image receptor high enough to project above the right lateral abdominal and thoracic walls. Alternatively, a 35 cm × 43 cm CR grid cassette is supported vertically against the patient's back.
- The patient's position is adjusted to bring the median sagittal plane at right angles to the image receptor.

Direction and Location of X-ray Beam

- The collimated horizontal central beam is directed to the anterior aspect of the patient and centred on the centre of the image receptor.

Essential Image Characteristics (Fig. 2.2b)

- The lateral abdominal wall and costo-phrenic angle of the right lung must be included, with the patient resting on their left side for a minimum of 10 minutes prior to exposure, for the reasons given above.

Expected DRL: DAP 2.5 Gy·cm², ESD 4 mGy

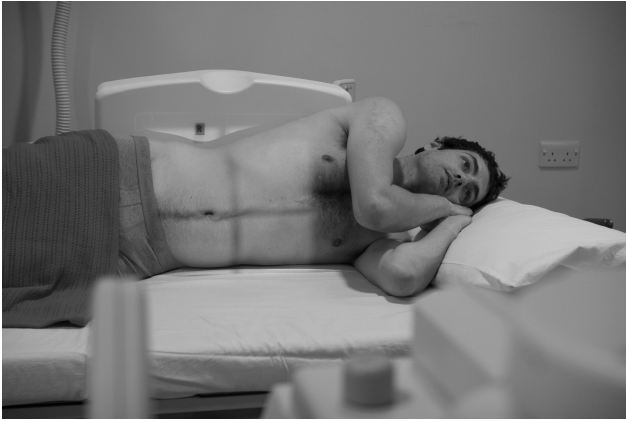

Fig. 2.2a Positioning for antero-posterior abdomen projection – left lateral decubitus.

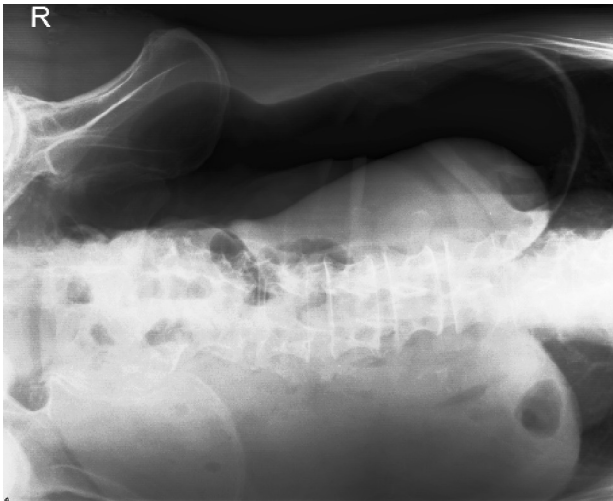


Fig. 2.2b Example of an antero-posterior abdomen radiograph – left lateral decubitus demonstrating free air (perforation).

ACROMIO-CLAVICULAR JOINT

Position of Patient and Image Receptor (Fig. 2.3a)

- The patient stands facing the X-ray tube, with the arms relaxed at the sides. The shoulder being examined is placed in contact with the receptor, and the patient is then rotated approximately 15 degrees towards the side being examined. This positions the acromio-clavicular joint space at right angles to the image receptor, with the acromion process central to the field.
- The image receptor is positioned so that the acromion process is in the centre of the image receptor.

Direction and Location of X-ray Beam

- The collimated horizontal beam is centred on the palpable lateral end of the clavicle at the acromio-clavicular joint.
- To avoid superimposition of the joint on the spine of the scapula, the central ray can be angled 15–25 degrees cranially before centring on the joint.

Essential Image Characteristics (Fig. 2.3b)

- The image should demonstrate the acromio-clavicular joint and the clavicle projected above the acromion process.
- The exposure should demonstrate soft tissue around the articulation.

Additional Considerations

- An antero-posterior projection of the joint in question is all that is normally required. In certain circumstances, subluxation of the joint may be confirmed with the patient holding a heavy weight.
- The inferior surfaces of the acromion and clavicle should usually be in a straight line.



Fig 2.3a Positioning for acromio-clavicular joint projection.

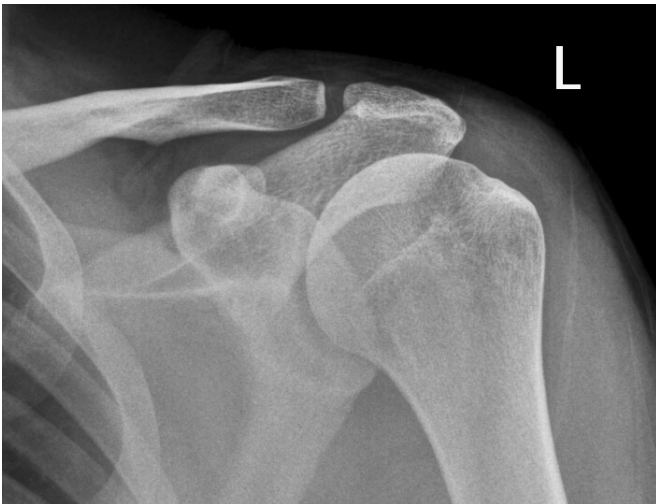

Fig. 2.3b Example of an antero-posterior radiograph of a normal acromio-clavicular joint.

ANKLE – ANTERO-POSTERIOR/ MORTISE JOINT

Position of Patient and Image Receptor (Fig. 2.4a)

- The patient is either supine or seated on the X-ray table, with both legs extended.
- A pad may be placed under the knee for comfort.
- The affected ankle is supported in dorsiflexion by a firm 90-degree pad placed against the plantar aspect of the foot. The limb is rotated medially (approximately 20 degrees) until the medial and lateral malleoli are equidistant from the receptor.
- If the patient is unable to sufficiently dorsiflex the foot, raising the heel on a 15-degree wedge or using 5–10 degrees of cranial tube angulation can correct this problem.
- The mid-tibia may be immobilised using a sandbag.

Direction and Location of X-ray Beam

- The collimated vertical beam is centred midway between the malleoli, with the central ray at 90 degrees to an imaginary line joining the malleoli.

Essential Image Characteristics (Fig. 2.4b)

- The lower third of the tibia and fibula should be included.
- With trauma, it is useful to include the base of fifth metatarsal.
- A clear joint space between the tibia, fibula and talus should be demonstrated (commonly called the mortise view).

Additional Considerations

- Insufficient dorsiflexion = calcaneum superimposed on lateral malleolus.

Expected DRL: ESD 0.11 mGy

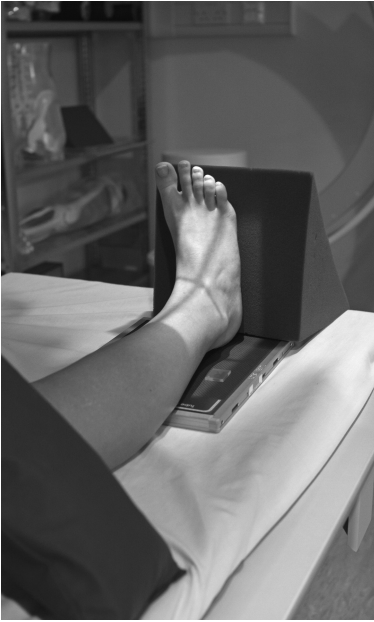

Fig. 2.4a Positioning for antero-posterior ankle (mortise) projection.

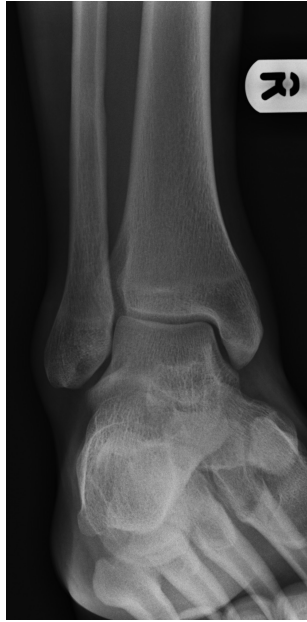

Fig. 2.4b Example of an antero-posterior ankle (mortise) radiograph.

ANKLE – LATERAL

Position of Patient and Image Receptor (Fig. 2.5a)

- With the ankle dorsiflexed, the patient turns onto the affected side until the malleoli are superimposed vertically and the tibia is parallel to the imaging receptor.
- A 15-degree pad is placed under the lateral border of the forefoot, and a pad is placed under the knee for support.

Direction and Location of X-ray Beam

- The collimated vertical beam is centred over the medial malleolus, with the central ray at right angles to the axis of the tibia.

Essential Image Characteristics (Fig. 2.5b)

- The lower third of the tibia and fibula, base of the fifth metatarsal and calcaneum should be included.
- The medial and lateral borders of the trochlear articular surface of the talus should be superimposed on the image.

Additional Considerations

- Over- and under-rotation lead to non-superimposition of the talar and trochlear surfaces.
- Over-rotation = fibula projected posterior to tibia.
- Under-rotation = shaft of fibula superimposed on tibia.
- Inversion injury of the ankle is common and may result in fracture of the lateral malleolus or base of the fifth metatarsal. Investigation of the injury should therefore cover both areas.

Expected DRL: ESD 0.12 mGy

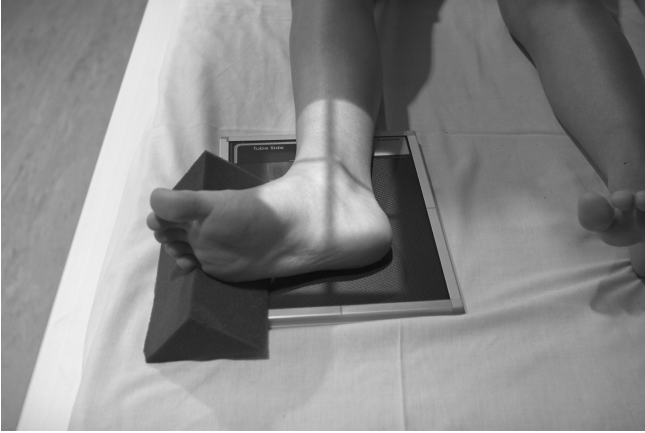


Fig. 2.5a Positioning for lateral ankle projection.

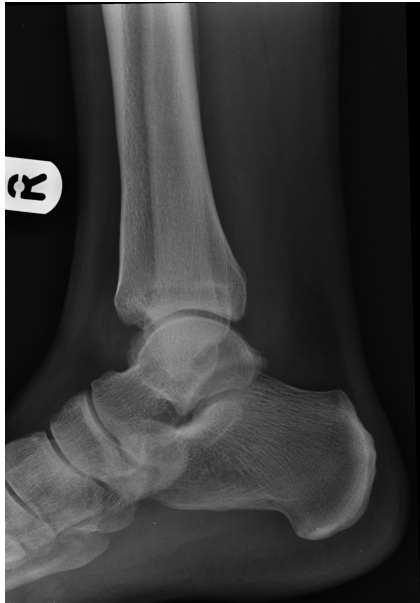

Fig. 2.5b Example of a lateral ankle radiograph.

CALCANEUM – AXIAL

Position of Patient and Image Receptor (Fig. 2.6a)

- The patient sits or lies supine on the X-ray table with both limbs extended.
- The affected leg is rotated medially until both malleoli are equidistant from the receptor.
- The ankle is dorsiflexed.
- The position is maintained using a bandage strapped around the forefoot and held in position by the patient.
- The receptor is positioned with its lower edge just distal to the plantar aspect of the heel.

Direction and Location of X-ray Beam

- The X-ray tube is directed cranially at an angle of 40 degrees to the plantar aspect of the heel.
- The collimated beam is centred on the plantar aspect of the heel at the level of the tubercle of the fifth metatarsal.

Essential Image Characteristics (Fig. 2.6b)

- The subtalar joint and sustentaculum tali should be visible on the axial projection.
- The inferior aspect of the calcaneum and soft tissue borders should also be demonstrated.

Expected DRL: ESD 0.2 mGy

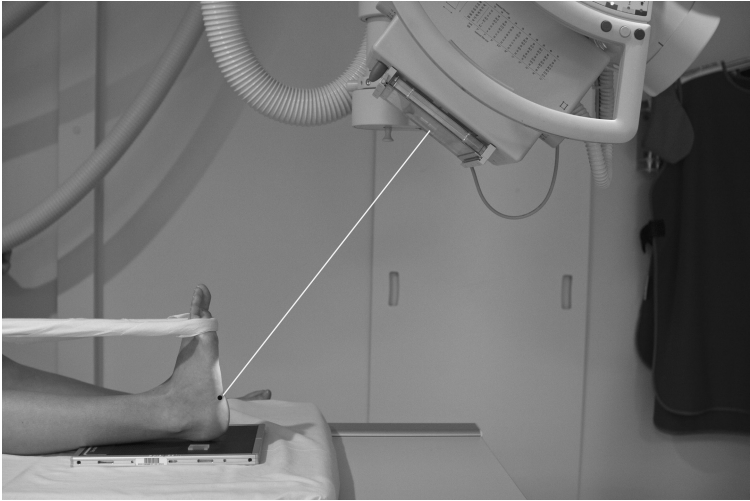

Fig. 2.6a Positioning for axial calcaneum projection.

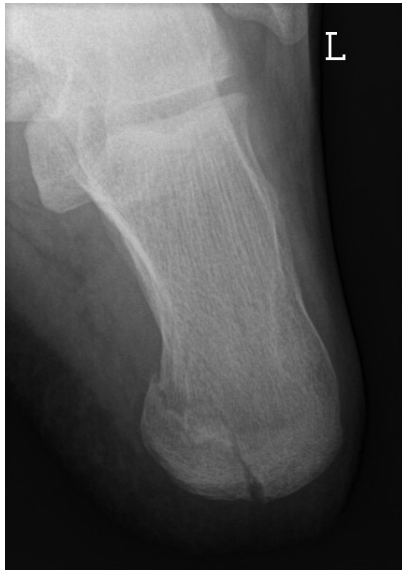

Fig. 2.6b Example of an axial calcaneum radiograph showing a fracture.

CERVICAL SPINE – ANTERO-POSTERIOR C3–C7

Position of Patient and Image Receptor (Fig. 2.7a)

- The patient lies supine on the table/trolley or, if erect positioning is preferred, sits or stands with the posterior aspect of the head and shoulders against the vertical Bucky detector system.
- The median sagittal plane is adjusted to be at right angles to the image receptor and to coincide with the midline of the table or Bucky.
- The neck is extended (if the patient's condition will allow) so that the lower part of the jaw is cleared from the upper cervical vertebra.
- The image receptor is positioned in the Bucky to coincide with the central ray. The Bucky mechanism will require some cranial displacement if the tube is angled.

Direction and Location of X-ray Beam

- The collimated beam is directed with a 5–15-degree cranial angulation, such that the inferior border of the symphysis menti is superimposed over the occipital bone.
- The beam is centred in the midline towards a point just below the prominence of the thyroid cartilage through the fifth cervical vertebra.

Essential Image Characteristics (Fig. 2.7b)

- The image must demonstrate the third cervical vertebra down to the cervico-thoracic junction.
- Lateral collimation should include the soft tissue margins.
- The chin should be superimposed over the occipital bone.

Additional Considerations

- It is usual to use a grid but this may be omitted for smaller patients.

Expected DRL: DAP 0.15 Gy·cm²

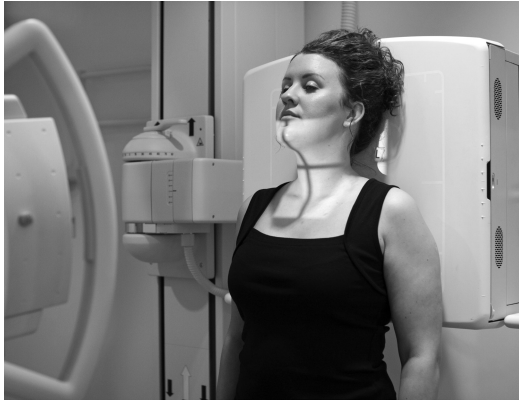

Fig. 2.7a Positioning for antero-posterior cervical spine projection – patient erect.

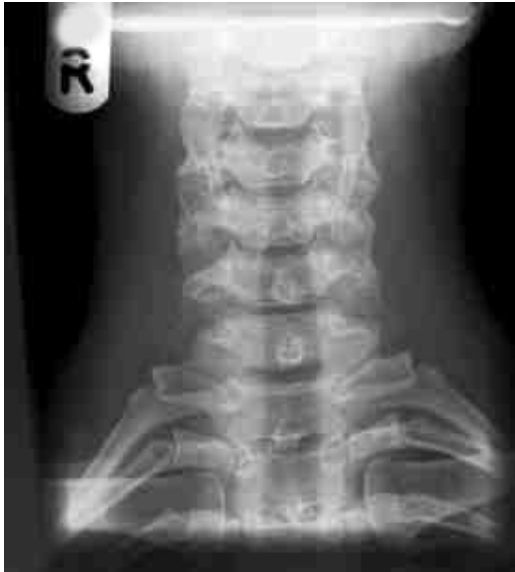

Fig. 2.7b Example of an antero-posterior cervical spine radiograph.

CERVICAL SPINE – ANTERO-POSTERIOR C1–C2 'OPEN MOUTH'

Position of Patient and Image Receptor (Fig. 2.8a)

- The patient lies supine on the Bucky table or, if erect positioning is preferred, sits or stands with the posterior aspect of the head and shoulders against the vertical Bucky detector system.
- The medial sagittal plane is adjusted to coincide with the midline of the image receptor, such that it lies at right angles to the image receptor.
- The neck is extended, if possible, such that a line joining the tip of the mastoid process and the inferior border of the upper incisors is at right angles to the receptor. This superimposes the upper incisors and the occipital bone, thus allowing clear visualisation of the area of interest.
- The receptor is centred on the level of the mastoid process.

Direction and Location of X-ray Beam

- The collimated beam is directed with the perpendicular central ray along the midline to the centre of the open mouth.
- If the patient is unable to flex the neck and attain the position described above, the beam must be angled, typically 5–10 degrees cranially or caudally, to superimpose the upper incisors on the occipital bone.
- The image receptor position will have to be altered slightly to allow the image to be centred after beam angulation.

Essential Image Characteristics (Fig. 2.8b)

- The inferior border of the upper central incisors should be superimposed over the occipital bone.
- The whole of the articulation between the atlas and the axis must be clearly demonstrated.
- Ideally, the whole of the dens, the lateral masses of the atlas and as much as possible of the axis should be included within the image.

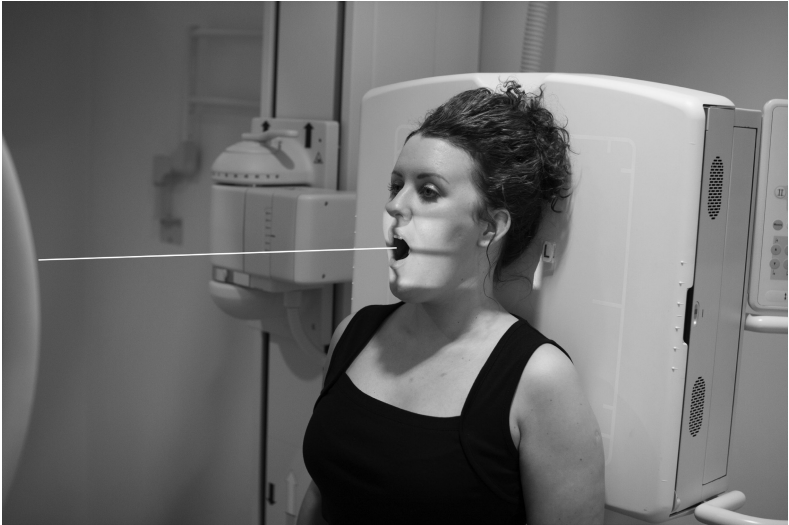

Fig. 2.8a Positioning for antero-posterior C1–C2 cervical spine projection – patient erect.

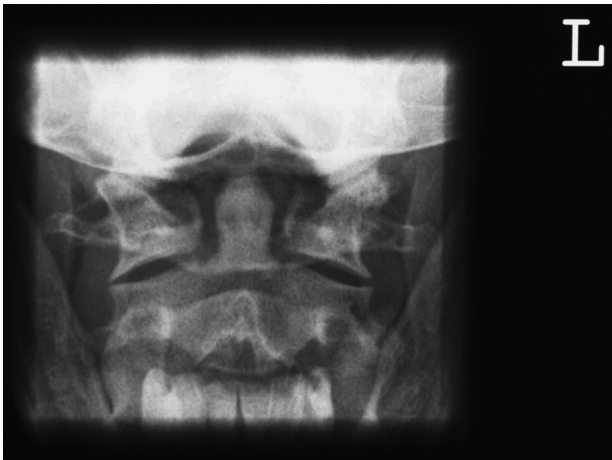


Fig. 2.8b Example of an antero-posterior C1–C2 cervical spine radiograph.

CERVICAL SPINE – LATERAL ERECT

Position of Patient and Image Receptor (Fig. 2.9a)

- The patient stands or sits with either shoulder against the CR cassette or vertical digital detector system (a grid may be employed depending on department protocols and patient size).
- The median sagittal plane should be adjusted such that it is parallel to the image receptor.
- The head should be flexed or extended such that the angle of the mandible is not superimposed over the upper anterior cervical vertebra or the occipital bone does not obscure the posterior arch of the atlas.
- To aid immobilisation, the patient should stand with the feet slightly apart and the shoulder resting against the detector stand.
- In order to demonstrate the lower cervical vertebra, the shoulders should be depressed. This can be achieved by asking the patient to relax the shoulders downwards. The process can be aided by asking the patient to hold a weight in each hand (if they are capable) and making the exposure on arrested expiration.

Direction and Location of X-ray Beam

- The collimated horizontal beam is centred over a point vertically below the mastoid process at the level of the prominence of the thyroid cartilage.

Essential Image Characteristics (Fig. 2.9b)

- The whole of the cervical spine should be included, from the atlanto-occipital joints to the top of the first thoracic vertebra.
- The mandible or occipital bone must not obscure any part of the upper vertebra.
- The angles of the mandible and lateral portions of the floor of the posterior cranial fossa should be superimposed.
- The soft tissues of the neck should be included.
- The contrast should produce densities sufficient to demonstrate soft tissue and bony detail.

Expected DRL: DAP 0.15 Gy·cm²

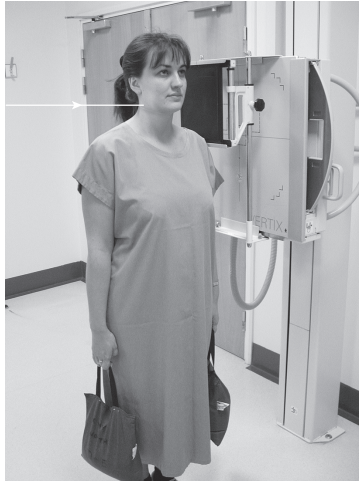

Fig. 2.9a Positioning for lateral erect cervical spine projection.

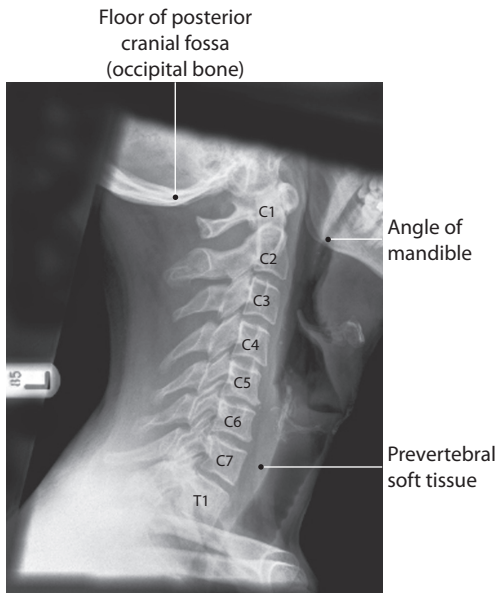


Fig. 2.9b Example of a lateral cervical spine radiograph.

CERVICAL SPINE – LATERAL 'SWIMMERS'

Position of Patient and Image Receptor (Fig. 2.10a)

- This projection is usually carried out with the patient supine on a trauma trolley. The trolley is positioned adjacent to the vertical Bucky digital detector system, with the patient's median sagittal plane parallel to the receptor.
- The arm nearest the receptor is folded over the head, with the humerus as close to the trolley top as the patient can manage. The arm and shoulder nearest the X-ray tube are depressed as far as possible.
- The shoulders are now separated vertically.
- The detector system should be raised or lowered, such that the line of the vertebrae should coincide with the middle of the receptor.
- This projection can also be undertaken with the patient erect, either standing or sitting, or supine.

Direction and Location of X-ray Beam

- The collimated horizontal central ray is directed to the midline of the image receptor at a level just above the shoulder that is remote from the receptor.

Essential Image Characteristics (Fig. 2.10b)

- It is imperative to ensure that the C7/T1 junction has been included on the image. It is therefore useful to include an anatomical landmark, e.g. an atypical second cervical vertebra, within the image. This makes it possible to count down the vertebrae and ensure that the junction has been imaged.

Additional Considerations

- Failure to ensure that the raised arm is as flat as possible against the trolley may result in the head of the humerus obscuring the region of interest.

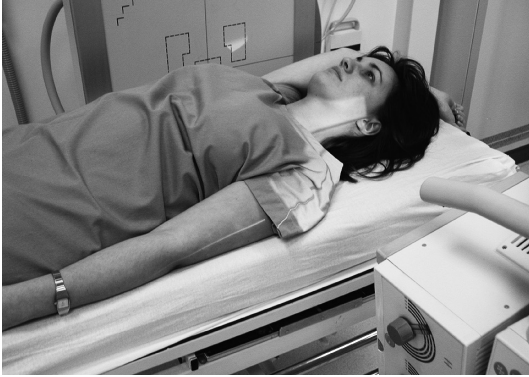

Fig. 2.10a Positioning for lateral ‘swimmers’ cervical spine projection.

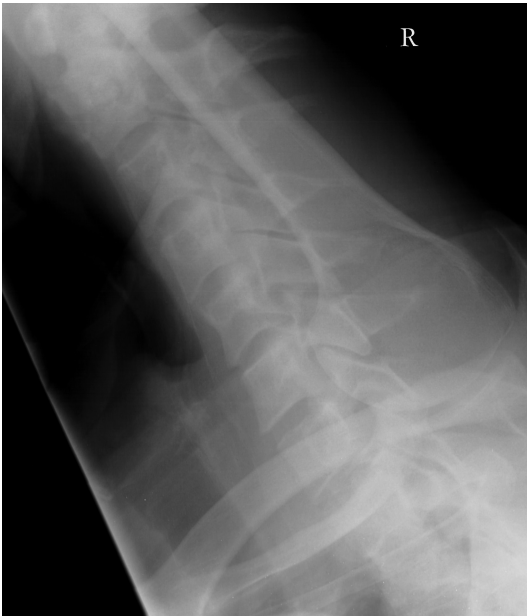

Fig. 2.10b Example of a lateral ‘swimmers’ cervical spine radiograph.

CERVICAL SPINE – LATERAL SUPINE

Position of Patient and Image Receptor (Fig. 2.11a)

- This projection is normally undertaken on trauma patients who arrive in a supine position on a trolley or bed.
- It is vitally important for the patient to depress the shoulders as much as possible (assuming no other injuries contraindicate this).
- A cassette should be supported vertically or placed in the erect cassette holder, with the top of the cassette at the same level as the top of the ear. Alternatively, a vertical DDR system is employed that is adjusted along with the position of the trolley to ensure that the cervical spine corresponds to the central field of the detector.
- To maximally depress the shoulders, one or two suitably qualified individuals can apply caudal traction to the arms.

Direction and Location of X-ray Beam

- The collimated horizontal beam is centred over a point horizontally distal to the mastoid process at the level of the prominence of the thyroid cartilage.

Essential Image Characteristics (Fig. 2.11b)

- See 'Cervical spine – lateral erect' (page 64).

Additional Considerations

- If the image has failed to demonstrate C7 or T1 and the patient's shoulders are already fully depressed, applying traction will normally show half to one extra vertebra inferiorly. Should the cervical thoracic junction still remain undemonstrated, swimmers, lateral and oblique projections or CT should be considered.
- Refer to departmental local rules for staff working within a controlled area.

Expected DRL: DAP 0.15 Gy·cm²

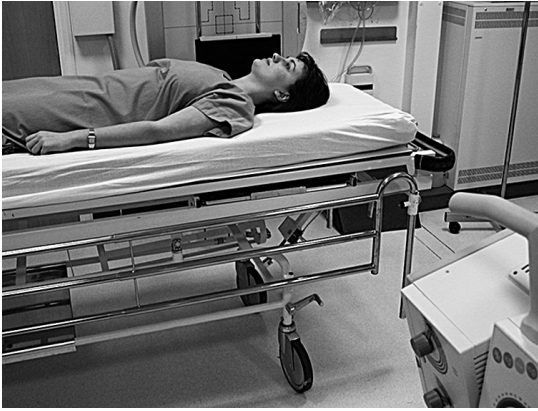

Fig. 2.11a Positioning for lateral supine cervical spine projection.

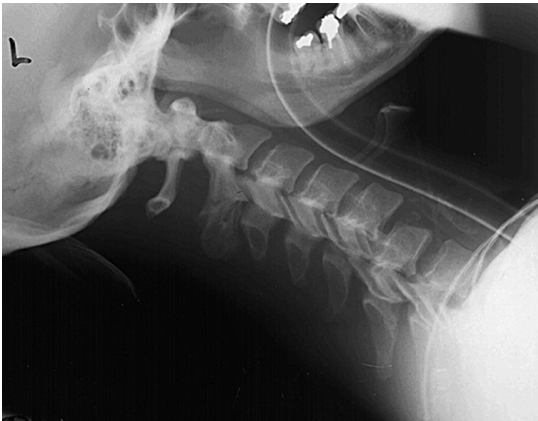

Fig. 2.11b Example of a lateral cervical spine cervical spine radiograph demonstrating a fracture dislocation of C5/C6.

CERVICAL SPINE – POSTERIOR OBLIQUE

Position of Patient and Image Receptor (Fig. 2.12a)

- The patient stands or sits with the posterior aspect of their head and shoulders against the image receptor. This can be a cassette or vertical DDR system. A grid may or may not be used depending on patient size.
- The median sagittal plane of the trunk is rotated through 45 degrees for the right and left sides in turn.
- The head can be rotated so that the median sagittal plane is parallel to the image receptor, thus avoiding superimposition of the mandible on the vertebra.
- The image receptor is centred on the prominence of the thyroid cartilage.

Direction and Location of X-ray Beam

- The collimated beam is angled 15 degrees cranially from the horizontal, and the central ray is directed to the middle of the neck on the side nearest the tube.

Essential Image Characteristics (Fig. 2.12b)

- The intervertebral foramina should be demonstrated clearly.
- C1–T1 should be included within the image.
- The mandible and the occipital bone should be clear of the vertebrae.

Additional Considerations

- In trauma cases, the projection may be undertaken supine with the beam angled 30–45 degrees to the median sagittal plane. The image receptor should be displaced to one side to account for the beam angulation, and no grid should be used or else a grid ‘cut-off’ artefact will result.



Fig. 2.12a Positioning for oblique cervical spine projection.

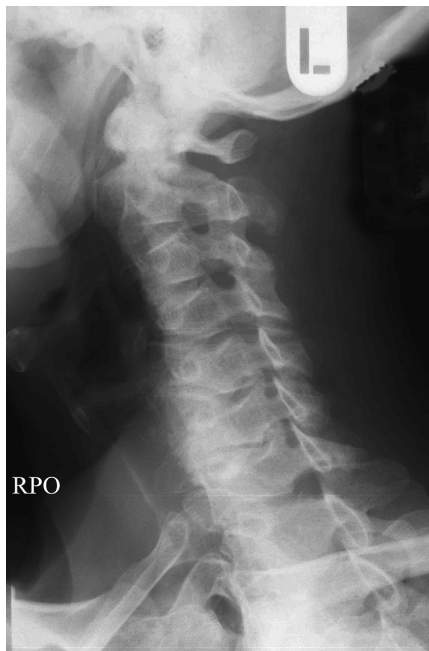

Fig. 2.12b Example of an oblique cervical spine radiograph.

CERVICAL SPINE – FLEXION AND EXTENSION

Position of Patient and Image Receptor (Figs 2.13a, b)

- The patient is positioned as for the lateral basic or lateral supine projection; however, erect positioning is more convenient. The patient is asked to flex the neck and tuck the chin in towards the chest as far as possible.
- For the second projection, the patient is asked to extend the neck by raising the chin as far as possible.
- Immobilisation can be facilitated by asking the patient to hold onto a solid object, such as the back of a chair.
- The image receptor is centred on the mid-cervical region. If a CR cassette is being used, this may have to be placed transversely for the lateral projection with the neck in flexion, depending on the degree of movement and the cassette size used.
- If the patient is being imaged supine, the neck can be flexed by placing pads under it. Neck extension can be achieved by placing pillows under the patient's shoulders.

Direction and Location of X-ray Beam

- The collimated horizontal beam is centred over the mid-cervical region (C4).

Essential Image Characteristics (Fig. 2.13c)

- The final image should include the entire cervical vertebra, including the atlanto-occipital joints, the spinous processes and the soft tissues of the neck.

Additional Considerations

- If undertaking these examinations on patients with suspected trauma or an unstable spine, refer to local protocols for the need for medical supervision when moving the spine or removing immobilisation collars.

Expected DRL: DAP 0.15 Gy·cm²



Fig. 2.13a Flexion.

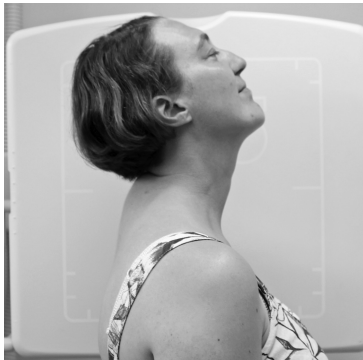

Fig. 2.13b Extension.

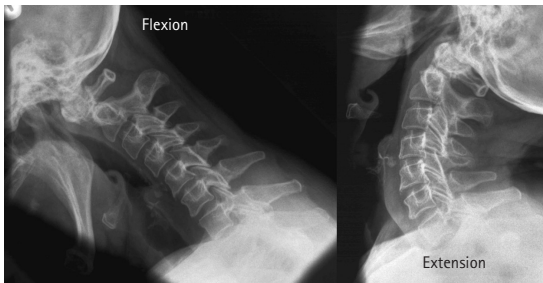


Fig. 2.13c Examples of cervical spine flexion and extension radiographs.

CHEST – POSTERO-ANTERIOR

Position of Patient and Image Receptor (Fig. 2.14a)

- A vertical Bucky DDR system is employed, or alternatively a 35 cm × 43 cm or 35 cm × 35 cm CR cassette is selected depending on the patient's size. Orientation of a larger cassette will depend on the width of the thorax.
- Careful patient preparation is essential, with all radio-opaque objects removed before the examination.
- The patient is positioned facing the receptor, with the chin extended and centred on the middle of the top of the receptor.
- The feet are placed slightly apart so that the patient is able to remain steady.
- The median sagittal plane is adjusted at right angles to the middle of the receptor; the shoulders are rotated forwards and pressed downwards in contact with the receptor or vertical stand.
- This is achieved by placing the dorsal aspect of the hands behind and below the hips, with the elbows brought forward or by allowing the arms to encircle the vertical Bucky device.

Direction and Location of X-ray Beam

- The collimated horizontal beam is directed at right angles to the receptor and centred on the level of the eighth thoracic vertebra (i.e. spinous process of T7), which coincides with the midpoint of the lung, and found using the inferior angle of the scapula before the shoulders are pushed forward.
- Exposure is made in full normal arrested inspiration.
- An focus-to-receptor distance (FRD) of 180 cm is used to minimise the magnification.

Essential Image Characteristics (Fig. 2.14b)

- Full lung fields are needed, with the scapulae projected laterally away from the lung fields, and the clavicles symmetrical and equidistant from the spinous processes.

- Sufficient inspiration allows visualisation of either six ribs anteriorly or 10 ribs posteriorly.
- The costo-phrenic angles, diaphragm, mediastinum, lung markings and heart should be defined sharply.

Additional Considerations

- An expiration radiograph may be obtained to demonstrate a small apical pneumothorax.

Expected DRL: DAP $0.1 \text{ Gy}\cdot\text{cm}^2$, ESD 0.15 mGy

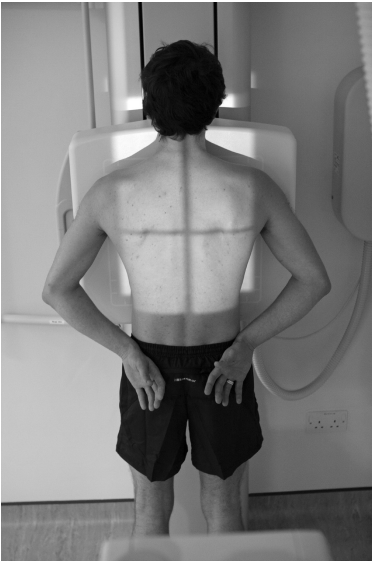

Fig. 2.14a Positioning for postero-anterior chest projection.

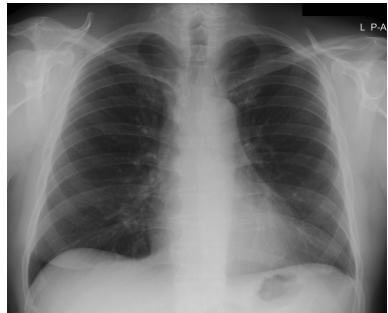

Fig. 2.14b Example of a postero-anterior chest radiograph.

CHEST – ANTERO-POSTERIOR (ERECT)

This projection is often used as an alternative when the postero-anterior projection cannot be performed due to the patient's condition. The patient is often supported sitting erect on a chair.

Position of Patient and Image Receptor (Fig. 2.15a)

- The patient sits with their back against the image receptor, with the upper edge of the image receptor above the lung apices.
- The median sagittal plane is adjusted to lie at right angles to the middle of the image receptor.
- Depending on the patient's condition, the arms are extended forwards into the anatomical position and internally rotated to minimise the superimposition of the scapulae on the lung fields.

Direction and Location of X-ray Beam

- The collimated horizontal beam is angled caudally until it is at right angles to the sternum and centred midway between the sternal notch and the xiphisternum.
- The degree of caudal angulation (5–10 degrees) for the non-kyphotic patient depends on the patient's anatomy. This will ensure maximum visualisation of the lung fields and that the clavicles do not obscure the lung apices.
- The exposure is taken on normal full inspiration.
- An FRD of at least 120 cm is essential to reduce unequal magnification of intrathoracic structures.

Essential Image Characteristics (Fig. 2.15b)

- The image should be of comparable quality to that described for the postero-anterior chest projection.

Additional Considerations

- The heart is moved further from the image receptor, thus increasing magnification and reducing the accuracy of assessment of heart size (as measured by the cardiothoracic ratio).

Expected DRL: DAP 0.15 Gy·cm², ESD 0.2 mGy

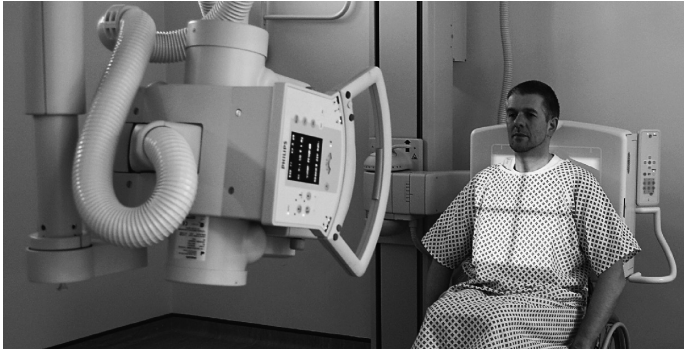

Fig. 2.15a Positioning for antero-posterior chest projection.

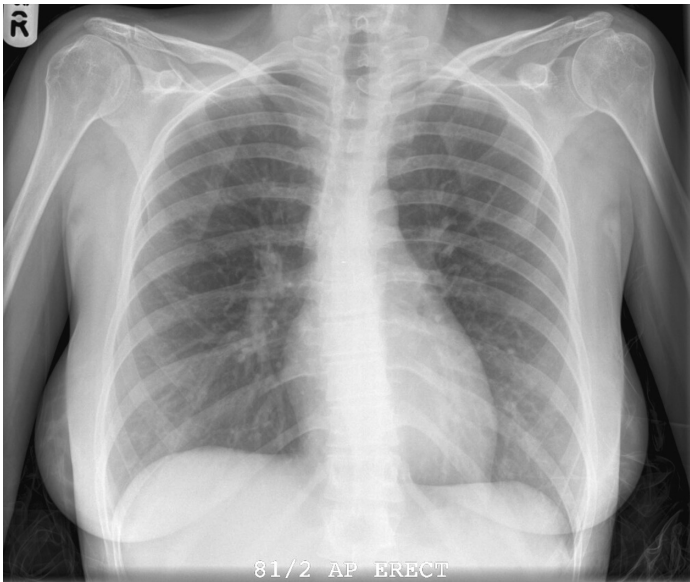

Fig. 2.15b Example of an antero-posterior chest radiograph.

CHEST – LATERAL

Position of Patient and Image Receptor (Fig. 2.16a)

- A vertical Bucky DDR system or a 35 cm × 43 cm CR cassette is employed.
- A moving or stationary grid may be used to prevent excess secondary radiation reaching the image. An FRD of 180 cm is used to minimise magnification, but in some circumstances this is reduced to 150 cm to maintain a short exposure time.
- The patient is turned to bring the side under investigation in contact with the image receptor.
- The median sagittal plane is adjusted parallel to the image receptor.
- The patient's arms are folded over the head or raised above the head to rest on a horizontal bar.
- The mid-axillary line is coincident with the middle of the image receptor, which is then adjusted to include the apices and the lower lobes to the level of the first lumbar vertebra.

Direction and Location of X-ray Beam

- The collimated horizontal beam is directed at right angles to the middle of the image receptor coincident with the mid-axillary line.
- Exposure is made in full normal arrested inspiration.

Essential Image Characteristics (Fig. 2.16b)

- The image should include the apices and costo-phrenic angles, and the lung margins anteriorly and posteriorly.
- Image contrast and density should be optimised to visualise the heart and lung tissue, with particular regard to any lesions if appropriate.

Additional Considerations

- This projection is useful to confirm the position and size of a lesion suspected from the initial projection, and to confirm the position of leads after a pacemaker insertion.
- However, it is not a routine examination due to the additional patient dose and the increasing use of CT to examine the thorax.

Expected DRL: ESD 0.5 mGy



Fig. 2.16a Positioning for lateral chest projection.

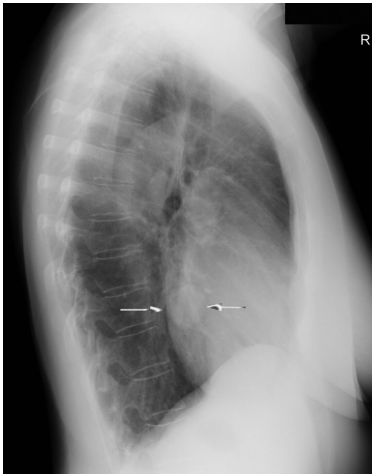


Fig. 2.16b Example of a lateral chest radiograph showing a tumour in the right lower lobe.

CHEST – SUPINE (ANTERO-POSTERIOR)

This projection is usually utilised only when the patient is unable to sit up on a bed or trolley.

Position of Patient and Image Receptor (Fig. 2.17a)

- With assistance, the detector is carefully positioned under the patient's chest with the upper edge of the detector above the lung apices (C7 prominence). A CR cassette, if used, is orientated to ensure that the lung fields are included on the image.
- The median sagittal plane is adjusted to lie at right angles to the middle of the detector, and the patient's pelvis is checked to ensure that it is not rotated.
- The patient's arms are rotated laterally and supported by the side of the trunk. The head is supported on a pillow, with the chin slightly raised.

Direction and Location of X-ray Beam

- This is as described for the sitting antero-posterior position except that the X-ray beam is vertical (see page 76).

Essential Image Characteristics (Fig. 2.17b)

- The image quality may be compromised due to the patient's condition and the drawbacks of this technique. However, the apices, lateral lung margins and bases should be visualised with adequate contrast, density and resolution, and no evidence of rotation.

Additional Considerations

- Maximum demonstration of the lung is lost due to the absence of the effect of gravity, present in the erect position, on the abdominal organs.
- A pleural effusion or a pneumothorax is not as well demonstrated compared with erect projections.
- An FRD of at least 120 cm is essential to reduce unequal magnification of the intrathoracic structures.

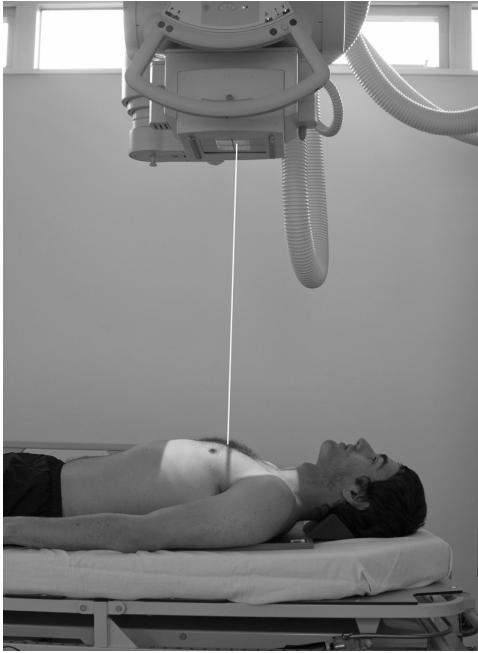

Fig. 2.17a Positioning for supine chest (antero-posterior) projection.

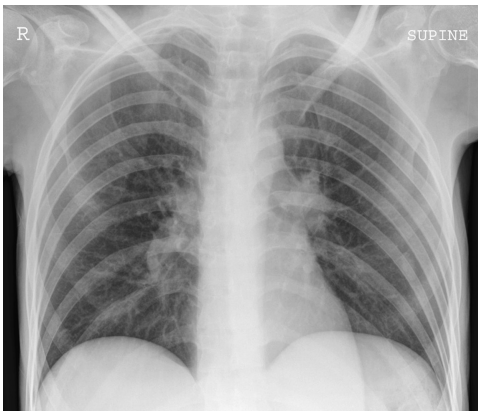


Fig. 2.17b Example of a supine chest (antero-posterior) radiograph.

CHEST – MOBILE/TROLLEY (ANTERO-POSTERIOR)

Ward radiography should only be performed when necessary, properly justifying the examination and checking previous images for consistency.

Position of Patient and Image Receptor (Fig. 2.18a)

- Where possible, the patient should be examined in an erect position. However, this may not be achievable due to the patient's condition.
- The image receptor is supported behind the patient's back, using pads, pillows or a padded receptor holder as required.
- It is very important to avoid or minimise any rotation or lordosis, which can make interpretation difficult.

Direction and Location of X-ray Beam

- These are as described for the sitting antero-posterior position (see page 76).
- Where possible, a high-powered mobile device is used to enable a 180 cm FRD for erect positioning of the patient.

Essential Image Characteristics (Fig. 2.18b)

- These are as described for the supine chest position (see page 80).

Additional Considerations

The radiographer needs to consider issues such as:

- careful identification of the patient;
- moving and handling issues;
- care when handling any patient devices such as drains or lines;
- infection control;
- radiation protection – use of lead rubber aprons; responsibility for the controlled area and protecting patients via careful selection of exposure factors, collimation and lead backstops where necessary;

- good communication with nursing staff;
- the good practice of annotating the image with information to assist with consistency of results. This may include the date, time, exposure, patient position and FRD.

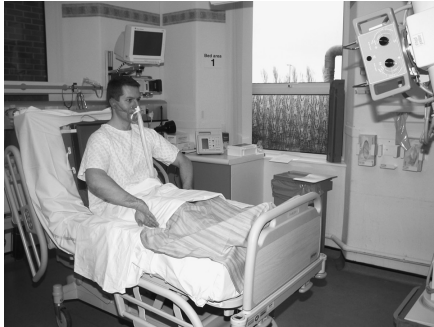

Fig. 2.18a Positioning for mobile antero-posterior chest projection.

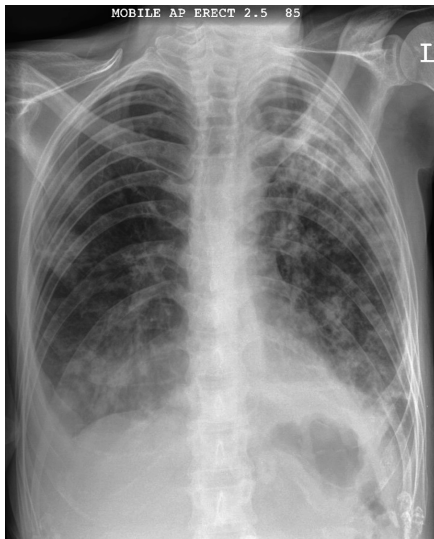

Fig. 2.18b Antero-posterior erect chest radiograph demonstrating bilateral consolidation with a right pleural effusion (in this case due to tuberculosis).

CLAVICLE – POSTERO-ANTERIOR

Position of Patient and Image Receptor (Fig. 2.19a)

- The patient sits or stands facing an erect image receptor.
- The patient's position is adjusted so that the middle of the clavicle is in the centre of the image receptor.
- The patient's head is turned away from the side being examined and the affected shoulder is rotated slightly forward to allow the affected clavicle to be brought into close contact with the image receptor or vertical Bucky DDR system.

Direction and Location of X-ray Beam

- The collimated horizontal beam is centred on the middle of the clavicle.

Essential Image Characteristics (Fig. 2.19b)

- The entire length of the clavicle should be included on the image.
- The lateral end of the clavicle will be demonstrated clear of the thoracic cage.
- There should be no foreshortening of the clavicle.
- The exposure should demonstrate both the medial and lateral ends of the clavicle.

Additional Considerations

- Although the clavicle is demonstrated on the antero-posterior projection, it is desirable to have the clavicle as close to the image receptor as possible to give optimum bony detail.
- The exposure is made on arrested respiration to eliminate patient movement.

Expected DRL: ESD 0.099 mGy*

* Based on a small sample.

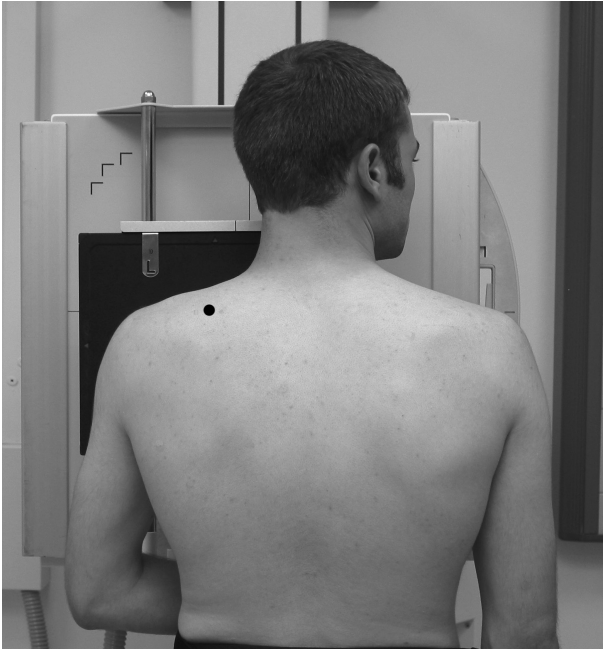

Fig. 2.19a Positioning for postero-anterior clavicle projection.

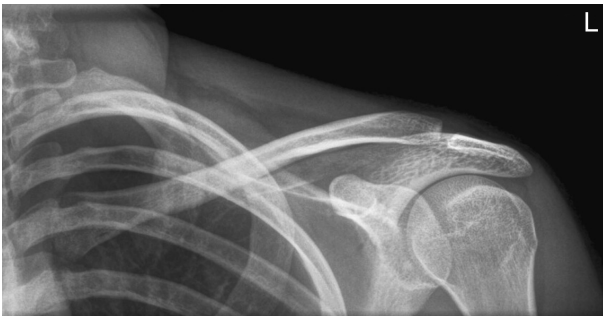

Fig. 2.19b Example of a postero-anterior clavicle radiograph.

CLAVICLE – INFERO-SUPERIOR

Position of Patient and Image Receptor (Fig. 2.20a)

- The patient sits facing the X-ray tube, resting against the image receptor. Some receptor supports allow forward angulation of the cassette of 15 degrees towards the shoulder. This reduces the distortion caused by the cranially projected central beam.
- The unaffected shoulder is raised slightly to bring the scapula in contact with the receptor.
- The patient's head is turned away from the affected side.
- The image receptor is displaced above the shoulder to allow the clavicle to be projected into the middle of the image.

Direction and Location of X-ray Beam

- The collimated horizontal beam is angled 30 degrees cranially and centred on the middle of the clavicle.
- The medial end of the clavicle can be shown in greater detail by adding a 15-degree lateral angulation to the beam.

Essential Image Characteristics (Fig. 2.20b)

- The image should demonstrate the entire length of the clavicle, including the sternoclavicular and acromio-clavicular joints.
- The entire length of the clavicle, with the exception of the medial end, should be projected clear of the thoracic cage.

Additional Considerations

- The 30 degrees needed to separate the clavicle from the underlying ribs can be achieved by a combination of patient positioning and beam angulation.
- It is not possible to undertake a lateral clavicle X-ray in addition to the antero-posterior one. The infero-superior projection thus allows the clavicle to be seen from a different aspect and will often detect abnormalities not seen on the antero-posterior view.

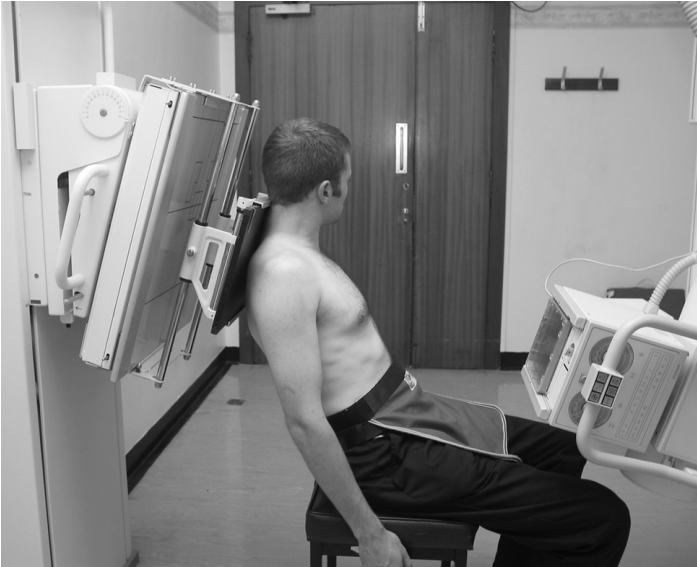

Fig. 2.20a Positioning for infero-superior clavicle projection.

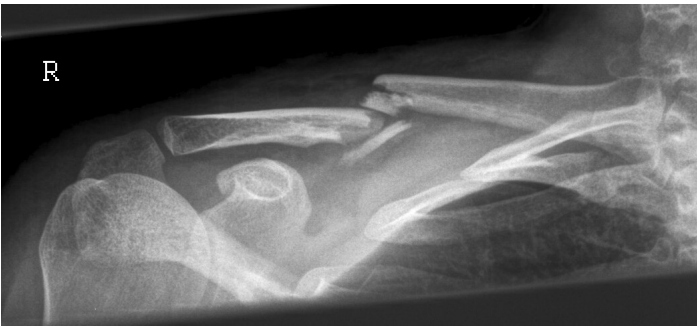

Fig. 2.20b Example of an infero-superior clavicle radiograph demonstrating a fracture.

ELBOW – ANTERO-POSTERIOR

Position of Patient and Image Receptor (Fig. 2.21a)

- The patient is seated alongside the table, with the affected side nearest to the table.
- The arm is then extended fully, such that the posterior aspect of the entire limb is in contact with the table top and the palm of the hand is facing upwards.
- The image receptor is positioned under the elbow joint to include the distal third of humerus and proximal third of the radius and ulna.
- The arm is adjusted such that the medial and lateral epicondyles are equidistant from the image receptor.
- The limb is immobilised using sandbags.

Direction and Location of X-ray Beam

- The collimated vertical beam is centred through the joint space 2.5 cm distal to the point midway between the medial and lateral epicondyles of the humerus

Essential Image Characteristics (Fig. 2.21b)

- To provide a satisfactory view of the joint space, the central ray must pass through the joint space at 90 degrees to the humerus.
- The image should demonstrate the distal third of humerus and the proximal third of the radius and ulna.

Notes

- When the patient is unable to extend the elbow to 90 degrees, a modified technique is used for the antero-posterior projection.
- If the limb cannot be moved, two projections at right angles to each other can be taken by keeping the limb in the same position and rotating the X-ray tube through 90 degrees.

Expected DRL: ESD 0.12 mGy

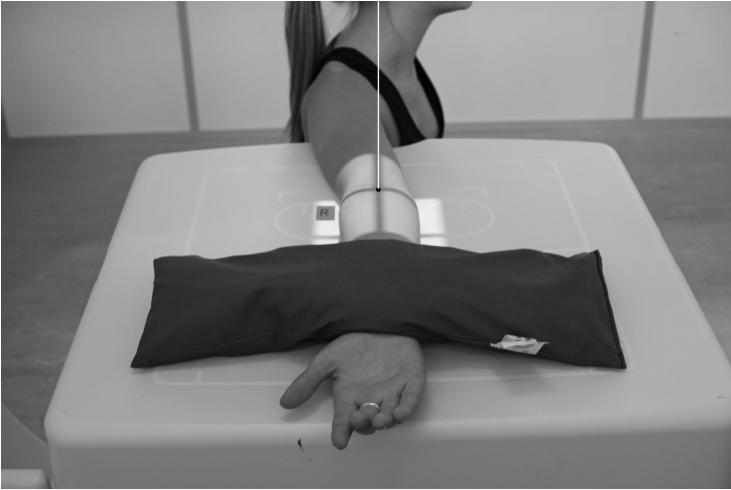

Fig. 2.21a Positioning for antero-posterior elbow projection.

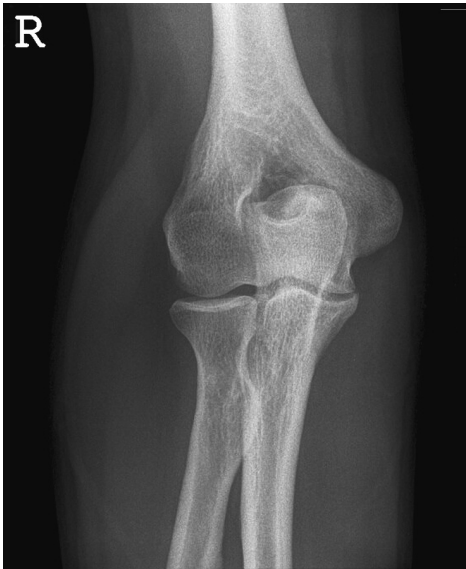

Fig. 2.21b Example of an antero-posterior elbow radiograph.

ELBOW – ALTERNATIVE ANTERO-POSTERIOR PROJECTIONS FOR TRAUMA

These projections may be useful if the patient is unable to extend the elbow fully. The positioning for the antero-posterior projection may thus be modified.

Position of Patient and Image Receptor (Figs 2.22a–c)

This is fundamentally the same as for an antero-posterior view of the elbow and the same for all projections; however, depending on the area of interest, either the upper arm or forearm is in contact with the image receptor:

- forearm in contact with the image receptor for suspected radial head and olecranon fractures;
- upper arm in contact with the image receptor for suspected supra-condylar fractures;
- axial projection when the patient cannot extend their arm to any extent.



Fig. 2.22a Forearm in contact with the receptor.

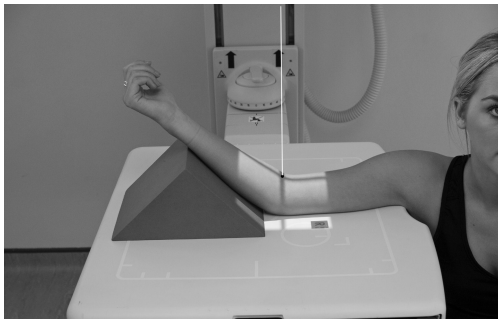


Fig. 2.22b Upper arm in contact with the receptor.




Fig. 2.22c Axial projection.

ELBOW – LATERAL

Position of Patient and Image Receptor (Fig. 2.23a)

- The patient is seated alongside the table, with the affected side nearest to the table.
- The elbow is flexed to 90 degrees, and the palm of the hand is rotated so that it is at a right angle to the table top.
- The shoulder is lowered so that it is at the same height as the elbow and wrist, such that the medial aspect of the entire arm is in contact with the table top.
- The image receptor is placed under the patient's elbow, with its centre to the elbow joint.
- The limb is immobilised using sandbags.

Direction and Location of X-ray Beam

- The vertical central ray is centred over the lateral epicondyle of the humerus.

Essential Image Characteristics (Fig. 2.23b)

- The central ray must pass through the joint space at 90 degrees to the humerus; i.e. the epicondyles should be superimposed.
- The image should demonstrate the distal third of humerus and the proximal third of the radius and ulna.

Notes

- Care should be taken when a supracondylar fracture of the humerus is suspected. In such cases, no attempt should be made to extend the elbow joint, and a modified technique must be employed.

Expected DRL: ESD 0.13 mGy

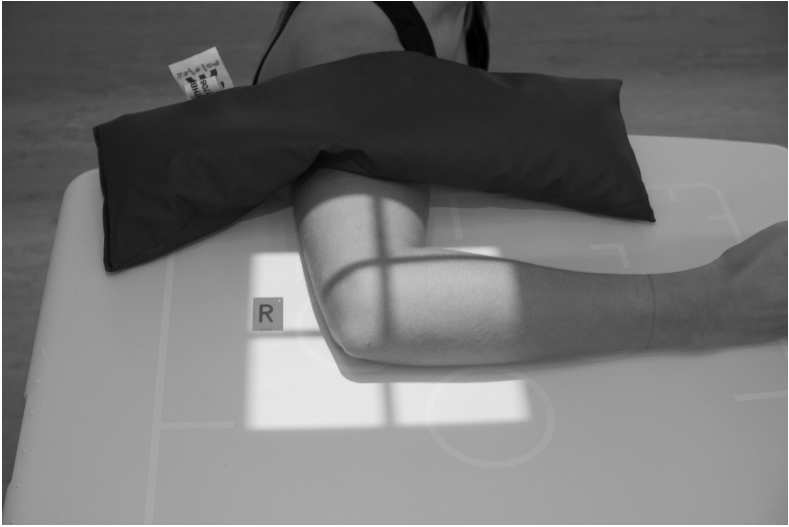


Fig. 2.23a Positioning for lateral elbow projection.

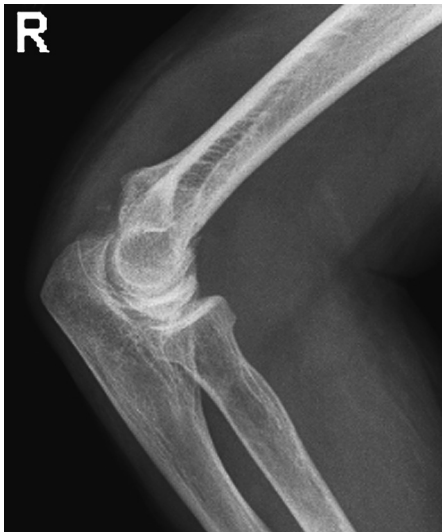

Fig. 2.23b Example of a lateral elbow radiograph.

FACIAL BONES – OCCIPITO-MENTAL

The occipito-mental projection shows the floor of the orbits in profile, the nasal region, the maxillae, the inferior parts of the frontal bone and the zygomatic bone. The zygomatic arches can be seen but they are visualised 'end on' and thus appear foreshortened. The occipito-mental projection is designed to project the petrous parts of the temporal bone below the inferior part of the maxilla.

Position of Patient and Image Receptor (Fig. 2.24a)

- The projection is best performed with the patient erect, seated facing the Bucky/receptor.
- The patient's nose and chin are placed in contact with the midline of the Bucky/receptor a-degree angle with the Bucky/receptor.
- The horizontal central line of the Bucky/receptor should be at the level of the lower orbital margins.
- Ensure the median sagittal plane is at right angles to the Bucky/receptor by checking that the outer canthus of the eyes and the external auditory meatuses are equidistant.

Direction and Location of X-ray beam

- The collimated horizontal beam is centred on the Bucky/receptor before positioning is undertaken.

Essential Image Characteristics (Fig. 2.24b)

- The petrous ridges should be demonstrated inferior to the floors of the maxillary sinuses. There should be no rotation.

Additional Considerations

- As this is an uncomfortable position to maintain, always check the baseline angle immediately before exposure.

Notes

- Common problems include superimposition of the petrous ridges over the inferior part of the maxillary sinuses. This demonstrates inadequate chin elevation and may be rectified by 5–10 degrees caudal angulation to the tube, maintaining the centring to the Bucky/receptor.



Fig. 2.24a Positioning for occipito-mental projection.

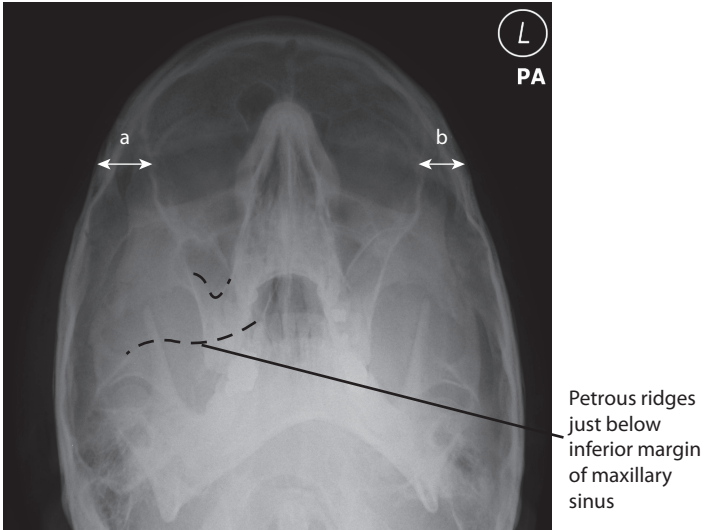


Fig. 2.24b Example of an occipito-mental radiograph with a right zygomatic arch fracture.

FACIAL BONES – OCCIPITO-MENTAL 30-DEGREE CAUDAL

This projection demonstrates the lower orbital margins and the orbital floors 'en face'.

Position of Patient and Image Receptor (Fig. 2.25a)

- The projection is best performed with the patient seated facing the vertical Bucky/receptor.
- The patient's nose and chin are placed in contact with the midline of the Bucky/receptor, and the head is then adjusted to bring the orbito-meatal base line at a 45-degree angle to the Bucky/receptor.
- The horizontal central line of the Bucky/receptor should be at the level of the symphysis menti.
- Ensure the median sagittal plane is at right angles to the Bucky/receptor by checking that the outer canthus of the eyes and the external auditory meatuses are equidistant.

Direction and Location of X-ray Beam

- The tube is angled 30 degrees caudally from the horizontal and centred along the midline such that the central ray exits at the level of the lower orbital margins.
- To ensure the collimated beam is properly centered, the crosslines on the Bucky/cassette holder should coincide approximately with the upper aspect of the symphysis menti region (this will vary with anatomical differences between patients).

Essential Image Characteristics (Fig. 2.25b)

- The orbital floors will be clearly visible through the maxillary sinuses, and the lower orbital margin should be clearly demonstrated. There should be no rotation.

Notes

- Common errors include failure to demonstrate the whole of the orbital floor due to under-angulation and failure to maintain the orbito-meatal baseline at 45 degrees. This may be compensated by increasing the caudal tube angle.




Fig. 2.25a Positioning for occipito-mental 30-degree caudal projection.

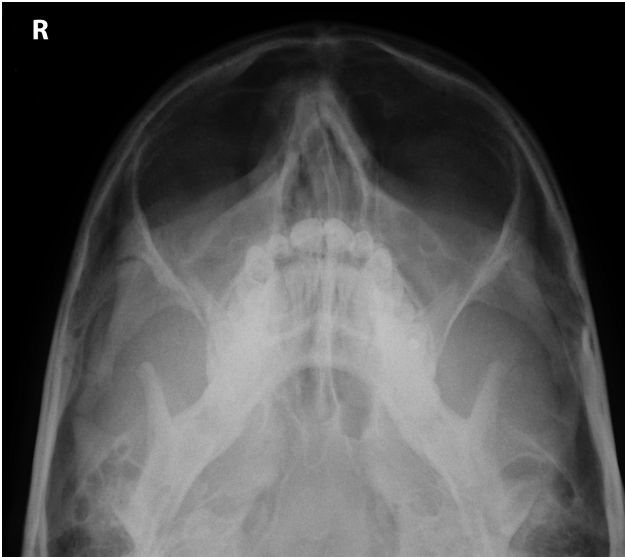

Fig. 2.25b Example of an occipito-mental 30-degree caudal radiograph.

FEMUR – ANTERO-POSTERIOR

Position of Patient and Image Receptor (Fig. 2.26a)

- The patient lies supine on the X-ray table, with both legs extended and the affected limb positioned on the centre line of the table.
- The affected limb is rotated to centralise the patella over the femur.
- Sandbags are placed below the knee to help maintain the position.
- The image receptor/Bucky mechanism is located directly under the posterior aspect of the thigh to include both the hip and the knee joints.
- Alternatively, a CR cassette or mobile DDR detector is positioned directly under the limb against the posterior aspect of the thigh, to include the knee and hip joints.

Direction and Location of X-ray Beam

- The collimated vertical beam is centred on the mid-shaft of the femur, with the central ray at 90 degrees to an imaginary line joining both femoral condyles.

Essential Image Characteristics (Figs 2.26b, c)

- Where possible, the whole length of the femur should be visualised, including the hip and knee joints.
- The patella should be centralised to indicate that rotation has been minimised.

Additional Considerations

- In suspected fractures, the limb must not be rotated.
- The knee and hip joints should be included on the image. This may be difficult to achieve, and an additional projection of the knee or hip joint may be required if coverage is not initially obtained; however, this will depend on the clinical information required.
- If the distal femur is the focus of attention, and the effects of scatter are not of pressing concern, the image receptor can be placed

directly under the femur. Radiographer assessment of patient size and thus resultant scatter will determine whether a direct exposure or the use of a Bucky tray/grid is appropriate.

Expected DRL: ESD 1.42 mGy

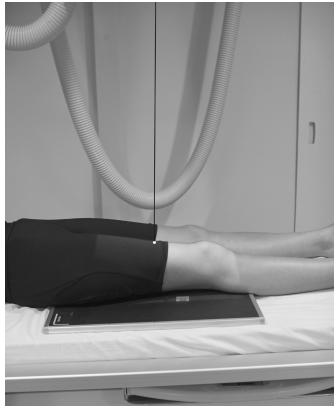

Fig. 2.26a Positioning for antero-posterior projection of the femur.

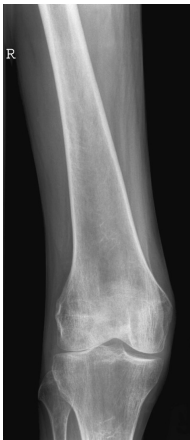

Fig. 2.26b Antero-posterior femur projection – knee up.

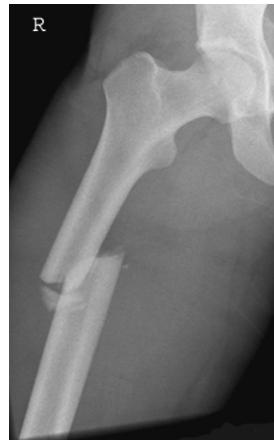

Fig. 2.26c Antero-posterior femur projection – hip down.

FEMUR – LATERAL

Position of Patient and Image Receptor (Fig. 2.27a)

- From the antero-posterior position, the patient rotates onto the affected side. The knee is slightly flexed and the patient adjusted so that the thigh is positioned on the centre line of the table.
- The pelvis is rotated backwards to separate the thighs.
- The position of the limb is then adjusted to vertically superimpose the femoral condyles.
- Pads are used to support the opposite limb in a position behind the one being examined.
- The image receptor/Bucky mechanism is located directly under the lateral aspect of the thigh to include the knee joint and as much of the femur as possible.
- Alternatively, a CR cassette or mobile DDR detector is positioned directly under the thigh to include the knee and hip joints.

Direction and Location of X-ray Beam

- The collimated vertical beam is centred on the middle of the femoral shaft, with the central ray parallel to the imaginary line joining the femoral condyles.

Essential Image Characteristics (Figs 2.27b, c)

- The whole length of the femur, including the hip and knee joints, should be visualised.

Additional Considerations

- An additional projection of the hip joint using a grid is often required if coverage is not initially achieved or image quality is affected by scatter and/or noise in the proximal femur. However, this will depend on the clinical information required and the patient's size.

Expected DRL: ESD 1.42 mGy

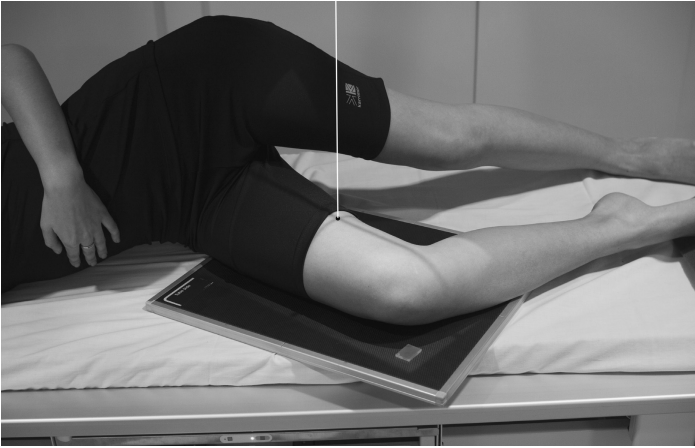


Fig. 2.27a Positioning for lateral femur projection.

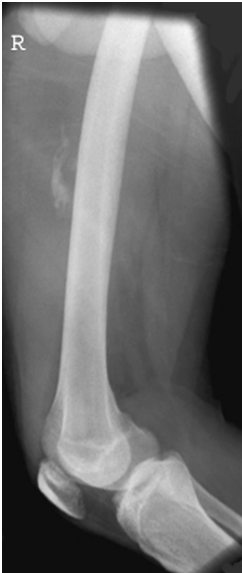

Fig. 2.27b Lateral femur – knee up.

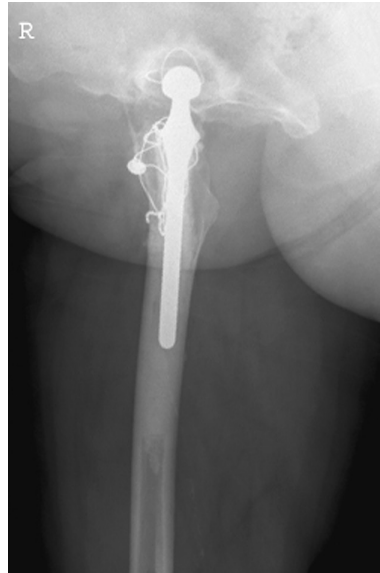

Fig. 2.27c Lateral femur – ‘hip down’, demonstrating a hip prosthesis.

FINGERS – DORSI-PALMAR

Position of Patient and Image Receptor (Fig. 2.28a)

- The patient is seated alongside the table, as for a dorsi-palmar projection of the hand (see page 118).
- The forearm is pronated with the anterior (palmar) aspect of the finger(s) in contact with the image receptor.
- The finger(s) are extended and separated.
- A sandbag is placed across the dorsal surface of the wrist for immobilisation.

Direction and Location of X-ray beam

- The collimated vertical beam is centred over the proximal interphalangeal joint of the affected finger.

Essential Image Characteristics (Fig. 2.28b)

- The image should include the fingertips and the distal third of the metacarpal bone.

Additional Considerations

- It is necessary to include adjacent finger(s), i.e. the second and third or fourth and fifth, to aid in identifying the relevant anatomy. If this is the case, then care should be taken to avoid superimposition, particularly in the lateral projection, by fully extending one finger and partly flexing the other.

Notes

- It is common practice to obtain two projections, a dorsi-palmar and a lateral.

Expected DRL: ESD 0.054 mGy

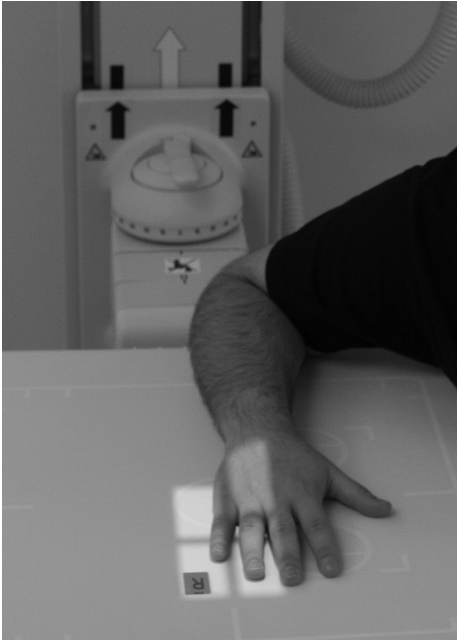

Fig. 2.28a Positioning for dorsi-palmar finger projection.

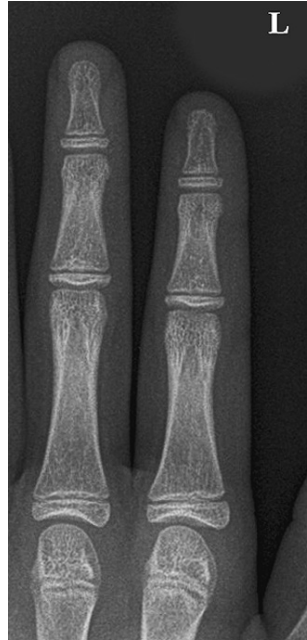

Fig. 2.28b Dorsi-palmar radiograph of the index and middle fingers – left hand.

FINGERS – LATERAL INDEX AND MIDDLE FINGERS

Position of Patient and Image Receptor (Fig. 2.29a)

- The patient is seated alongside the table with the arm abducted and medially rotated to bring the lateral aspect of the index finger in contact with the image receptor.
- The raised forearm is supported.
- The index finger is fully extended and the middle finger slightly flexed to avoid superimposition.
- The middle finger is supported on a non-opaque pad.
- The remaining fingers are fully flexed into the palm of the hand and held there by the thumb.

Direction and Location of X-ray Beam

- The collimated vertical beam is centred over the proximal interphalangeal joint of the affected finger.

Essential Image Characteristics (Fig. 2.29b)

- The image should include the fingertips and the distal third of the metacarpal bone.

Additional Considerations

- Scleroderma (one cause of Raynaud's disease) causes wasting and calcification of the soft tissue of the finger pulp.
- A chip fracture of the base of the dorsal aspect of the distal phalanx is associated with avulsion of the insertion of the extensor digitorum tendon, leading to the mallet finger deformity.
- In cases of severe trauma when the fingers cannot be flexed, it may be necessary to take a lateral projection of all the fingers superimposed, as for the lateral projection of the hand (see page 122), but centring over the proximal interphalangeal joint of the index finger.

Notes

- It is common practice to obtain two projections, a dorsi-palmar and a lateral.

Expected DRL: ESD 0.0.54 mGy




Fig. 2.29a Patient positioning for lateral projection of index and middle fingers.

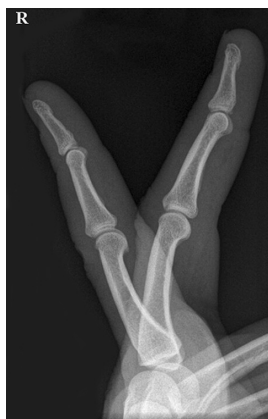

Fig. 2.29b Example of a normal lateral radiograph of the index and middle fingers.

FINGERS – LATERAL RING AND LITTLE FINGERS

Position of Patient and Image Receptor (Fig. 2.30a)

- The patient is seated alongside the table with the palm of the hand at right angles to the table and the medial aspect of the little finger in contact with the image receptor.
- The affected finger is extended and the remaining fingers are fully flexed into the palm of the hand and held there by the thumb in order to prevent superimposition.
- It may be necessary to support the ring finger on a non-opaque pad to ensure that it is parallel to the image receptor.

Direction and Location of X-ray Beam

- The collimated vertical beam is centred over the proximal interphalangeal joint of the affected finger.

Essential Image Characteristics (Fig. 2.30b)

- The image should include the fingertips and the distal third of the metacarpal bone.

Additional Considerations

- Scleroderma (one cause of Raynaud's disease) causes wasting and calcification of the soft tissue of the finger pulp.
- A chip fracture of the base of the dorsal aspect of the distal phalanx is associated with avulsion of the insertion of the extensor digitorum tendon, leading to the mallet finger deformity.
- In cases of severe trauma when the fingers cannot be flexed, it may be necessary to take a lateral projection of all the fingers superimposed, as for the lateral projection of the hand (see page 122), but centring over the proximal interphalangeal joint of the index finger.

Notes

- It is common practice to obtain two projections, a dorsi-palmar and a lateral.

Expected DRL: ESD 0.054 mGy




Fig. 2.30a Positioning for lateral ring and little fingers projection.

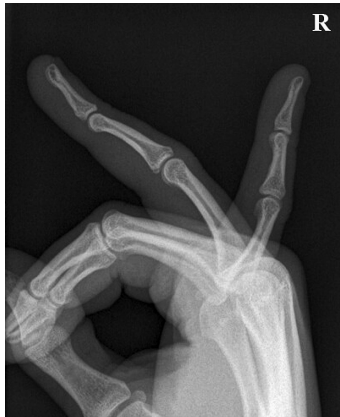

Fig. 2.30b Example of a lateral radiograph of the ring and little fingers.

FOOT – DORSI-PLANTAR

Position of Patient and Image Receptor (Fig. 2.31a)

- The patient is seated on the X-ray table, supported if necessary, with the hip and knee flexed.
- The plantar aspect of the foot is placed on the image receptor, and the lower leg is supported in the vertical position by the other knee.
- The receptor can be raised by 15 degrees to aid positioning, with a vertical central beam. This will improve the visualisation of the tarsal and tarso-metatarsal joints. This angulation compensates for the inclination of the longitudinal arch and reduces overshadowing of the tarsal bones.

Direction and Location of X-ray Beam

- The collimated vertical beam is centred over the cuboid-navicular joint midway between the palpable navicular tuberosity and the tuberosity of the fifth metatarsal.
- The X-ray tube is angled 15 degrees cranially when the receptor is parallel to the table.
- Alternatively, the X-ray beam can be vertical if the receptor is raised by 15 degrees.

Essential Image Characteristics (Fig. 2.31b)

- The tarsal and tarso-metatarsal joints should be demonstrated when the whole foot is examined.
- In trauma cases, it is helpful to include the medial and lateral malleoli to exclude bony injury to these areas.
- A wedge filter placed under the toes may be used to give a uniform range of densities, especially if the image is acquired using film/screen technology.

Expected DRL: ESD 0.075 mGy

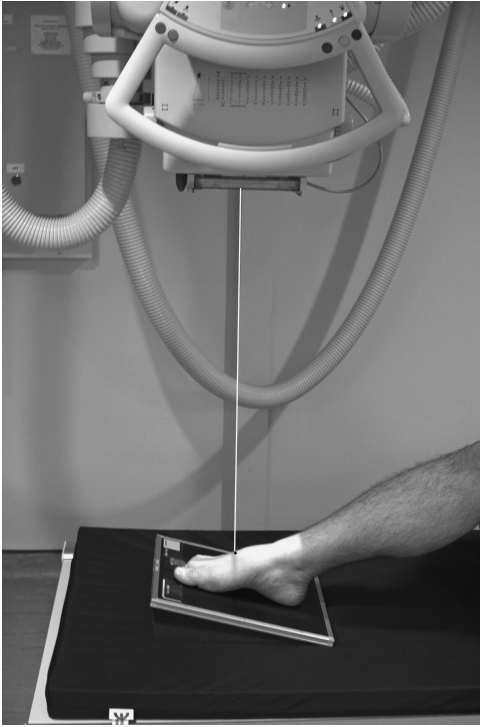

Fig. 2.31a Positioning for dorsi-plantar foot projection with a 15-degree angled pad.

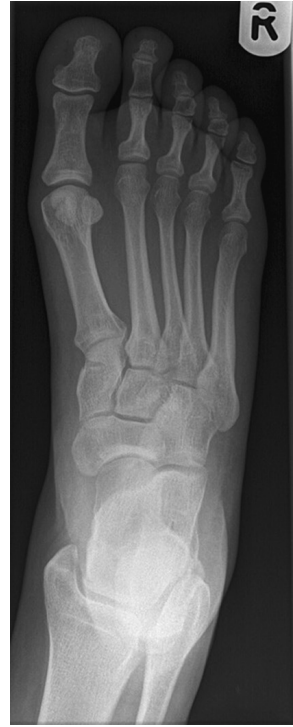

Fig. 2.31b Example of a normal dorsi-plantar foot radiograph.

FOOT – DORSI-PLANTAR OBLIQUE

Position of Patient and Image Receptor (Fig. 2.32a)

- From the basic dorsi-plantar position, the affected limb is leaned medially, bringing the plantar surface of the foot to a position approximately 30–45 degrees to the image receptor.
- A non-opaque angled pad is placed under the foot to maintain the position, with the opposite limb acting as a support.

Direction and Location of X-ray beam

- The collimated vertical beam is directed over the cuboid-navicular joint.

Essential Image Characteristics (Fig. 2.32b)

- The exposure and processing algorithm selected should produce an image that adequately demonstrates the differences in subject contrast and density between the toes and tarsus.
- The dorsi-plantar oblique projection should demonstrate the intertarsal and tarso-metatarsal joints.
- The base of the fifth metatarsal should be clearly seen.

Additional Considerations

- Be aware of the location of possible accessory ossicles around the foot. Do not confuse these with avulsion fractures, which are generally not as rounded in appearance.
- The appearance of the unfused apophysis at the base of the fifth metatarsal is variable in children and adolescents and frequently causes confusion. (As a rule of thumb, a fracture is transverse and an apophysis is parallel to the base of the fifth metatarsal.)

Expected DRL: ESD 0.076 mGy

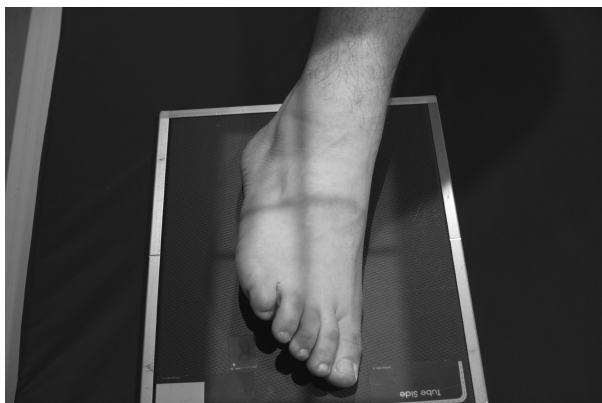

Fig. 2.32a Positioning for dorsi-plantar oblique foot projection.

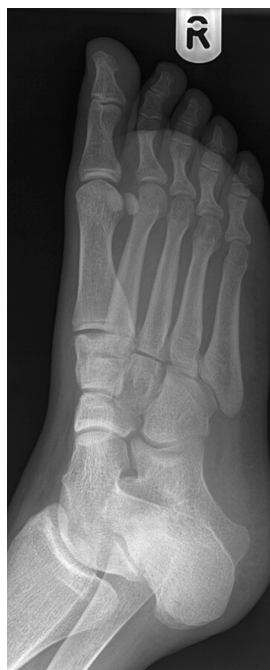

Fig. 2.32b Example of a normal dorsi-plantar oblique foot radiograph.

FOOT – LATERAL ERECT

Position of Patient and Image Receptor (Fig. 2.33a)

- The patient stands on a low platform with the receptor placed vertically between the feet.
- The feet are brought close together. The weight of the patient's body is distributed equally.
- To help maintain the position, the patient should rest their fore-arms on a convenient vertical support, e.g. the vertical Bucky or the platform support mechanism.

Direction and Location of X-ray Beam

- The collimated horizontal beam is centred on the tubercle of the fifth metatarsal.

Essential Image Characteristics (Fig. 2.33b)

- The image should include the distal phalanges and calcaneum.
- The ankle joint and soft tissue margins of the plantar aspect of the foot should be included.
- The longitudinal arches of the feet should be clearly demonstrated.

Additional Considerations

- Frequently, both feet are imaged for comparison.
- Images should be labelled as 'standing' or 'weight-bearing'.

Expected DRL: ESD 0.092 mGy

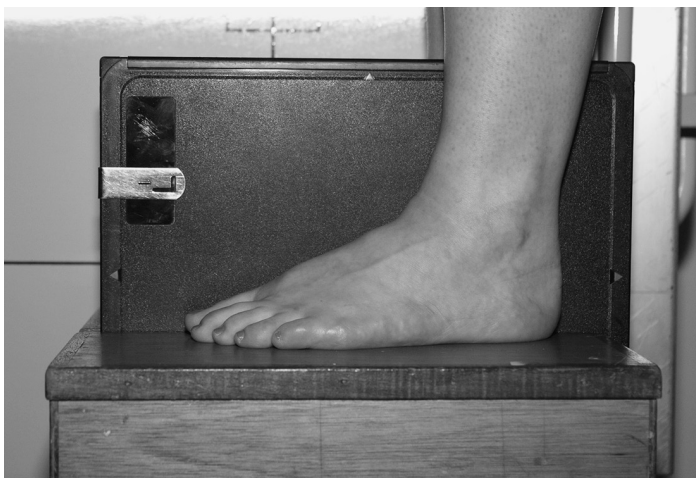

Fig. 2.33a Positioning for lateral erect foot projection.

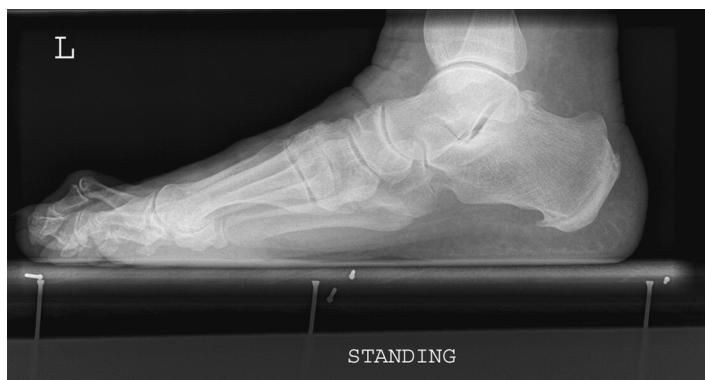

Fig. 2.33b Example of a normal lateral erect foot radiograph.

FOREARM – ANTERO-POSTERIOR

Position of Patient and Image Receptor (Fig. 2.34a)

- The patient is seated alongside the table, with the affected side nearest to the table.
- The arm is abducted and the elbow joint fully extended, with the supinated forearm resting on the table.
- The shoulder is lowered to the same level as the elbow joint.
- The image receptor is placed under the forearm to include the wrist joint and the elbow joint.
- The arm is adjusted such that the radial and ulnar styloid processes and the medial and lateral epicondyles are equidistant from the image receptor.
- The lower end of the humerus and the hand are immobilised using sandbags.

Direction and Location of X-ray Beam

- The collimated vertical beam is centred in the midline of the forearm to a point midway between the wrist and elbow joint.

Essential Image Characteristics (Fig. 2.34b)

- Both the elbow and the wrist joint must be demonstrated on the radiograph.
- Both joints should be seen in the true antero-posterior position, with the radial and ulnar styloid processes and the epicondyles of the humerus equidistant from the image receptor.

Notes

- When the patient is unable to extend the elbow to 90 degrees, a modified technique is used for the antero-posterior projection.
- If the limb cannot be moved, two projections at right angles to each other can be taken by keeping the limb in the same position and rotating the X-ray tube through 90 degrees.

- The postero-anterior projection of the forearm with the wrist pronated is not satisfactory because, in this projection, the radius is superimposed over the ulna for part of its length.

Expected DRL: ESD 0.13 mGy

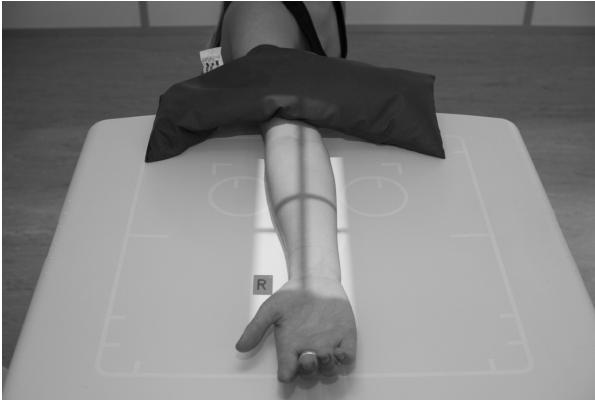


Fig. 2.34a Positioning for antero-posterior forearm projection.

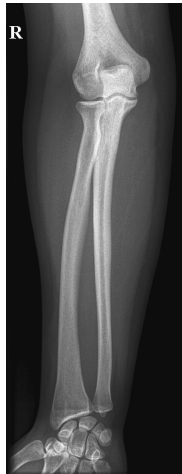

Fig. 2.34b Example of an antero-posterior forearm radiograph.

FOREARM – LATERAL

Position of Patient and Image Receptor (Fig. 2.35a)

- From the antero-posterior position, the elbow is flexed to 90 degrees.
- The humerus is internally rotated to 90 degrees to bring the medial aspect of the upper arm, elbow, forearm, wrist and hand in contact with the table.
- The image receptor is placed under the forearm to include the wrist joint and the elbow joint.
- The arm is adjusted such that the radial and ulnar styloid processes and the medial and lateral epicondyles are superimposed.
- The lower end of the humerus and the hand are immobilised using sandbags.

Direction and Location of X-ray beam

- The collimated vertical beam is centred in the midline of the forearm to a point midway between the wrist and elbow joints.

Essential Image Characteristics (Fig. 2.35b)

- Both the elbow and the wrist joint must be demonstrated on the image.
- Both joints should be seen in the true lateral position, with the radial and ulnar styloid processes and the epicondyles of the humerus superimposed.

Notes

- In trauma cases, it may be impossible to move the arm into the positions described, and a modified technique may need to be employed to ensure that diagnostic images are obtained.
- If the limb cannot be moved through 90 degrees, a horizontal beam should be used.
- Both joints should be included on each image.
- No attempt should be made to rotate the patient's hand.
- It is common practice to obtain two projections, a dorsi-palmar and a lateral

Expected DRL: ESD 0.13 mGy

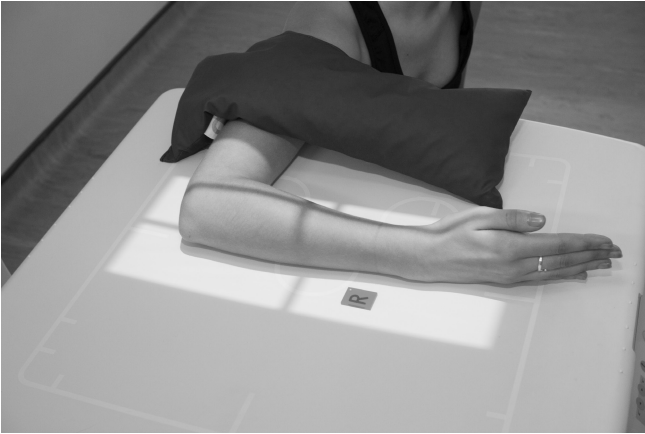

Fig. 2.35a Positioning for lateral forearm projection.

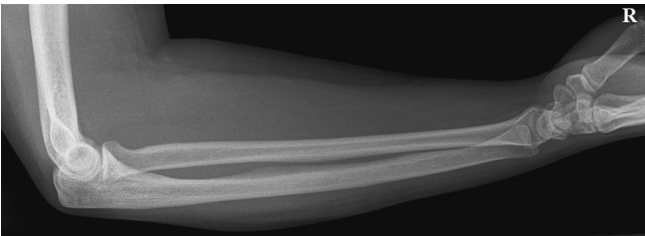


Fig. 2.35b Example of a lateral forearm radiograph.

HAND – DORSI-PALMAR

Position of Patient and Image Receptor (Fig. 2.36a)

- The patient is seated alongside the table with the affected arm nearest to the table.
- The forearm is pronated and placed on the table with the palmar surface of the hand in contact with the image receptor.
- The fingers are separated and extended but relaxed to ensure that they remain in contact with the image receptor.
- The wrist is adjusted so that the radial and ulnar styloid processes are equidistant from the image receptor.
- A sandbag is placed over the lower forearm for immobilisation.

Direction and Location of X-ray Beam

- The collimated vertical beam is centred over the head of the third metacarpal.

Essential Image Characteristics (Fig. 2.36b)

- The image should demonstrate all the phalanges, including the soft tissue of the fingertips, the carpal and metacarpal bones, and the distal end of the radius and ulna.
- The interphalangeal, metacarpo-phalangeal and carpo-metacarpal joints should be demonstrated clearly.
- The hand should not be rotated.

Notes

- It is common practice to obtain two projections, a dorsi-palmar and an oblique.

Expected DRL: ESD 0.058 mGy

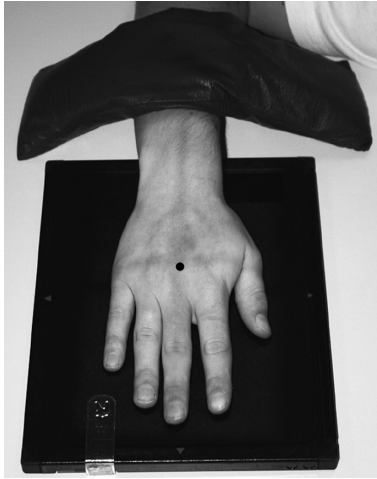


Fig. 2.36a Positioning for dorsi-palmar hand projection.

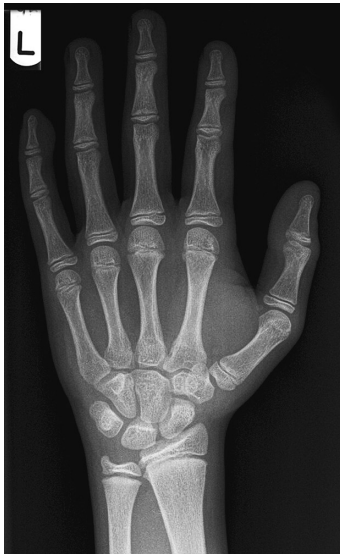

Fig. 2.36b Example of a dorsi-palmar hand radiograph.

HAND – DORSI-PALMAR OBLIQUE

Position of Patient and Image Receptor (Fig. 2.37a)

- From the basic dorsi-palmar position, the hand is externally rotated 45 degrees with the fingers extended in contact with the image receptor.
- The fingers should be separated slightly and the hand supported on a 45-degree non-opaque pad.
- A sandbag is placed over the lower end of the forearm for immobilisation.

Direction and Location of X-ray Beam

- The collimated vertical beam is centred over the head of the fifth metacarpal.
- The tube is then angled so that the central ray passes through the head of the third metacarpal, enabling a reduction in the size of the field.

Essential Image Characteristics (Fig. 2.37b)

- The image should demonstrate all the phalanges, including the soft tissue of the fingertips, the carpal and metacarpal bones, and the distal end of the radius and ulna.
- The exposure factors selected must produce a density and contrast that optimally demonstrate joint detail.
- The heads of the metacarpals should not be superimposed.

Expected DRL: ESD 0.060 mGy

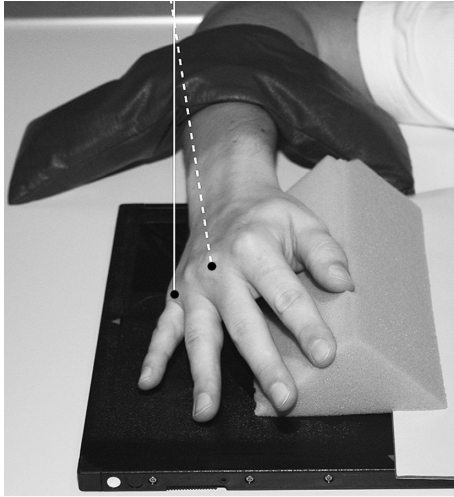

Fig. 2.37a Positioning for dorsi-palmar oblique hand projection.

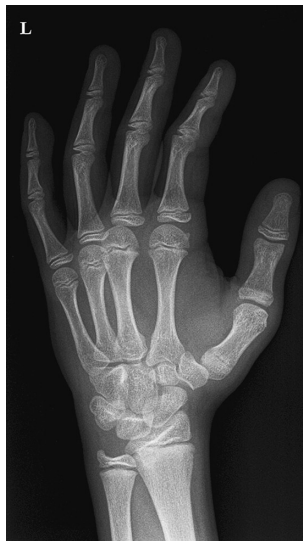

Fig. 2.37b Example of a dorsi-palmar oblique hand radiograph.

HAND – LATERAL

Position of Patient and Image Receptor (Fig. 2.38a)

- From the postero-anterior position, the hand is externally rotated by 90 degrees.
- The palm of the hand is perpendicular to the image receptor, with the fingers extended and the thumb abducted and supported parallel to the image receptor on a non-opaque pad.
- The radial and ulnar styloid processes are superimposed.

Direction and Location of X-ray Beam

- The collimated vertical beam is centred over head of the second metacarpal.

Essential Image Characteristics (Fig. 2.38b)

- The hand and wrist (like the ankle and foot) have many accessory ossicles, which may trap the unwary into a false diagnosis of pathology.
- A 'boxer's fracture' of the neck of the fifth metacarpal is seen easily, but conspicuity of fractures of the bases of the metacarpals is reduced by over-rotation and underexposure.

Notes

- If the projection is undertaken to identify the position of a foreign body, the kilovoltage should be lowered to demonstrate or exclude its presence in the soft tissues.
- A metal marker can be used to demonstrate the site of entry of the foreign body.

Expected DRL: ESD 0.081 mGy

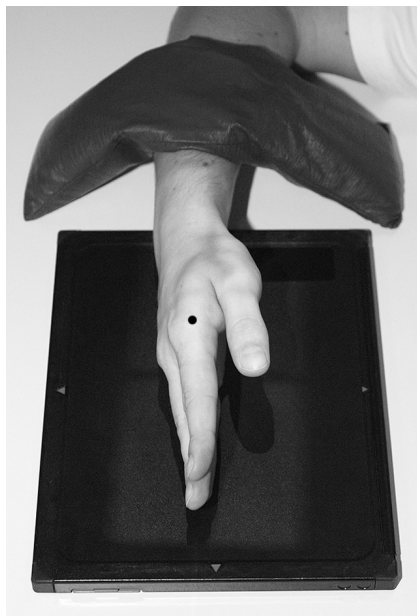


Fig. 2.38a Positioning for lateral hand projection.

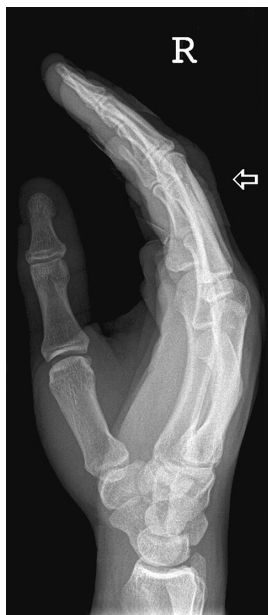

Fig. 2.38b Example of a lateral hand radiograph demonstrating a foreign body marker and healed fracture of the fifth metacarpal.

HIP (ANTERO-POSTERIOR) – SINGLE HIP

Position of Patient and Image Receptor (Fig. 2.39a)

- The patient is positioned as described for the basic pelvis and basic bilateral hip projections (see page 164).
- To avoid pelvic rotation, the anterior superior iliac spines must be positioned equidistant from the X-ray table top.
- The affected limb is internally rotated to bring the femoral neck parallel to the table top, supported by sandbags if necessary.

Direction and Location of X-ray Beam

- The collimated vertical beam is centred over the femoral pulse, 2.5 cm distally along the perpendicular bisector of a line joining the anterior superior iliac spine and the symphysis pubis.
- The primary beam should be collimated to the area under examination and gonad protection applied where appropriate.

Essential Image Characteristics (Fig. 2.39b)

- The acetabular floor, greater trochanter and proximal femur 2.5 cm below the lesser trochanter should be demonstrated, with the femoral neck in profile.
- The image must include the proximal third of femur, and when the examination is undertaken to show the positioning and integrity of an arthroplasty, the whole length of the prosthesis, including the femur inferior to the cement, must be visualised.

Notes

- Over-rotating the limb internally will bring the greater trochanter into profile. This may be a useful supplementary projection for a suspected avulsion fracture of this bone.
- When using conventional film/screen systems, care is needed when setting the exposure in order to optimise visualisation of the greater trochanters.

Expected DRL: ESD 2.83 mGy



Fig. 2.39a Positioning for antero-posterior single hip joint projection.

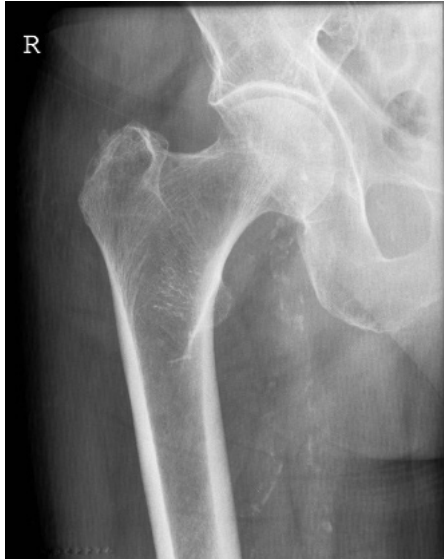

Fig. 2.39b Example of an antero-posterior hip radiograph.

HIP – LATERAL NECK OF FEMUR (TRAUMA)

This projection is used routinely in all cases of suspected fracture of the neck of femur. It is commonly carried out with the patient remaining on a trauma trolley as it is not advisable to move patients if there is a clinical suspicion of a fracture.

Position of Patient and Image Receptor (Fig. 2.40a)

- The patient lies supine on the trolley or X-ray table with their legs extended and the pelvis adjusted to ensure the median sagittal plane is perpendicular to the table top. If the patient is very slender, it may be necessary to place a non-opaque pad under the buttocks so that the whole of the affected hip can be included in the image.
- The CR grid cassette is positioned vertically, with the shorter edge pressed firmly against the waist, just above the iliac crest. The longitudinal axis of the cassette should be parallel to the neck of the femur. This can be approximated by placing a 45-degree foam pad between the front of the cassette/image receptor and the lateral aspect of the pelvis.
- The unaffected limb is then raised until the thigh is vertical, with the knee flexed. This position is maintained by supporting the lower leg on a stool or specialised equipment.

Direction and Location of X-ray Beam

- The collimated horizontal beam is centred through the affected groin midway between the femoral pulse and the palpable prominence of the greater trochanter, with the central ray directed horizontally and at right angles to the cassette and collimated closely to the area to improve the image contrast.

Essential Image Characteristics (Fig. 2.40b)

- A high quality image of the acetabulum, femoral neck, trochanters and upper third of the femur is assured with the use of a stationary grid and minimal ORD.

Notes

- A relatively high kilovoltage is necessary (e.g. 100 kV) to penetrate the thigh without overexposing the trochanteric region. Use of a (Ferlic) filter improves the overall optical density. It is essential to ensure that the cassette/image receptor is perpendicular to the central X-ray beam to exclude 'grid cut-off'.

Expected DRL: ESD 8.12 mGy

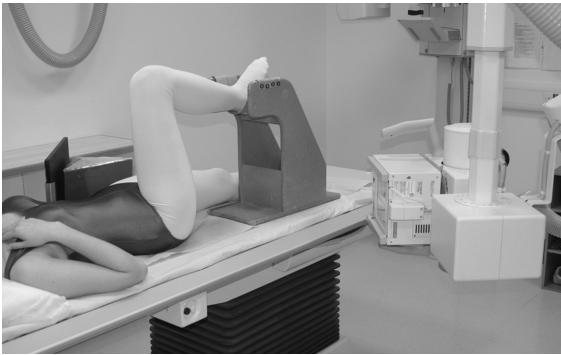


Fig. 2.40a Positioning for lateral neck of femur projection.

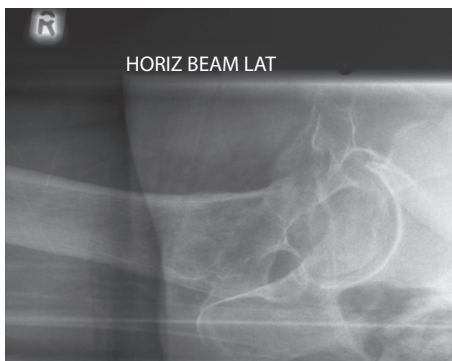


Fig. 2.40b Example of a lateral neck of femur radiograph showing a subcapital fracture.

HIP – LATERAL AIR-GAP TECHNIQUE

This technique is used as an alternative projection to the standard horizontal beam lateral and can produce an image with improved resolution due to the reduction in scattered radiation incident upon the CR cassette/image receptor. This projection is used on a patient with a suspected femoral neck fracture.

A DDR detector in the vertical Bucky is used without a grid, or a 24 cm × 30 cm CR cassette is positioned vertically, in landscape position, in a vertical cassette holder or vertical Bucky without a grid.

Position of Patient and Image Receptor (Fig. 2.41a)

- The patient lies supine on the trolley or X-ray table with the pelvis adjusted to ensure there is no rotation.
- The unaffected limb is then raised until the thigh is vertical, with the knee flexed. This position is maintained by supporting the lower leg on a stool or specialised equipment. The trolley is rotated to an angle of approximately 45 degrees to bring the longitudinal axis of the affected femoral neck parallel to the cassette/receptor.
- The tube is positioned with a FRD of 150 cm to compensate for the increased object-to-receptor distance (ORD) caused by the patient's rotation.

Direction and Location of X-ray Beam

- The collimated horizontal beam is centred through the affected groin at the position of the groin crease, with the central ray directed horizontally and at right angles to the receptor and collimated closely to the area to improve the image contrast.

Essential Image Characteristics (Fig. 2.41b)

- The image should be of high quality with improved resolution and high contrast, because with the previous horizontal beam lateral examination (see page 126) the femoral neck is optimally demonstrated with no foreshortening.

- Careful technique and close collimation will assist in reducing the patient dose.

Expected DRL: ESD 8.12 mGy



Fig. 2.41a Positioning for lateral neck of femur projection using the air-gap technique.

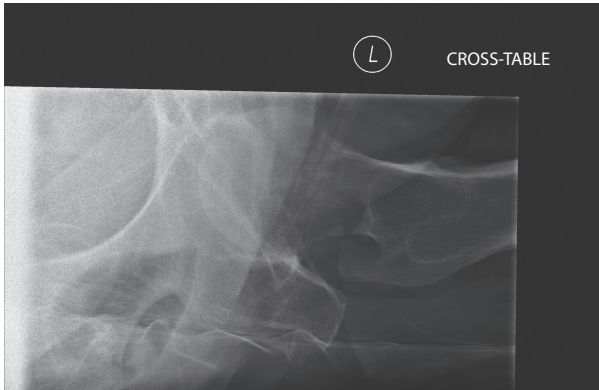

Fig. 2.41b Example of a lateral neck of femur radiograph using the air-gap technique, demonstrating the high resolution.

HIP – POSTERIOR OBLIQUE (LAUENSTEIN'S)

This examination is undertaken on a non-fractured hip where the hip joint (rather than femoral neck) is being examined.

Position of Patient and Image Receptor (Fig. 2.42a)

- The patient lies supine on the X-ray table, with the legs extended. The median sagittal plane coincides with the long axis of the table Bucky.
- The patient rotates through 45 degrees onto the affected side with the hip abducted 45 degrees and flexed 45 degrees, supported in this position by non-opaque pads.
- The knee is flexed to bring the lateral aspect of the thigh in contact with the table top, and the knee rests on the table in the lateral position with the opposite limb raised and supported.
- The image receptor is centred at the level of the femoral pulse in the groin and should include the proximal third of femur. The upper border of the image receptor should be level with the anterior superior iliac spine.

Direction and Location of X-ray beam

- The collimated vertical beam is centred on the femoral pulse in the groin on the affected side, with the central ray perpendicular to the image receptor.
- The long axis of the primary beam is adjusted by turning the light beam diaphragm to coincide with the long axis of the femur.
- The primary beam needs to be collimated to the area under examination.

Essential Image Characteristics (Fig. 2.42b)

- This projection is not used to demonstrate the neck of femur and should not be used as a first-line projection for a suspected fracture in this region.
- Used in conjunction with the antero-posterior projection, it shows the satisfactory position of pins and plates for internal fixation.

Notes

- If the unaffected side is raised more than 45 degrees, the superior pubic ramus may be superimposed on the acetabulum.
- The patient requires a degree of mobility to be positioned satisfactorily and should not experience any great discomfort in maintaining the position.



Fig. 2.42a Positioning for posterior oblique hip joint projection.

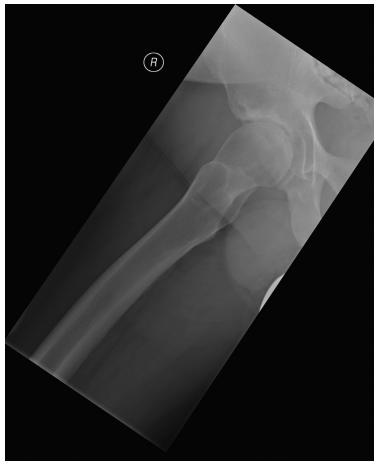

Fig. 2.42b Example of a posterior oblique hip joint radiograph.

HIPS (BOTH) – LATERAL ('FROG'S LEGS' POSITION)

Position of Patient and Image Receptor (Fig. 2.43a)

- To avoid rotation of the pelvis, the patient lies supine on the X-ray table with the anterior superior iliac spines equidistant from the table top.
- The median sagittal plane is perpendicular to the table and coincident with the centre of the table Bucky mechanism.
- The hips and knees are flexed and both limbs rotated laterally through approximately 60 degrees. This movement separates the knees and brings the plantar aspects of the feet in contact with each other.
- The limbs are supported in this position by pads and sandbags.
- The image receptor is centred at the level of the femoral pulse so that it includes both hip joints.

Direction and Location of X-ray Beam

- The collimated vertical beam is centred in the midline at the level of the femoral pulse, with the central ray perpendicular to the image receptor.

Essential Image Characteristics (Fig. 2.43b)

- The examination is undertaken to allow a comparison of both hip joints and femoral head epiphyses in paediatric patients; therefore the hip rotation should be equal to allow this.

Notes

- A lateral rotation of 60 degrees demonstrates the hip joints.
- A modified technique with the limbs rotated laterally through 15 degrees and the plantar aspect of the feet in contact with the table top demonstrates the neck of femur.
- If the patient is unable to achieve 60 degrees' rotation, it is important to apply the same degree of rotation to both limbs without losing symmetry.
- In very young children, a Bucky grid is not required. The child may be placed directly onto the image receptor.

Expected DRL: DAP 2.2 Gy·cm², ESD 4 mGy (adult)

Gonad protection must be correctly applied according to local protocol.




Fig. 2.43a Positioning for 'frog's legs' lateral projection.

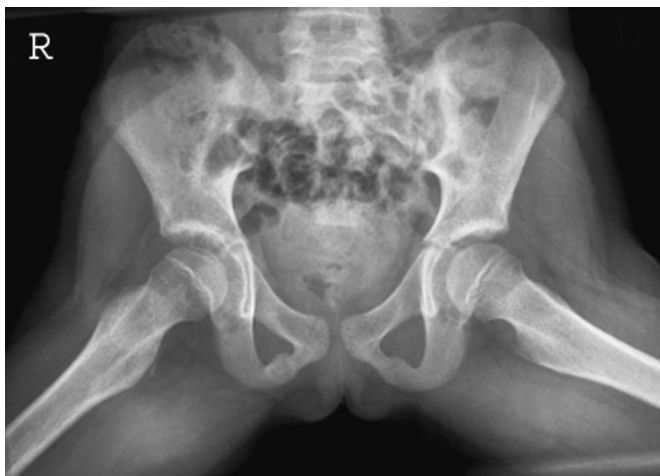

Fig. 2.43b Example of a 'frog's legs' lateral radiograph.

HUMERUS – ANTERO-POSTERIOR

Position of Patient and Image Receptor (Fig. 2.44a)

- The image receptor is placed in an erect holder.
- The patient sits or stands with their back in contact with the image receptor.
- The patient is rotated towards the affected side to bring the posterior aspect of the shoulder, upper arm and elbow in contact with the image receptor.
- The position of the patient is adjusted to ensure that the medial and lateral epicondyles of the humerus are equidistant from the image receptor.

Direction and Location of X-ray Beam

- The collimated horizontal beam is directed at right angles to the shaft of the humerus and centred midway between the shoulder and elbow joint.

Essential Image Characteristics (Fig. 2.44b)

- The exposure should be adjusted to ensure that the area of interest is clearly visualised.
- Positioning the patient supine allows greater stability than positioning the patient standing.

Notes

- A type of injury commonly found in children is a fracture of the lower end of the humerus just proximal to the condyles (a supracondylar fracture). The injury is very painful and even small movements of the limb can exacerbate the injury, causing further damage to adjacent nerves and blood vessels.
- Any supporting sling should not be removed, and the patient should not be asked to extend the elbow joint or rotate the arm or forearm.
- It is common practice to obtain two projections, antero-posterior and lateral.

Expected DRL: ESD 0.28 mGy

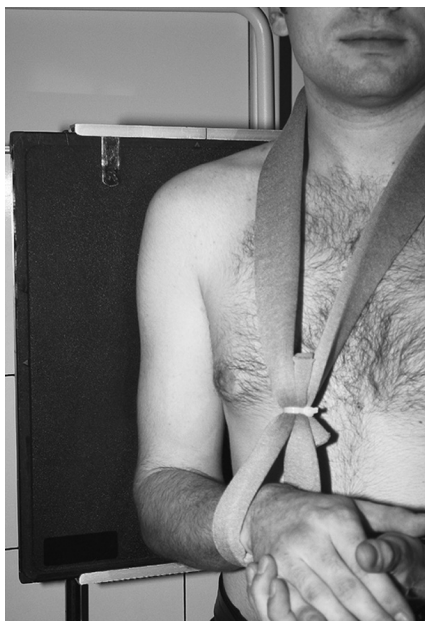

Fig. 2.44a Positioning for antero-posterior humerus projection – patient's arm in a sling.

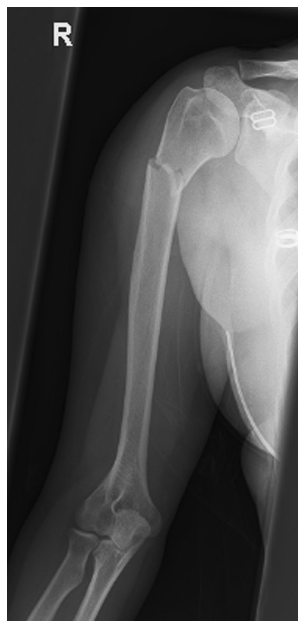

Fig. 2.44b Example of an antero-posterior radiograph of the right humerus showing a fracture of the proximal shaft of the humerus.

HUMERUS – LATERAL

Position of Patient and Image Receptor (Fig. 2.45a)

- The image receptor is placed in an erect holder.
- From the anterior position, the patient is rotated through 90 degrees until the lateral aspect of the injured arm is in contact with the image receptor.
- The patient's arm is then extended backwards and rotated further until the arm is just clear of the rib cage, but still in contact with the image receptor, with the medial and lateral epicondyles at right angles to the image receptor.

Direction and Location of X-ray Beam

- The collimated horizontal beam is directed at right angles to the shaft of the humerus and centred midway between the shoulder and elbow joints.

Essential Image Characteristics (Fig. 2.45b)

- The exposure should be adjusted to ensure that the area of interest is clearly visualised.

Notes

- The patient should be made as comfortable as possible to assist in immobilisation.
- An erect holder, or similar device, should be used to support the image receptor.
- The X-ray beam should be collimated carefully to ensure that the primary beam does not extend beyond the area of the image receptor.

Expected DRL: ESD 0.35 mGy

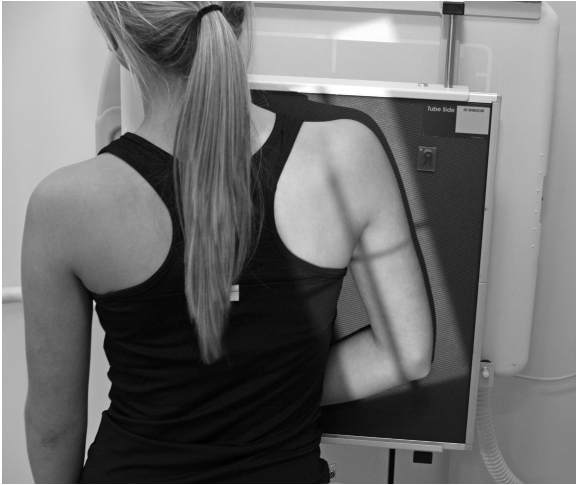

Fig. 2.45a Positioning for lateral humerus projection.

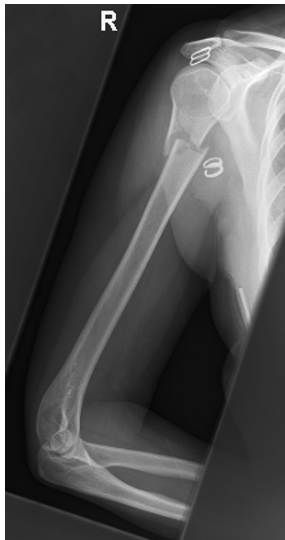

Fig. 2.45b Example of a lateral humerus radiograph showing a fracture of the proximal shaft of the humerus.

KNEE – ANTERO-POSTERIOR

Position of Patient and Image Receptor (Figs 2.46a, b)

- This projection can be obtained in the weight-bearing (erect) or supine (conventional) position.
- Unless the patient is unable to safely stand, the erect (weight-bearing) position is increasingly being obtained as the first-line projection.
- Erect: the patient stands with their back against the vertical Bucky or DDR receptor (grid removed), using it for support if necessary. The patient's weight is distributed equally.
- Supine: the patient is supine or seated on the table with both legs extended. The image receptor is positioned behind the knee joint.
- The knee is rotated so that the patella lies equally between the femoral condyles.
- The centre of the image receptor is level with the palpable upper borders of the tibial condyles.

Direction and Location of X-ray Beam

- The collimated horizontal beam is centred 1 cm below the apex of the patella through the joint space, with the central ray at 90 degrees to the long axis of the tibia (midway between the palpable upper borders of the tibial condyles).
- Occasionally, an X-ray of both knees is requested for a comparison, in which case the beam should be centred at a point midway between the knees at a level 1 cm below the two patellae.

Essential Image Characteristics (Fig. 2.46c)

- The patella must be centralised over the distal femoral condyles.
- The image should include the proximal third of the tibia and fibula and distal third of the femur.

Expected DRL: ESD 0.3 mGy



Fig. 2.46a Positioning for antero-posterior knee projection – standing.

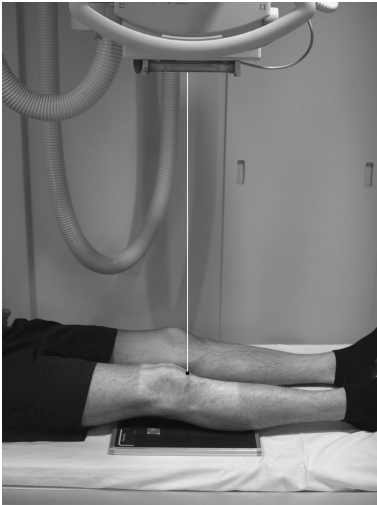

Fig. 2.46b Positioning for antero-posterior knee projection – supine.

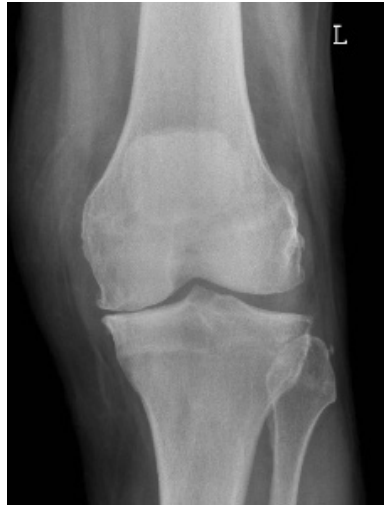

Fig. 2.46c Example of an erect antero-posterior radiograph of the knee showing degenerative changes.

KNEE – LATERAL (BASIC)

Position of Patient and Image Receptor (Fig. 2.47a)

- The patient lies on the side to be examined, with the knee flexed at 45 degrees (i.e. 135 degrees from back of calf to back of the thigh) or 90 degrees.
- The second limb is brought forward in front of the one being examined and supported on a sandbag.
- A sandbag is placed under the ankle of the affected side to bring the long axis of the tibia parallel to the image receptor. Dorsiflexion of the foot helps maintain this position.
- The position of the limb is now adjusted to ensure that the femoral condyles are superimposed vertically.
- The medial tibial condyle is placed level with the centre of the receptor.

Direction and Location of X-ray Beam

- The collimated vertical beam is centred on the middle of the superior border of the medial tibial condyle, with the central ray at 90 degrees to the long axis of the tibia.

Essential Image Characteristics (Fig. 2.47b)

- The patella should be projected clear of the femur.
- The femoral condyles should be superimposed.
- The proximal tibio-fibular joint is not clearly visible. (Approximately one third of the fibular head should be superimposed behind the tibia.)

Additional Considerations

- A small cranial tube angulation of 5–7 degrees can help superimpose the femoral condyles.
- Over-rotation = fibula is projected too posteriorly.
- Under-rotation = fibular head is hidden behind tibia.
- Identification of the adductor tubercle indicates the medial femoral condyle and can assist the radiographer to correct positioning faults.

- This projection may also be acquired in the weight-bearing position against a vertical detector.

Expected DRL: ESD 0.3 mGy



Fig. 2.47a Positioning for lateral knee (basic) projection.

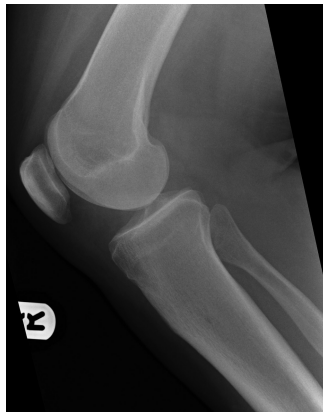

Fig. 2.47b Example of a lateral knee radiograph.

KNEE – HORIZONTAL BEAM LATERAL (TRAUMA)

Position of Patient and Image Receptor (Fig. 2.48a)

- The patient remains on the trolley/bed, with the limb gently raised and supported on pads.
- If possible, the leg can be rotated slightly to centralise the patella between the femoral condyles.
- For CR, a 24 cm × 30 cm image receptor is usually used.
- The imaging receptor is supported vertically against the medial aspect of the knee with its centre at the level of the upper border of the tibial condyle.

Direction and Location of X-ray Beam

- The collimated horizontal beam is centred on the upper border of the lateral tibial condyle, at 90 degrees to the long axis of the tibia.

Essential Image Characteristics (Fig. 2.48b)

- The image should demonstrate the lower third of the femur and proximal third of the tibia. The femoral condyles should be superimposed and the soft tissues adequately demonstrated to visualise any fluid levels within the suprapatellar pouch.

Additional Considerations

- This projection replaces the conventional lateral in all cases of gross injury and suspected fracture of the patella.
- No attempt must be made to either flex or extend the knee joint.
- Additional flexion may result in the fragments of a transverse patellar fracture being separated by the opposing muscle pull.
- Any rotation of the limb must be from the hip, with support given to the whole leg.
- By using a horizontal beam, fluid levels may be demonstrated, indicating lipohaemarthrosis.

Expected DRL: ESD 0.3 mGy

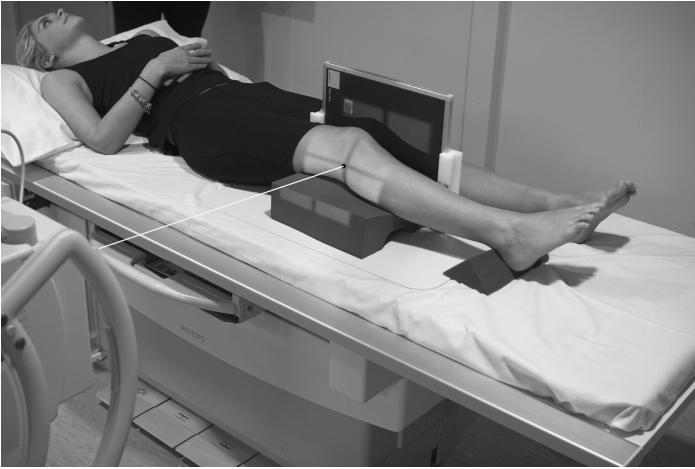

Fig. 2.48a Positioning for horizontal beam lateral knee projection.

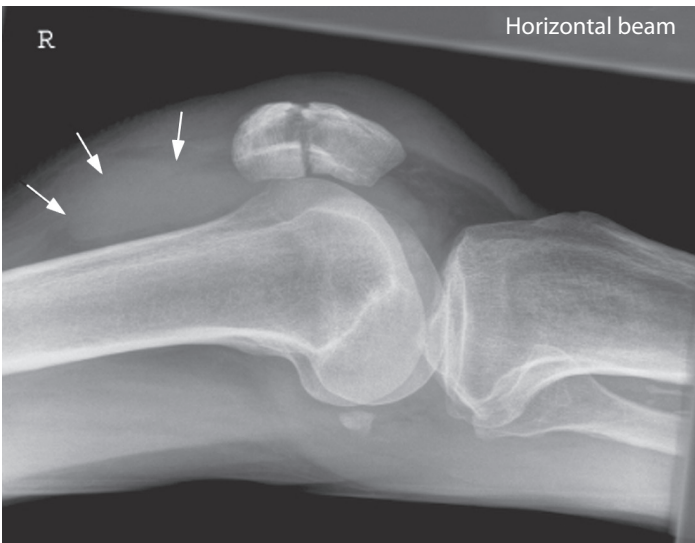

Fig. 2.48b Example of a horizontal beam knee radiograph showing a fracture of the patella with a joint effusion in the suprapatellar bursa (arrows).

KNEE – TUNNEL/INTERCONDYLAR NOTCH

Position of Patient and Image Receptor (Fig. 2.49a)

- The patient is either supine or seated on the X-ray table, with the affected knee flexed to approximately 60 degrees.
- A suitable pad is placed under the knee to help maintain the position.
- The limb is rotated to centralise the patella over the femur.
- The image receptor is placed on top of the pad as close as possible to the posterior aspect of the knee and displaced towards the femur. This method often utilises an 18 cm × 24 cm CR receptor, which can fit behind the knee.

Direction and Location of X-ray Beam

- The collimated beam is centred immediately below the apex of the patella.
- Two different tube angulations are used in relation to the long axis of the tibia: 90 degrees = the posterior aspect of the notch is shown; 100 degrees = the anterior aspect of the notch is shown.

Essential Image Characteristics (Figs 2.49b, c)

- The lower femur and upper tibia are included, with the intercondylar notch clearly seen; this should demonstrate any radio-opaque loose bodies.

Additional Considerations

- Commonly, only the 90 degree angulation is used.
- Take care when flexing the knee if a fracture is suspected.
- An alternative projection to obtain similar diagnostic information is the postero-anterior ('racing start') projection, which can be used in fitter patients who can tolerate the kneeling position.

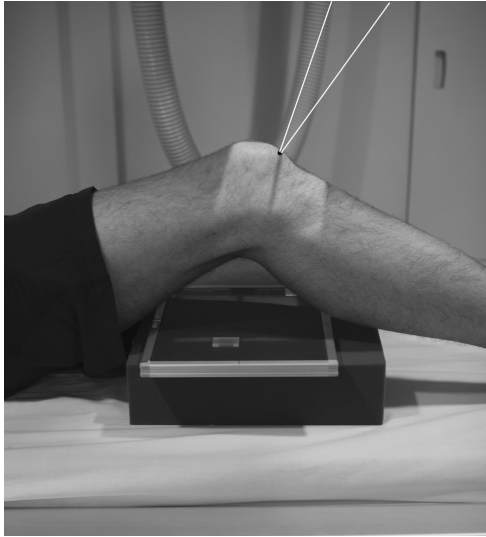


Fig. 2.49a Positioning for the intercondylar projection showing 90- and 110-degree beam angulations to the tibia.

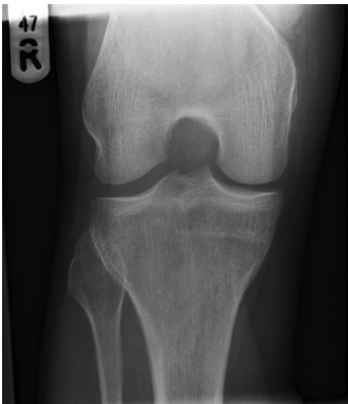

Fig. 2.49b Intercondylar image 90-degree angulation.

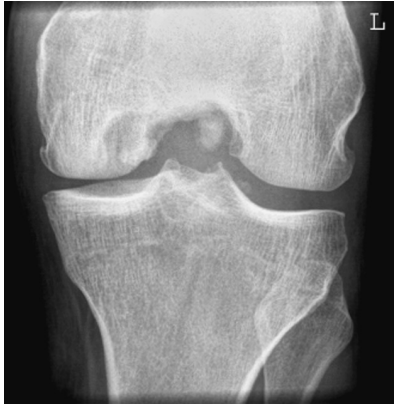

Fig. 2.49c Intercondylar image 110-degree angulation, showing a loose body.

KNEE – ‘SKYLINE’ PATELLAR (SUPERO-INFERIOR)

Position of Patient and Image Receptor (Fig. 2.50a)

- The patient sits on the X-ray table, with the affected knee flexed over the side.
- Ideally, the leg should be flexed to 45 degrees; however, some orthopaedic doctors may request skyline projections with a specified amount of flexion, for example 20 degrees, depending on the clinical situation and information required. Too much flexion reduces the retropatellar spacing. Sitting the patient on a cushion helps to achieve the optimum position.
- The receptor is supported horizontally on a stool at the level of the inferior tibial tuberosity border.
- This method describes the use of CR equipment. However, this could be adapted to be used with digital radiography equipment, using the erect detector placed in a horizontal position with the patient sitting on a chair with the knee overhanging the detector, as described above.

Direction and Location of X-ray Beam

- The collimated vertical central beam is centred over the posterior aspect of the proximal border of the patella. The central ray should be parallel to the long axis of the patella.
- The beam is collimated to the patella and femoral condyles.

Essential Image Characteristics (Fig. 2.50b)

- The retropatellar space should be clearly seen without superimposition of the femur or tibia within the patellofemoral joint.
- If there is insufficient flexion, the tibial tuberosity will overshadow the retropatellar joint.
- Too much flexion will cause the patella to track over the lateral femoral condyle.

Additional Considerations

- There are at least three methods of achieving the skyline patellar projection; however, the supero-inferior method is reasonably quick and has radiation protection advantages.
- Radiation protection should be provided to the gonads, and the patient should lean backwards, away from the primary beam.

Expected DRL: ESD 0.28 mGy

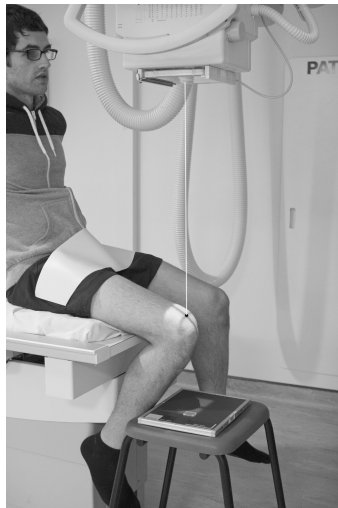

Fig. 2.50a Positioning for ‘skyline’ (supero-inferior) patellar projection.

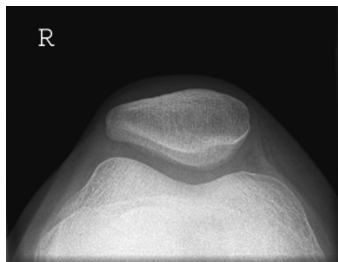


Fig. 2.50b Example of a normal skyline patellar radiograph.

LUMBAR SPINE – ANTERO-POSTERIOR

Position of Patient and Image Receptor (Fig. 2.51a)

- The patient lies supine on the Bucky table, with the median sagittal plane coincident with, and at right angles to, the midline of the table and Bucky.
- The anterior superior iliac spines should be equidistant from the table top.
- The hips and knees are flexed, and the feet are placed with their plantar aspect on the table top to reduce the lumbar arch and bring the lumbar region of the vertebral column parallel to the receptor.
- If a CR cassette is being used, it should be large enough to include the lower thoracic vertebrae and the sacro-iliac joints and is centred on the level of the lower costal margin.
- The exposure should be made on arrested expiration, as the diaphragm will cause the diaphragm to move superiorly. The air within the lungs would otherwise cause a large difference in density and poor contrast between the upper and lower lumbar vertebrae.

Direction and Location of X-ray Beam

- The collimated vertical beam is centred over the midline at the level of the lower costal margin (L3).

Essential Image Characteristics (Fig. 2.51b)

- The image should include the vertebrae from T12 down, to include the complete sacro-iliac joints.
- Rotation can be assessed by ensuring that the sacro-iliac joints are equidistant from the spine.
- The exposure and image processing should enable bony detail to be discerned throughout the region of interest.

Expected DRL: DAP 1.5 Gy·cm², ESD 5.7 mGy

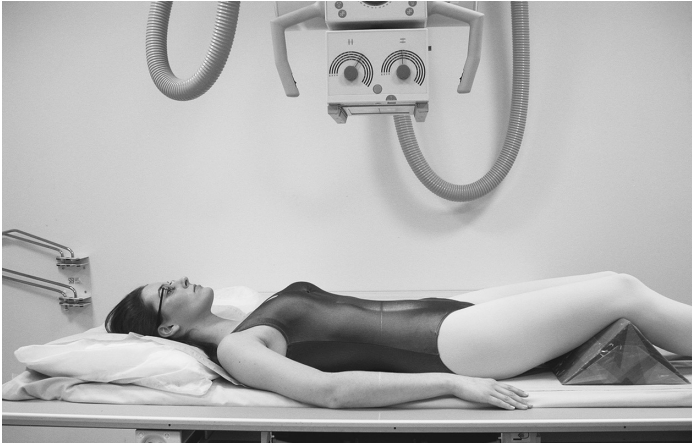

Fig. 2.51a Positioning for antero-posterior lumbar spine projection.

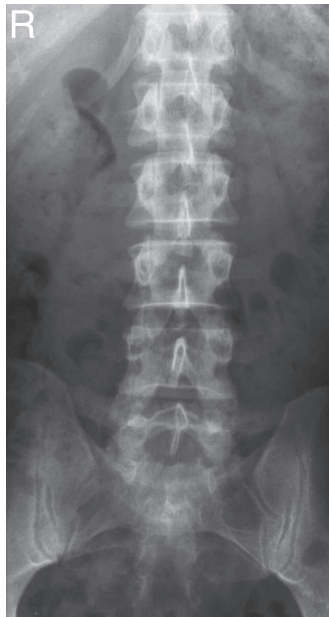

Fig. 2.51b Example of an antero-posterior lumbar spine radiograph.

LUMBAR SPINE – LATERAL

Position of Patient and Image Receptor (Fig. 2.52a)

- The patient can lie on either side on the Bucky table. If there is any degree of scoliosis, the most appropriate lateral position will be such that the concavity of the curve is towards the X-ray tube.
- The patient's arms should be raised and resting on the pillow in front of their head. The knees and hips are flexed for stability.
- The coronal plane running through the centre of the spine should coincide with, and be perpendicular to, the midline of the Bucky.
- Non-opaque pads may be placed under the waist and knees, as necessary, to bring the vertebral column parallel to the image receptor.
- The image receptor is centred on the level of the lower costal margin.
- The exposure should be made on arrested expiration.
- This projection can also be undertaken erect with the patient standing or sitting.

Direction and Location of X-ray Beam

- The collimated vertical beam is centred at right angles to the line of the spinous processes and towards a point 7.5 cm anterior to the third lumbar spinous process at the level of the lower costal margin.

Essential Image Characteristics (Fig. 2.52b)

- The image should include the T12 vertebra downwards, to include the lumbo-sacral junction.
- Ideally, the projection will produce a clear view through the centre of the intervertebral disc space, with individual vertebral end-plates superimposed.
- The cortices at the posterior and anterior margins of the vertebral body should also be superimposed.
- The imaging factors selected must produce sufficient image detail for diagnosis from T12 to L5/S1, including the spinous processes.

Expected DRL: DAP 2.5 Gy·cm², ESD 10 mGy

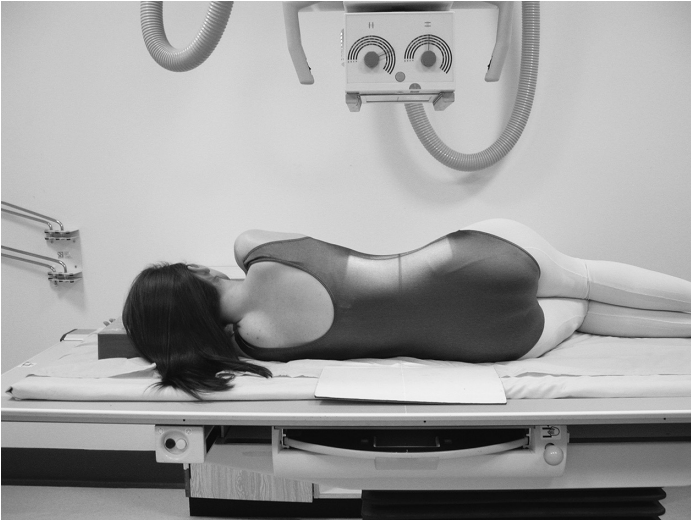

Fig. 2.52a Positioning for lateral lumbar spine projection.

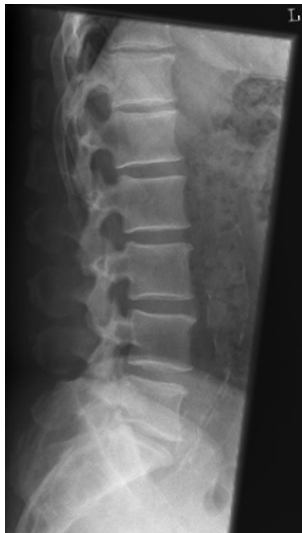

Fig. 2.52b Example of a lateral lumbar spine radiograph.

LUMBAR SPINE – OBLIQUE

Position of Patient and Image Receptor (Fig. 2.53a)

- The patient is positioned supine on the Bucky table and then rotated 45 degrees to the right and left sides in turn.
- The hips and knees are flexed, and the patient is supported with a 45-degree foam pad placed under the trunk on the raised side.
- The patient's arms can be moved away from the sides or can be raised, with the hands resting on the pillow.

Direction and Location of X-ray Beam

- The collimated vertical beam is centred towards the mid-clavicular line on the raised side at the level of the lower costal margin.

Essential Image Characteristics (Fig. 2.53b)

- The degree of obliquity should be such that the posterior elements of the vertebra are aligned in such a way as to show the classic 'Scottie dog' appearance.

Notes

- These projections demonstrate the pars interarticularis and the apophyseal joints on the side nearest the image receptor. Both sides are taken for comparison.

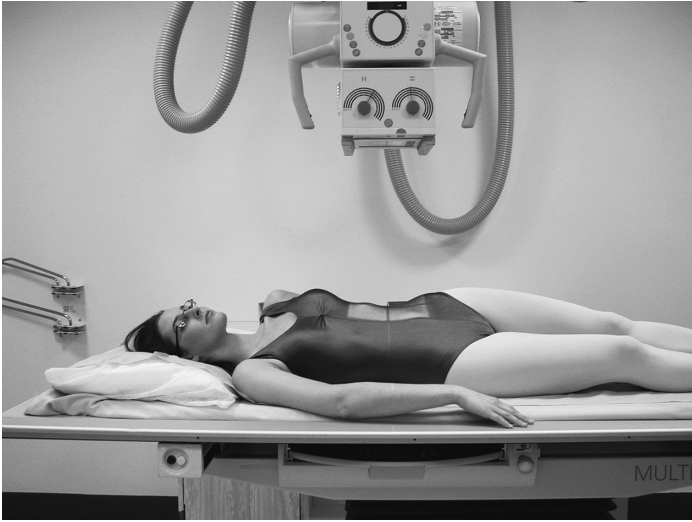

Fig. 2.53a Positioning for right posterior oblique lumbar spine projection.

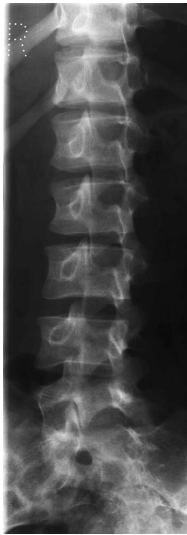

Fig. 2.53b Example of an oblique lumbar spine radiograph.

LUMBO-SACRAL JUNCTION (L5–S1) – LATERAL

Position of Patient and Image Receptor (Fig. 2.54a)

- The patient lies on either side on the Bucky table with the arms raised and the hands resting on the pillow. The knees and hips are flexed slightly for stability.
- The dorsal aspect of the trunk should be at right angles to the image receptor. This can be assessed by palpating the iliac crests or the posterior superior iliac spines.
- The coronal plane running through the centre of the spine should coincide with, and be perpendicular to, the midline of the Bucky.
- The image receptor is centred at the level of the fifth lumbar spinous process.
- Non-opaque pads may be placed under the waist and knees, as necessary, to bring the vertebral column parallel to the image receptor.

Direction and Location of X-ray Beam

- The collimated vertical beam is centred at right angles to the lumbo-sacral region and towards a point 7.5 cm anterior to the fifth lumbar spinous process. This is found at the level of the tubercle of the iliac crest or midway between the level of the upper border of the iliac crest and the anterior superior iliac spine.
- If the patient has particularly large hips and the spine is not parallel to the table top, a 5-degree caudal angulation may be required to clear the joint space.

Essential Image Characteristics (Fig. 2.54b)

- The area of interest should include the fifth lumbar vertebra and the first sacral segment.
- A clear joint space should be demonstrated.

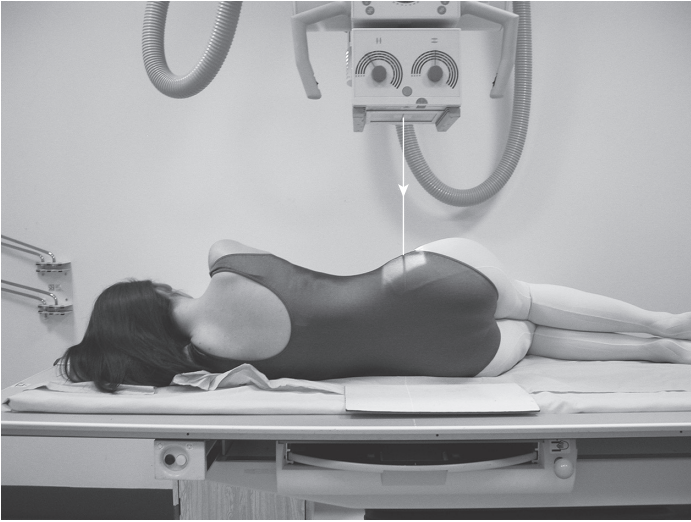

Fig. 2.54a Positioning for lateral lumbo-sacral junction projection.

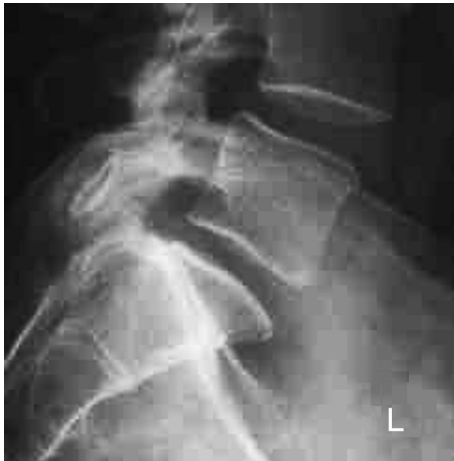

Fig. 2.54b Example of a lateral lumbo-sacral junction radiograph.

MANDIBLE – POSTERO-ANTERIOR

Position of Patient and Image Receptor (Fig. 2.55a)

- The patient sits erect facing the vertical Bucky/receptor (in the case of trauma, the projection may be taken anteroposteriorly).
- The patient's median sagittal plane should be coincident with the midline of the Bucky/receptor, and the patient's head is then adjusted to bring the orbito-meatal baseline perpendicular to the Bucky/receptor.
- The median sagittal plane should be perpendicular to the receptor. Check the external auditory meatuses are equidistant from the Bucky/receptor.
- An 18 cm × 24 cm CR cassette, if used, should be positioned such that, when placed longitudinally in the Bucky, it is centred at the level of the angles of the mandible.

Direction and Location of X-ray Beam

- The collimated central ray is directed perpendicular to the receptor and centred in the midline at the levels of the angles of the mandible.

Essential Image Characteristics (Fig. 2.55b)

- The whole of the mandible from the lower portions of the temporo-mandibular joints to the symphysis menti must be included in the image.
- There should be no rotation evident.

Additional Considerations

- This projection demonstrates the body and rami of the mandible and may show transverse or oblique fractures not evident on other projections or orthopantomography/dental panoramic tomography (OPG/DPT).
- The region of the symphysis menti is superimposed over the cervical vertebra, but fractures in this region are often better demonstrated than on OPG/DPT.

Notes

- A 10-degree cranial angulation of the beam may be required to demonstrate the mandibular condyles and temporo-mandibular joints.

Expected DRL: ESD 1.24 mGy



Fig. 2.55a Positioning for postero-anterior mandible projection.

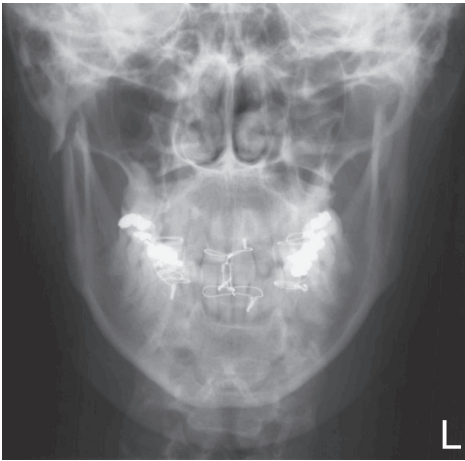


Fig. 2.55b Example of a postero-anterior mandible radiograph.

MANDIBLE – LATERAL OBLIQUE 30-DEGREE CRANIAL (SUPINE)

Position of Patient and Image Receptor (Fig. 2.56a)

- The patient lies in the supine position. The trunk is rotated slightly and then supported with pads to allow the side of the face being examined to come in contact with a CR cassette, which is supported using a thin wedge foam pad.
- The median sagittal plane should be parallel to the CR cassette and the inter-pupillary line perpendicular to both of these.
- The neck may be flexed slightly to clear the mandible from the spine.
- The long axis of the CR cassette should be parallel to the long axis of the mandible and the lower border positioned 2 cm below the lower border of the mandible.

Direction and Location of X-ray Beam

- The collimated vertical beam is angled 30 degree cranially at an angle of 60 degrees to the receptor and is centred 5 cm inferior to the angle of the mandible remote from the receptor.
- Collimate to include the whole of the mandible and temporo-mandibular joint (include the external auditory meatus at the edge of the collimation field).

Essential Image Characteristics (Fig. 2.56b)

- The body and ramus of each side of the mandible should not be superimposed.
- The image should include the whole of mandible from the temporo-mandibular joint to the symphysis menti.

Additional Considerations

- Do not mistake the mandibular canal, which transmits the inferior alveolar nerve, for a fracture.

Notes

- In cases of injury, both sides should be examined to demonstrate a possible contre-coup fracture.
- If the patient is mobile, this may be undertaken erect.

Expected DRL: ESD 0.66 mGy

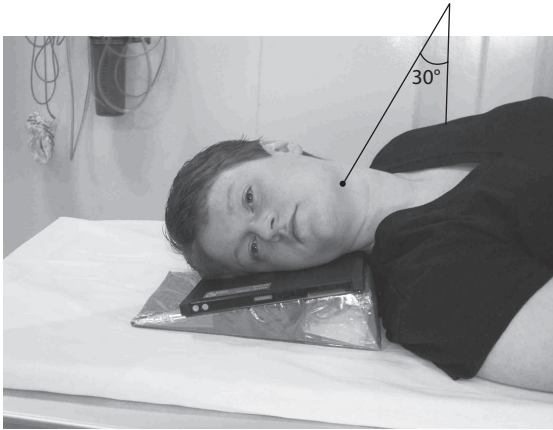


Fig. 2.56a Positioning for lateral oblique mandible projection.

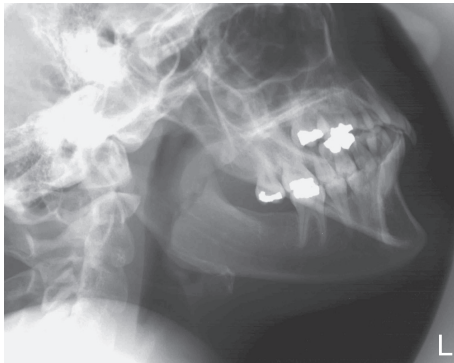

Fig. 2.56b Example of a lateral oblique mandible radiograph.

ORBITS – OCCIPITO-MENTAL (MODIFIED)

This is a frequently undertaken projection used to assess injuries to the orbital region (e.g. a blow-out fracture of the orbital floor) and to exclude the presence of metallic FBs in the eyes prior to MRI investigation.

Position of Patient and Image Receptor (Fig. 2.57a)

- The projection is best performed with the patient seated facing the receptor/vertical Bucky.
- The patient's nose and chin are placed in contact with the midline of the receptor/Bucky, and the head is then adjusted to bring the orbito-mental baseline to a 35-degree angle to the image receptor.
- The horizontal central line of the vertical Bucky/receptor should be at the level of the midpoint of the orbits.
- Ensure the median sagittal plane is at right angles to the Bucky/receptor by checking that the outer canthi of the eyes and the external auditory meatuses are equidistant from the image receptor.

Direction and Location of X-ray Beam

- If an erect Bucky is used, the tube should be centered on the Bucky using a collimated horizontal beam before positioning is undertaken.

Essential Image Characteristics (Figs 2.57b, c)

- The orbits should be roughly circular in appearance (they will be more oval in the occipito-mental projection).
- The petrous ridges should appear in the lower third of the maxillary sinuses. There should be no rotation.

Notes

- If the examination is purely to exclude foreign bodies within the orbit, tight 'letter box' collimation to the orbital region should be applied.
- A dedicated CR cassette should be used to assess for foreign bodies. This should be regularly cleaned to avoid small artefacts on the screens being confused with foreign bodies.



Fig. 2.57a Positioning for orbits – occipito-mental projection.

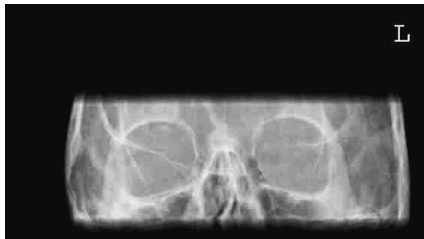


Fig. 2.57b Collimation used for a foreign-body projection.

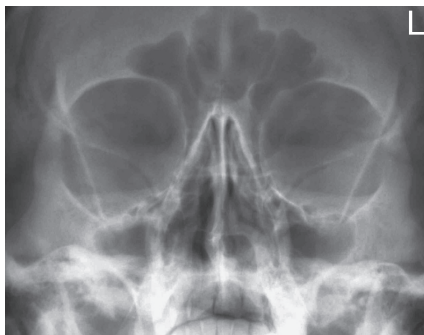


Fig. 2.57c Example of a radiograph of the orbits.

ORTHOPANTOMOGRAPHY (OPG/DPT)

Patient Preparation

- The patient should remove all radio-opaque objects from the head and neck areas.
- The unit should be readied in the start position and raised sufficiently to allow the patient to walk into the equipment. The examination can be carried out with the patient either standing or seated.
- Careful explanation of the procedure must be given to the patient as exposure times vary from 12 seconds for newer equipment up to 20 seconds for older panoramic units.

Position of Patient and Image Receptor (Fig. 2.58a)

- If used, a 15 cm × 30 cm cassette should be inserted into the cassette carrier; otherwise the digital unit is placed in the start position. Position a bite-block on the machine (or chin rest).
- Ask the patient to walk straight into the machine, gripping the handles if available, and ask them to adopt the 'ski position'. The patient's head should be tilted down towards the floor so that the Frankfort plane is parallel to floor. In this position, the ala–tragus line is 5 degrees caudal.
- Turn on the positioning lights and ensure that the sagittal plane light is shining down the middle of the face. The Frankfort plane should be 5 degrees down from ala–tragus line. The antero-posterior light should be centred distal to the upper lateral incisor (i.e. the lateral/canine interproximal space).
- Stand behind the patient and check the symmetry of position; adjust this if needed by holding the shoulders. Close the head restraints.
- Ask the patient to close their lips and press their tongue against the roof of their mouth. Closing the lips around the bite-block reduces the air shadow that can be mistaken for caries where it overlies the dentition in the premolar region.
- Explain again to the patient that they must stay absolutely still for about 20 seconds.
- Make the exposure (Fig. 2.58b).

Notes

- The technique is plagued with problems relating to positioning errors and patient movement – see the 13th edition of *Clark's Positioning in Radiography* (Whitley et al, 2016) for further information and essential characteristics.

Expected DRL: ESD 9.0 mGy

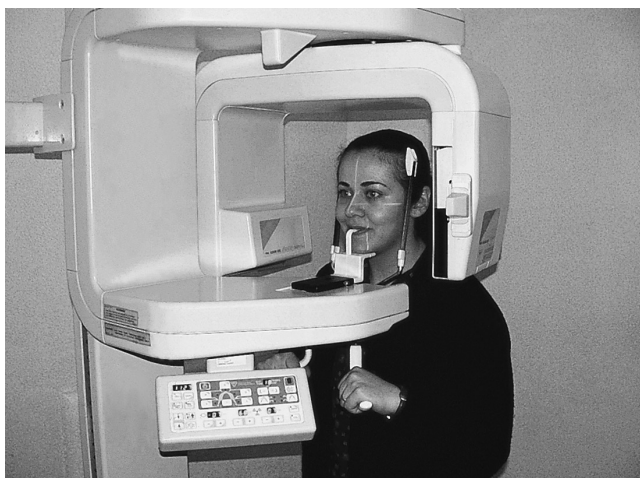


Fig. 2.58a Positioning for orthopantomography.

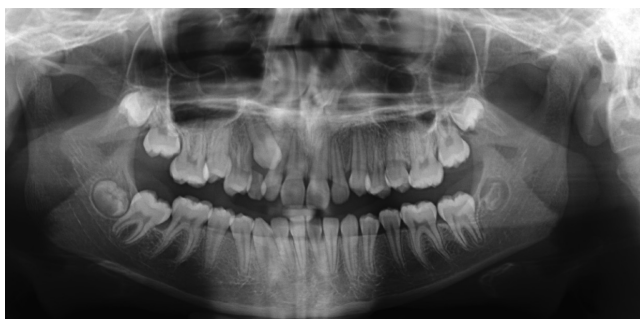

Fig. 2.58b Example of a correctly positioned orthopantomographic projection.

PELVIS – ANTERO-POSTERIOR

Position of Patient and Image Receptor (Fig. 2.59a)

- The patient lies supine and symmetrical on the X-ray table with the median sagittal plane perpendicular to the table top. The mid-line of the patient must coincide with the centred primary beam and table Bucky mechanism.
- To avoid pelvic rotation, the anterior superior iliac spines must be equidistant from the table top.
- The limbs are slightly abducted and internally rotated to bring the femoral necks parallel to the image receptor.

Direction and Location of X-ray Beam

- The collimated vertical beam is centred over the midline midway between the upper border of the symphysis pubis and anterior superior iliac spines to include the whole of the pelvis and proximal femora. The upper edge of the image receptor should be 5 cm above the upper border of the iliac crest.
- The centre of the image receptor is placed level with the upper border of the symphysis pubis for the hips and upper femora (low-centred pelvis).

Essential Image Characteristics (Fig. 2.59b)

- For the basic pelvic projection, both iliac crests and proximal femora, including the lesser trochanters, should be visible on the image.
- The exposure indicator reading should be adequate to visualise the bones of the posterior pelvis (sacrum and sacro-iliac joints) and the proximal femora.

Notes

- Internal rotation of the limb compensates for the X-ray beam divergence when centring in the midline. The resultant image will show both the greater and lesser trochanters.

- At the first clinic visit and in trauma cases, it is normal practice *not* to apply gonad protection, but it should be applied for any follow-up visits.

Expected DRL: DAP 2.2 Gy·cm², ESD 4 mGy

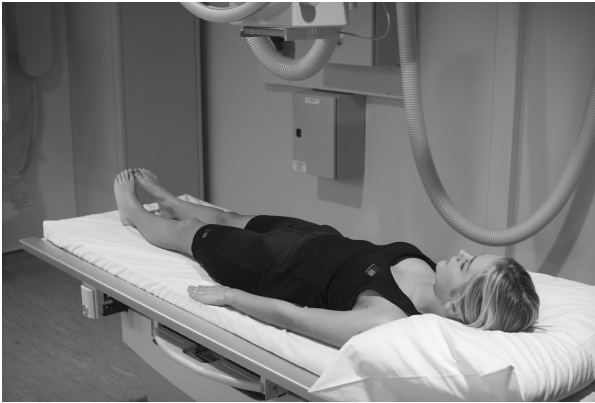

Fig. 2.59a Positioning for antero-posterior pelvic projection.

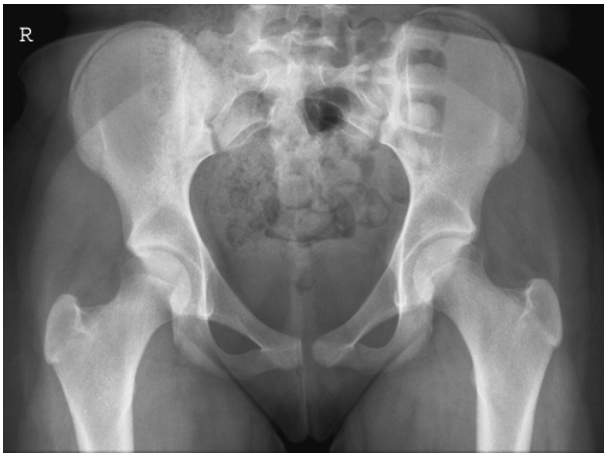

Fig. 2.59b Example of an antero-posterior pelvic radiograph.

SACRO-ILIAC JOINTS – POSTERO-ANTERIOR

The sacrum is situated posteriorly between the two iliac bones, the adjacent surfaces forming the sacro-iliac joints. These joint surfaces are oblique in direction, sloping backwards, inwards and downwards.

In the prone position, the oblique divergent rays coincide with the direction of the joints.

Position of Patient and Image Receptor (Figs 2.60a, b)

- The patient lies prone on the X-ray table with the median sagittal plane perpendicular to the table top.
- To avoid rotation, the posterior superior iliac spines should be equidistant from the table top.
- The midline of the patient should coincide with the centred primary beam and table Bucky mechanism.
- The image receptor is positioned so that the central ray passes through the centre of the image receptor.

Direction and Location of X-ray Beam

- The collimated vertical beam is centred in the midline at the level of the posterior superior iliac spines.
- The central ray is angled 5–15 degrees caudally from the vertical depending on the angulation of the patient's sacrum, which is generally greater in females due to the natural increased L5/S1 lordosis.
- The primary beam is collimated to the area of interest.

Notes

- The postero-anterior projection demonstrates the joints more effectively than the antero-posterior projection. It also reduces the radiation dose to the gonads in comparison to the antero-posterior projection.
- Additional imaging may be required as some pathologies, such as sacro-iliitis, can give rise to specific sacro-iliac joint pain and require more detailed demonstration of the joints with the aid of CT/MRI.

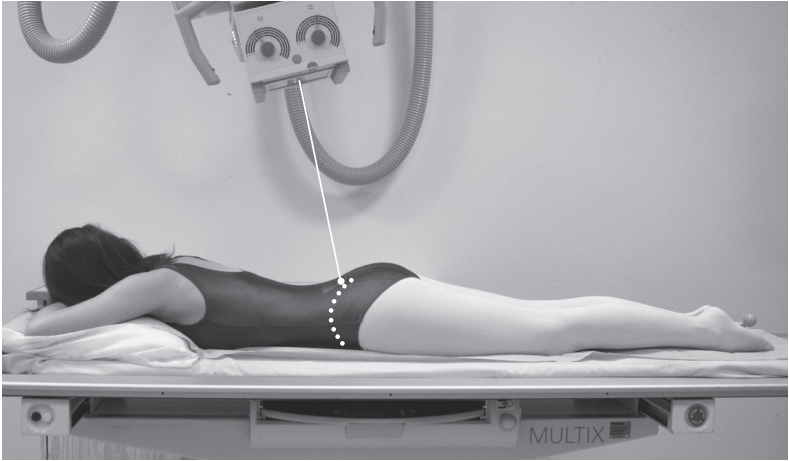


Fig. 2.60a Positioning for postero-anterior sacro-iliac joint projection.

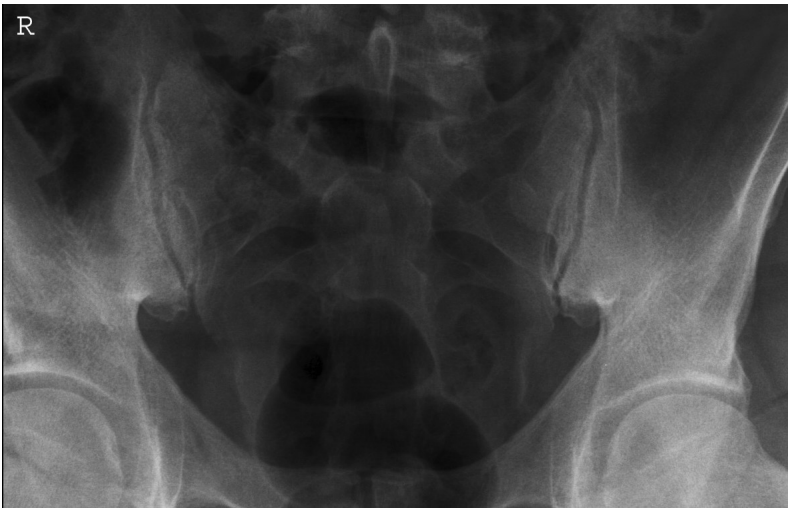

Fig. 2.60b Example of normal postero-anterior sacro-iliac joints.

SACRUM – ANTERO-POSTERIOR

The antero-posterior projection also demonstrates both sacro-iliac joints and the sacrum on one image and can be used when the patient is unable to turn prone.

A DDR detector is selected, or alternatively a 24 cm × 30 cm CR cassette can be placed in landscape mode in the table Bucky.

Position of Patient and Image Receptor (Figs 2.61a, b)

- The patient lies supine and symmetrical on the X-ray table with the median sagittal plane perpendicular to the table top.
- The midline of the patient must coincide with the centred primary beam and table Bucky/detector.
- To avoid rotation, the anterior superior iliac spines must be equidistant from the table top.
- The shoulders are raised over a pillow to reduce the lumbar arch, and the knees are flexed over foam pads for comfort and also to reduce the lumbar lordosis.

Direction and Location of X-ray Beam

- The collimated vertical beam is centred in the midline at a level midway between the anterior superior iliac spines and superior border of the symphysis pubis.
- The central ray is directed between 5–15 degrees cranially depending on the sex of the patient due to the natural angulation of the male/female pelvis and the lordosis of the lower lumbar spine.
- Greater angulation of the beam is needed for female patients.

Notes

- The sacrum may need to be visualised in detail to assess the sacral foramina and body when a fracture is suspected. In addition, although the sacro-iliac joints are best demonstrated in the

postero-anterior projection, this may not be a feasible position for the patient, so the antero-posterior sacrum technique may be used as an alternative.

Expected DRL: ESD 2.9 mGy*

* Based on a small sample size.

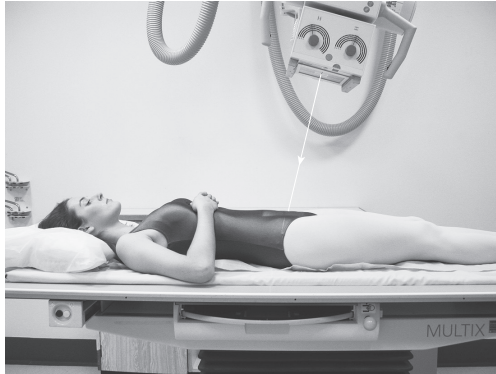

Fig. 2.61a Positioning for antero-posterior sacrum projection.

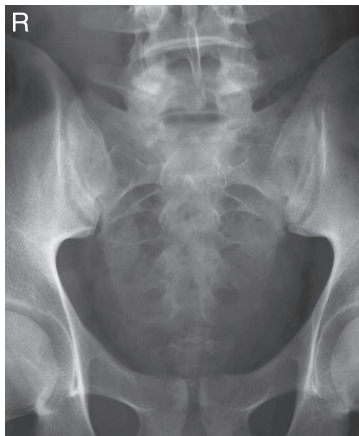

Fig. 2.61b Example of an antero-posterior sacrum radiograph.

SACRUM – LATERAL

This is a non-routine examination that delivers a large radiation dose to the patient and is therefore only indicated when a fracture is suspected, which is most commonly in an elderly patient. CT is the alternate examination and modality for fractures involving pelvic stability.

Position of Patient and Image Receptor (Fig. 2.62a)

- The patient can lie on either side on the Bucky table with the arms raised and the hands resting on a pillow. The knees and hips are flexed slightly for stability.
- The dorsal aspect of the trunk should be at right angles to the image receptor. This can be assessed by palpating the iliac crests or posterior superior iliac spines. The coronal plane running through the centre of the spine should coincide with, and be perpendicular to, the midline of the Bucky.
- The image receptor is centred to coincide with the central ray at the level of the midpoint of the sacrum.

Direction and Location of X-ray Beam

- The collimated vertical X-ray beam is directed towards the long axis of the sacrum. It is centred on a point in the midline of the table at a level midway between the posterior superior iliac spines and sacro-coccygeal junction.

Essential Image Characteristics (Fig. 2.62b)

- The image should include all the sacrum from the lumbo-sacral junction down to the sacro-coccygeal junction.
- The posterior collimation and imaging exposure factors should be sufficient to allow demonstration of the posterior spinous tubercle.

Additional Considerations

- Fractures may be missed if the image is underexposed or if there is some element of pelvic rotation.

Notes

- If using an automatic exposure control, inadequate centring (usually posteriorly) will result in an underexposed image.

Expected DRL: ESD 8.12 mGy*

* Based on a small sample.

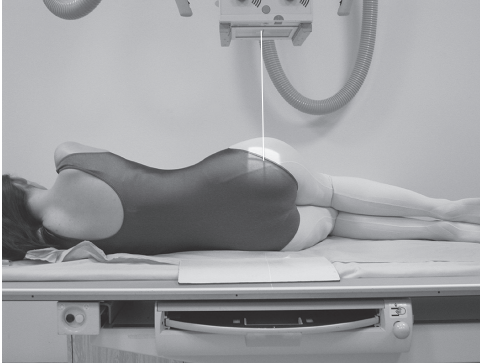

Fig. 2.62a Positioning for lateral sacrum projection.

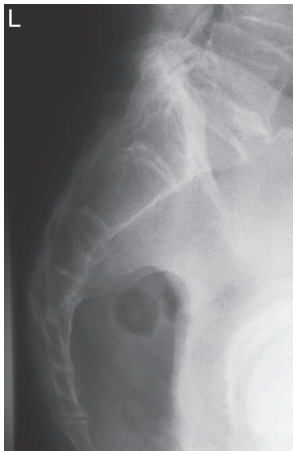


Fig. 2.62b Example of a lateral sacrum radiograph.

SCAPHOID POSTERO-ANTERIOR WITH ULNAR DEVIATION

For suspected scaphoid fractures, three or more projections may be taken: these are normally the postero-anterior and lateral (wrist projections; see pages 224–227), plus one or more of the three projections described in this book.

Position of Patient and Image Receptor (Fig. 2.63a)

- The patient is seated alongside the table, with the affected side nearest to the table.
- The arm is extended across the table with the elbow flexed and the forearm pronated.
- If possible, the shoulder, elbow and wrist should be at the level of the table top.
- The wrist is positioned over the centre of the image receptor and the hand is adducted (ulnar deviation).
- Ensure that the radial and ulnar styloid processes are equidistant from the image receptor.
- The hand and lower forearm are immobilised using sandbags.

Direction and Location of X-ray Beam

- The collimated vertical beam is centred midway between the radial and ulnar styloid processes.

Essential Image Characteristics (Fig. 2.63b)

- The image should include the distal end of the radius and ulna and the proximal end of the metacarpals.
- The joint space around the scaphoid should be clearly demonstrated.

Notes

- When the image is undertaken for a scaphoid view, the wrist should be in ulnar deviation.

Expected DRL: ESD 0.072 mGy




Fig. 2.63a Positioning for postero-anterior projection of the scaphoid with ulnar deviation.

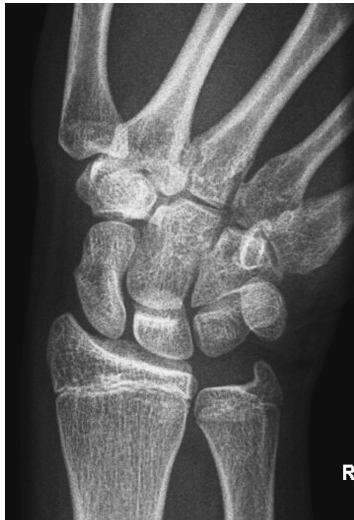

Fig. 2.63b Example of a postero-anterior scaphoid radiograph with ulnar deviation.

SCAPHOID – ANTERIOR OBLIQUE WITH ULNAR DEVIATION

Position of Patient and Image Receptor (Fig. 2.64a)

- From the postero-anterior position, the hand and wrist are rotated 45 degrees externally and placed central over an image receptor. The hand should remain adducted in ulnar deviation.
- The hand is supported in position, with a non-opaque pad placed under the thumb.
- The forearm is immobilised using a sandbag.

Direction and Location of X-ray Beam

- The collimated vertical beam is centred midway between the radial and ulnar styloid processes.

Essential Image Characteristics (Fig. 2.64b)

- The image should include the distal end of the radius and ulna and the proximal end of the metacarpals.
- The scaphoid should be seen clearly, with its long axis parallel to the image receptor.

Additional Considerations

- A carpal fracture is a break of one of the eight small bones of the carpus: the scaphoid, lunate, capitate, triquetrum, hamate, pisiform, trapezium and trapezoid. Although fractures of the other carpal bones occur, the scaphoid is accountable for 60–70% of fractures of the carpal bones.

Expected DRL: ESD 0.072 mGy




Fig. 2.64a Positioning for scaphoid anterior oblique projection with ulnar deviation.

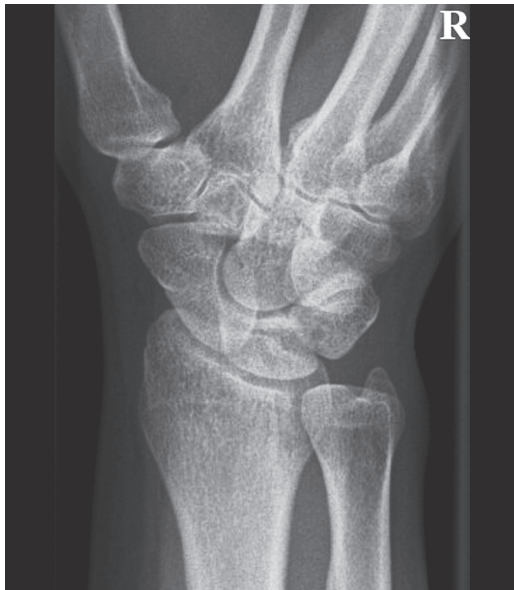

Fig. 2.64b Example of a lateral scaphoid anterior oblique radiograph with ulnar deviation.

SCAPHOID – POSTERIOR OBLIQUE

Position of Patient and Image Receptor (Fig. 2.65a)

- From the anterior oblique position, the hand and wrist are rotated externally through 90 degrees, such that the posterior aspect of the hand and wrist are at 45 degrees to the image receptor.
- The wrist is then supported on a 45-degree non-opaque foam pad.
- The forearm is immobilised using a sandbag.

Direction and Location of X-ray Beam

- The collimated vertical beam is centred over the styloid process of the ulna.

Essential Image Characteristics (Fig. 2.65b)

- The image should include the distal end of the radius and ulna and the proximal end of the metacarpals.
- The pisiform should be seen clearly in profile situated anterior to the triquetral.
- The long axis of the scaphoid should be seen perpendicular to the image receptor.

Expected DRL: ESD 0.072 mGy




Fig. 2.65a Positioning for posterior oblique scaphoid projection.

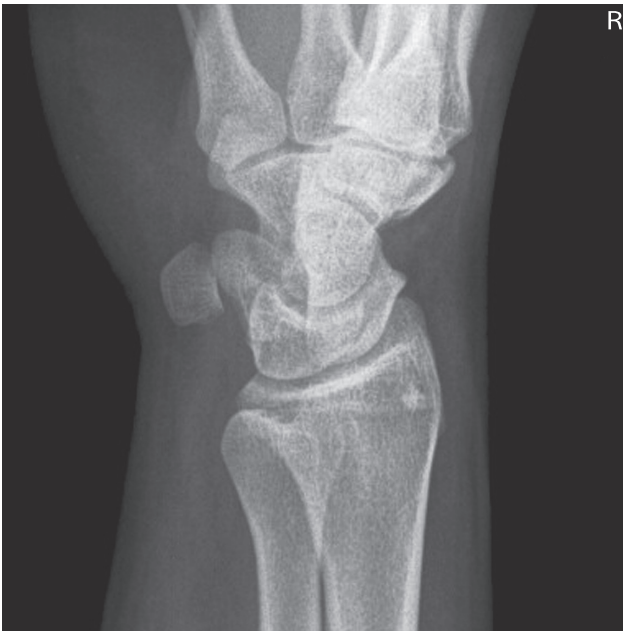

Fig. 2.65b Example of a posterior oblique scaphoid radiograph.

SCAPHOID – POSTERO-ANTERIOR, ULNAR DEVIATION AND 30-DEGREE CRANIAL

Position of Patient and Image Receptor (Fig. 2.66a)

- The patient and image receptor are positioned as for the postero-anterior scaphoid with ulnar deviation (see page 172).
- The wrist must be positioned to allow the X-ray tube to be angled at 30 degrees along the long axis of the scaphoid.

Direction and Location of X-ray Beam

- The collimated vertical beam is angled 30 degrees cranially and centred on the scaphoid.

Essential Image Characteristics (Fig. 2.66b)

- This projection elongates the scaphoid, and with ulnar deviation demonstrates the space surrounding the scaphoid.

Notes

- As the X-ray beam is directed towards the patient's trunk, radiation protection of the gonads should be applied.

Radiological Considerations

- Fracture of the waist of the scaphoid may not be clearly visible, if at all, at presentation. It carries a high risk of delayed avascular necrosis of the distal pole, which can cause severe disability.
- If a fracture is suspected clinically, the patient may be re-examined after 10 days of immobilisation; otherwise MRI may offer immediate diagnosis.

Expected DRL: ESD 0.072 mGy

Scaphoid – Postero-anterior, Ulnar Deviation and 30-degree Cranial

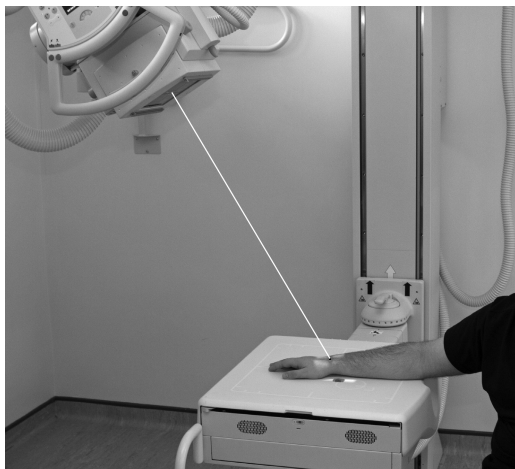

Fig. 2.66a Positioning for scaphoid postero-anterior projection with ulnar deviation and a 30-degree cranial angle.

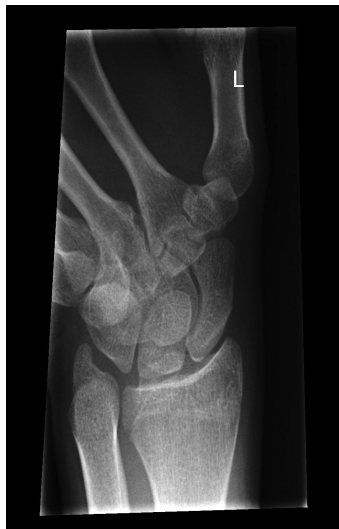

Fig. 2.66b Example of radiograph the scaphoid – postero-anterior, ulnar deviation and a 30-degree cranial angle.

SHOULDER GIRDLE – ANTERO-POSTERIOR (15-DEGREE) ERECT

Position of Patient and Image Receptor (Fig. 2.67a)

- The patient stands with the affected shoulder against the image receptor, and the torso is rotated approximately 15 degrees towards the affected side to bring the plane of the glenoid fossa perpendicular to the image receptor.
- The arm is supinated and slightly abducted away from the body.
- The image receptor is positioned so that its upper border is at least 5 cm above the shoulder to ensure that the oblique rays do not project the shoulder off the edge of the final image.
- The patient should be asked to rotate their head away from the side under examination to avoid superimposition of the chin over the medial end of the clavicle.

Direction and Location of X-ray Beam

- The collimated horizontal beam is directed to the palpable coracoid process of the scapula.

Essential Image Characteristics (Fig. 2.67b)

- The image should demonstrate the head of the humerus and proximal end of the humerus, the inferior angle of the scapula and the whole of the clavicle including the sternoclavicular joint.
- The head of the humerus should be seen *slightly* overlapping the glenoid cavity but separate from the acromion process.

Expected DRL: ESD 0.5 mGy

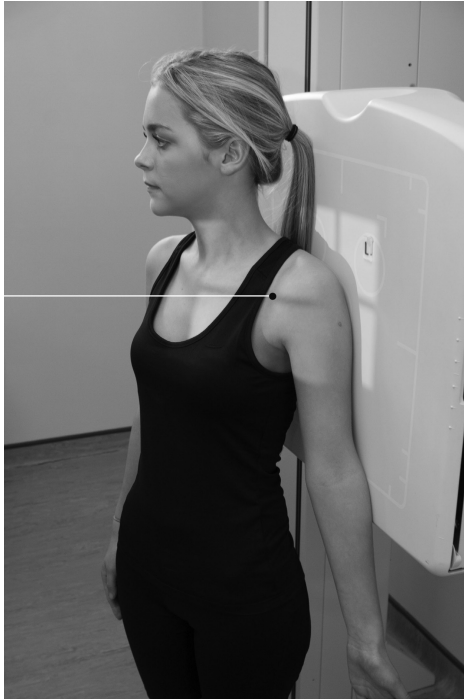


Fig. 2.67a Positioning for the antero-posterior shoulder girdle projection.

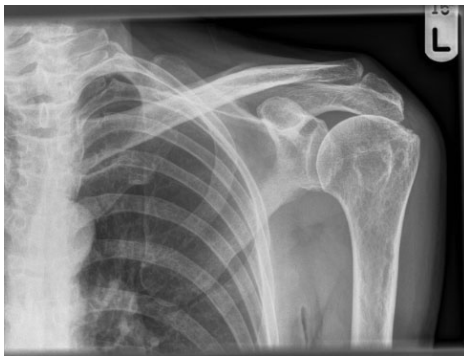

Fig. 2.67b Example of an antero-posterior shoulder girdle radiograph.

SHOULDER GIRDLE – ANTERO-POSTERIOR (GLENOHUMERAL JOINT) – MODIFIED (GRASHEY PROJECTION)

Position of Patient and Image Receptor (Fig. 2.68a)

- The patient stands with the affected shoulder against the image receptor and the torso is rotated approximately 35–45 degrees towards the affected side to bring the plane of the glenoid fossa perpendicular to the image receptor.
- The arm is supinated and slightly abducted.
- The image receptor is positioned so that its upper border is at least 5 cm above the shoulder to ensure that the oblique rays do not project the shoulder off the edge of the final image.
- The patient should be asked to rotate their head away from the side under examination to avoid superimposition of the chin over the medial end of the clavicle.

Direction and Location of X-ray Beam

- The collimated horizontal beam is directed to the palpable coracoid process of the scapula.

Essential Image Characteristics (Fig. 2.68b)

- The image should demonstrate a clear joint space between the head of the humerus and the glenoid cavity.
- The image should demonstrate the head, the greater and lesser tuberosities of the humerus, the lateral aspect of the scapula and the distal end of the clavicle.

Additional Considerations

- This projection is useful for demonstrating the glenohumeral joint in joint instability and for the narrowing seen in arthritis.



Fig. 2.68a Positioning for shoulder girdle – antero-posterior modified (Grashey) projection.

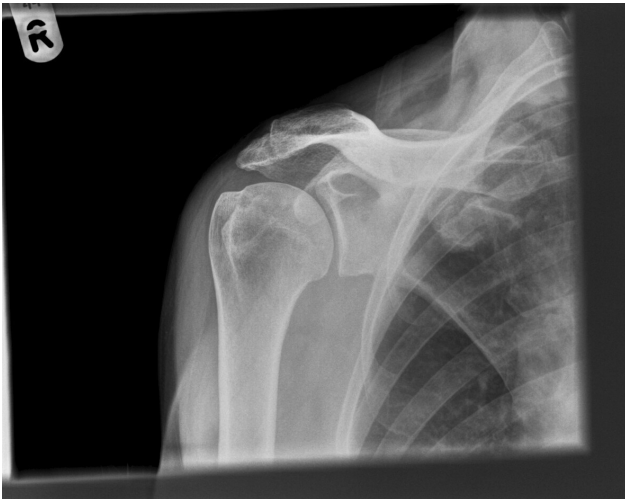

Fig. 2.68b Example of a Grashey projection radiograph.

SHOULDER – SUPERO-INFERIOR (AXIAL)

Position of Patient and Image Receptor (Fig. 2.69a)

- The patient is seated with their affected side adjacent to the table, which is lowered to waist level.
- The image receptor is placed on the table top, and the arm under examination is abducted over the table.
- The patient leans towards the table to reduce the ORD and ensure that the glenoid cavity is included in the image.
- The elbow can remain flexed, but the arm should be abducted to a minimum of 45 degrees, injury permitting. If only limited abduction is possible, the receptor may be supported on pads to reduce the ORD.

Direction and Location of X-ray Beam

- The collimated vertical beam is centred over the middle of the glenohumeral joint. Some tube angulation, towards the palm of the hand, may be necessary to coincide with the plane of the glenoid cavity.
- If there is a large ORD, it may be necessary to increase the overall FRD to reduce the magnification.

Essential Image Characteristics (Fig. 2.69b)

- The image must demonstrate the head of the humerus, the acromion process, the coracoid process and the glenoid cavity of the scapula.

Additional Considerations

- Trauma patients will have severe difficulty abducting their arm and should not be forced to do so. In such cases, it is recommended that an apical oblique projection is undertaken.

Expected DRL: ESD 0.58 mGy



Fig. 2.69a Positioning for supero-inferior (axial) shoulder projection.

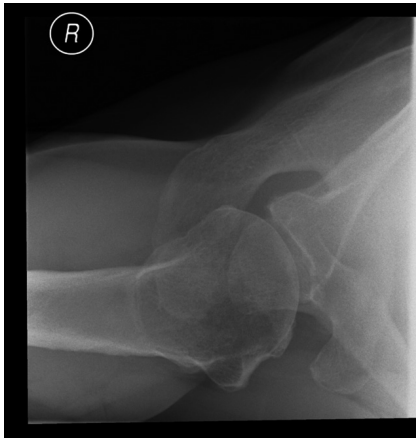


Fig. 2.69b Example of a supero-inferior (axial) shoulder radiograph.

SHOULDER – ANTERIOR OBLIQUE ('Y' PROJECTION)

Position of Patient and Image Receptor (Figs 2.70a, b)

- The patient stands or sits with the lateral aspect of the injured arm against the image receptor, and the shoulder is adjusted so that the axilla is in the centre of the receptor.
- The unaffected shoulder is raised to make the angle between the trunk and the receptor approximately 60 degrees. A line joining the medial and lateral borders of the scapula is now at right angles to the receptor.
- The image receptor is positioned to include the superior and inferior borders of the scapula.

Direction and Location of X-ray Beam

- The collimated horizontal beam is centred towards the medial border of the scapula and centred on the head of the humerus.
- Collimate to include the region 2 cm above the palpable acromion process superiorly, just below the inferior aspect of the scapula inferiorly, the posterior skin margin and 2 cm of the rib cage anteriorly.

Essential Image Characteristics (Fig. 2.70c)

- The body of the scapula should be at right angles to the image receptor, thus demonstrating the scapula and the proximal end of the humerus clear of the rib cage.
- The exposure should demonstrate the position of the head of the humerus in relation to the glenoid cavity between the coracoid and acromion processes.

Additional Considerations

- If the arm is immobilised and no abduction of the arm is possible, an anterior oblique projection may be taken as an alternative to an axial or apical oblique projection.

Shoulder – Anterior Oblique ('Y' Projection)

- Over- or under-rotation of the torso will result in superimposition of the rib cage over the region of interest.

Expected DRL: ESD 0.73 mGy



Figs 2.70a, b Positioning for an anterior oblique shoulder projection in the erect position and an alternative 'reverse' position for use on a trolley.

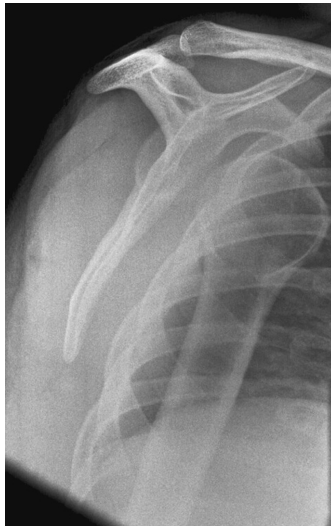

Fig. 2.70c Example of an anterior oblique 'Y' projection radiograph showing an anterior dislocation.

SINUSES – OCCIPITO-MENTAL

This projection is designed to project the petrous part of the temporal bone below the floor of the maxillary sinuses so that fluid levels or pathological changes in the lower part of the sinuses can be clearly visualised.

Position of Patient and Image Receptor (Fig. 2.71a)

- The projection is best performed with the patient seated facing the vertical Bucky/receptor.
- The patient's nose and chin are placed in contact with the midline of the receptor, and the head is then adjusted to bring the orbito-mental baseline into a 45-degree angle to the Bucky/receptor.
- The horizontal central line of the Bucky/receptor should be at the level of the lower orbital margins.
- The median sagittal plane is positioned at right angles to the Bucky/receptor by ensuring that the outer canthi of the eyes and the external auditory meatuses are equidistant.
- The patient should open their mouth as wide as possible prior to exposure. This will allow the posterior part of the sphenoid sinuses to be projected through the mouth.

Direction and Location of X-ray Beam

- The collimated horizontal beam should be centered on the Bucky/receptor before positioning is undertaken.
- To check the beam is properly centered, the crosslines on the Bucky/receptor should coincide with the patient's anterior nasal spine.
- Collimate to include all of the sinuses.

Essential Image Characteristics (Fig. 2.71b)

- The petrous ridges must appear below the floors of the maxillary sinuses.
- There should be no rotation.

Notes

- Always check the baseline angle immediately before exposure as this is an uncomfortable position for the patient to maintain.



Fig. 2.71a Positioning for occipito-mental sinus projection.

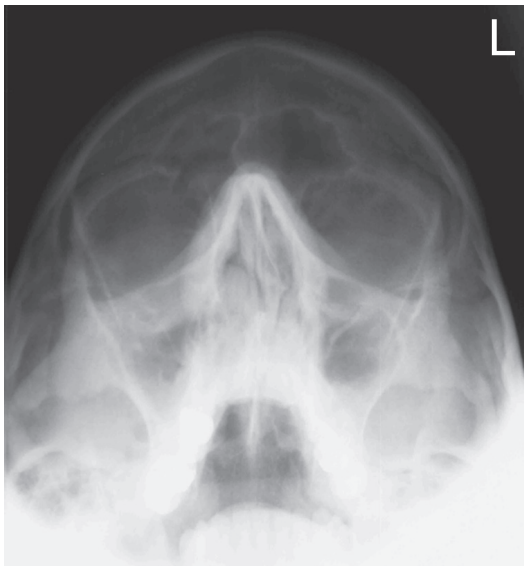


Fig. 2.71b Example of an occipito-mental sinus projection, showing a polyp in the right maxillary sinus.

SKULL – OCCIPITO-FRONTAL

Occipito-frontal projections can be undertaken with the patient erect or prone on the table.

Position of Patient and Image Receptor (Figs 2.72a, b)

- The patient is seated facing the erect Bucky/receptor so that the median sagittal plane is coincident with the midline of the image receptor and is also perpendicular to it.
- The neck is flexed so that orbito-meatal baseline is perpendicular to the image receptor. This can usually be achieved by ensuring that the nose and forehead are in contact with the Bucky/receptor. Ensure that the mid-part of the frontal bone is positioned in the centre of the Bucky/receptor.
- For stability, the patient may place the palms of each hand either side of the head (out of the primary beam).

Direction and Location of X-ray Beam

- The collimated horizontal beam is directed perpendicular to the Bucky/receptor along the median sagittal plane.
- The beam collimation should include the vertex of the skull superiorly, the region immediately below the base of the occipital bone inferiorly and the lateral skin margins. It is important to ensure the tube is centred on the Bucky receptor.

Essential Image Characteristics (Fig. 2.72c)

- All the cranial bones, including the skin margins, should be included within the image. It is important to ensure the skull is not rotated.

Additional Considerations

- This examination can be undertaken with a 10- or 20-degree caudal beam angulation; this will result in the petrous ridges appearing more inferiorly in the orbit.

Notes

- Patients often find it difficult to maintain or achieve their orbito-meatal baseline perpendicular to the image receptor as this is an uncomfortable position. Modifications in tube angulation may accommodate this.

Expected DRL: ESD 1.8 mGy



Fig. 2.72a Positioning for occipito-frontal skull projection.




Fig. 2.72b Positioning for occipito-frontal 20-degree caudal skull projection.

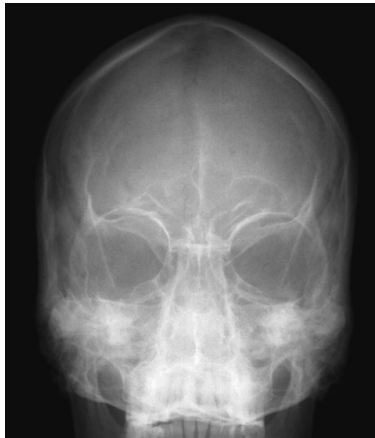

Fig. 2.72c Example of an occipito-frontal 20-degree caudal angulation skull projection.

SKULL – OCCIPITO-FRONTAL 30-DEGREE CRANIAL (REVERSE TOWNE'S)

Position of Patient and Image Receptor (Fig. 2.73a)

- This projection is usually undertaken with the patient in the erect position facing the erect Bucky/image receptor, although it may be performed with the patient prone on the X-ray table.
- Initially, the patient is asked to place their nose and forehead against the image receptor. The head is adjusted to position the median sagittal plane at right angles to the image receptor so it is coincident with its midline.
- The orbito-meatal baseline should be perpendicular to the image receptor.
- The patient may place their hands on the Bucky/receptor for stability.

Direction and Location of X-ray Beam

- The central ray is angled cranially so it makes an angle of 30 degrees with the orbito-meatal line. Adjust the collimation field such that the whole of the occipital bone and the parietal bones up to the vertex are included within the field. Avoid including the orbits in the primary beam.

Essential Image Characteristics (Fig. 2.73b)

- The sella turcica of the sphenoid bone is projected within the foramen magnum.
- The image must include all of the occipital bone, and the posterior parts of the parietal bone and lambdoid suture should be clearly visualised.
- The skull should not be rotated.

Additional Considerations

- The foramen magnum should be clearly visualised on this projection. The margins may be obscured by incorrect angulation, thus hiding important fractures.

Skull – Occipito-frontal 30-degree Cranial (Reverse Towne's)

- The zygoma may be well seen on this projection; the presence of a fracture gives a clue to the origin of associated facial injury.

Notes

- This projection carries a lower radiation dose to sensitive structures than the equivalent fronto-occipital 30-degree caudal projection.




Fig. 2.73a Positioning for a reverse Towne's projection.

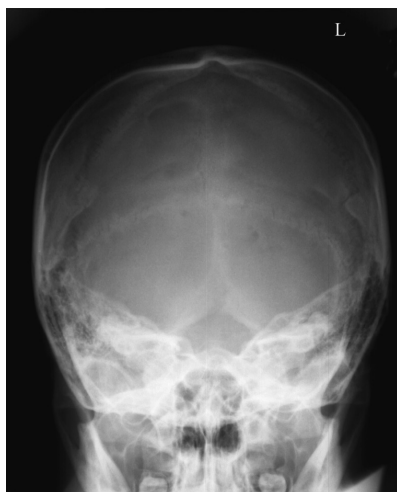

Fig. 2.73b Example of an occipito-frontal 30-degree cranial skull radiograph.

SKULL – LATERAL ERECT

This position may be used if the patient is cooperative.

Position of Patient and Image Receptor (Fig. 2.74a)

- The patient sits facing the erect Bucky/receptor, and the head is then rotated such that the median sagittal plane is parallel to, and the inter-pupillary line perpendicular to, the Bucky/receptor.
- The shoulders may be rotated slightly to allow the correct position to be attained, and the patient may grip the Bucky inferiorly for stability.
- Position the image receptor transversely such that its upper border is 5 cm above the vertex of the skull. A radiolucent pad may be placed under the chin or lower half of the face for support.

Direction and Location of X-ray Beam

- The X-ray tube should be centred on the Bucky/image receptor and the 'tracking' facility utilised if available.
- Adjust the height of the Bucky/tube so that the patient is comfortable. (NB Do not decentre the tube from the Bucky at this point.)
- Centre with a collimated horizontal beam midway between the glabella and the external occipital protuberance to a point approximately 5 cm superior and posterior to the external auditory meatus.

Essential Image Characteristics (Fig. 2.74b)

- The lateral floors of the cranial fossa should be superimposed by ensuring that the inter-orbital line is perpendicular to the cassette/receptor, and the median sagittal plane parallel to the receptor.

Additional Considerations

- This is not an easy position for the patient to maintain. Check the position of all planes immediately prior to the exposure as the patient may have moved.

Notes

- This projection can also be performed with the patient prone on a floating-top table with a collimated vertical beam.

Expected DRL: ESD 1.1 mGy



Fig. 2.74a Positioning for lateral skull projection.

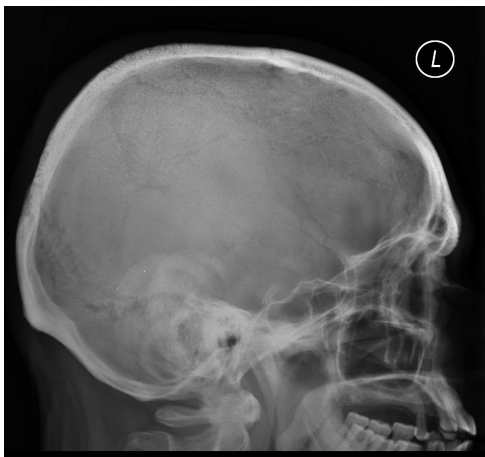


Fig. 2.74b Example of a lateral skull radiograph.

SKULL – FRONTO-OCCIPITAL (SUPINE/TROLLEY)

Fronto-occipital projections of the skull demonstrate the same anatomy as occipito-frontal projections. The orbits and frontal bone will, however, be magnified as they are positioned further from the image receptor.

Such projections should only be undertaken when the patient cannot be moved and must be imaged supine. These projections result in an increased radiation dose to the orbits and some loss of resolution of the anterior skull structures due to increased ORD.

Position of Patient and Image Receptor (Figs 2.75a, b)

- The patient lies supine on the trolley (or X-ray table) with the posterior aspect of the skull resting on the image receptor or gridded CR cassette.
- The head is adjusted to position the median sagittal plane at right angles to the image receptor and coincident with its midline. In this position, rotation is prevented by ensuring that the external auditory meatuses are equidistant from the image receptor.
- The orbito-meatal baseline should be perpendicular to the image receptor.

Direction and Location of X-ray Beam

- All angulations for fronto-occipital projections are made cranially.
- The collimated vertical X-ray beam is directed perpendicularly to the image receptor along the median sagittal plane.
- The collimated field should be set to include the vertex of the skull superiorly, the base of the occipital bone inferiorly and the lateral skin margins. It is important to ensure that the tube is centred on the image receptor and 'tracking' applied if available.

Essential Image Characteristics and Notes (Fig. 2.75c)

- These are the same as for occipito-frontal projections (see page 190).

Additional Considerations

- This examination can be undertaken with a 10- or 20-degree cranial beam angulation; this will result in the petrous ridges appearing more inferiorly in the orbit. For a fronto-occipital 20-degree cranial projection when the patient can only maintain the orbito-mental baseline at 10 degrees back from the perpendicular (i.e. with the chin raised slightly), a 10-degree cranial angulation is applied to the tube to achieve an overall 20-degree angle.

Expected DRL: ESD 1.8 mGy

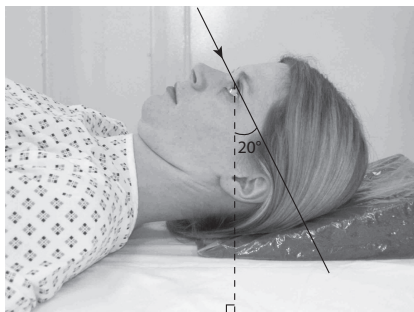


Fig. 2.75a Positioning for fronto-occipital 20-degree cranial skull projection.

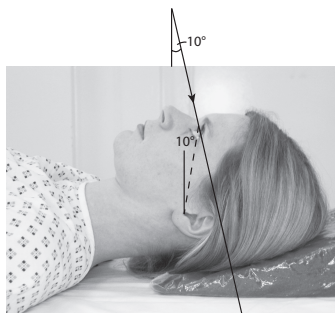


Fig. 2.75b A fronto-occipital 20-degree cranial skull projection achieved with a 10-degree tube angulation and the orbito-metal base line raised by 10 degrees.

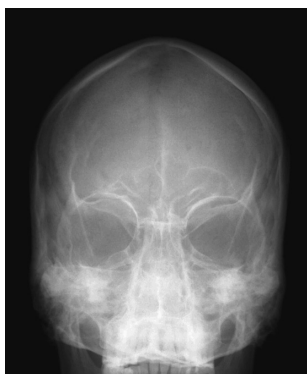

Fig. 2.75c Example of a fronto-occipital 20-degree cranial skull radiograph.

SKULL – FRONTO-OCCIPITAL 30-DEGREE CAUDAL (TOWNE'S PROJECTION) (SUPINE/TROLLEY)

Position of Patient and Image Receptor (Fig. 2.76a)

- The patient lies supine on a trolley (or X-ray table) with the posterior aspect of the skull resting on an image receptor or gridded CR cassette.
- The head is adjusted to position the median sagittal plane at right angles to the image receptor and so that it is coincident with its midline.
- The orbito-meatal baseline should be perpendicular to the image receptor.

Direction and Location of X-ray Beam

- The collimated vertical beam is angled caudally so it makes an angle of 30 degrees with the orbito-meatal plane.
- To avoid irradiating the eyes, the collimation is set to ensure that the lower border is coincident with the superior-orbital margin and the upper border includes the skull vertex. Laterally, the skin margins should also be included within the field. The top of the receptor should be positioned adjacent to the vertex of the skull to ensure that the beam angulation does not project the area of interest off the bottom of the image.

Essential Image Characteristics (Fig. 2.76b)

- The sella turcica of the sphenoid bone is projected to appear within the foramen magnum. The image must include all of the occipital bone, and the posterior parts of the parietal bone and the lamboidal suture should be clearly visualised. The skull should not be rotated.

Additional Considerations

- The foramen magnum should be clearly seen on this projection. The margins may be obscured by incorrect angulation, thus hiding serious fractures.

Notes

- Some of the 30-degree angle required for this projection can be achieved using a skull board. If a 30-degree board is used and the patient's orbito-meatal baseline is perpendicular to the top of the board, a vertical central ray should be employed.

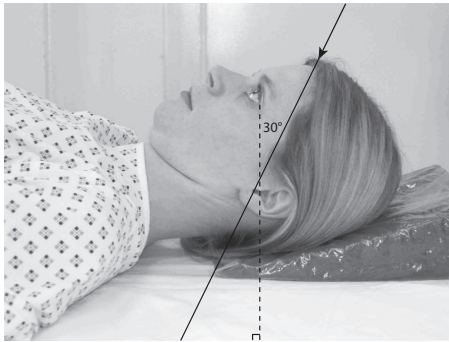


Fig. 2.76a Positioning for fronto-occipital 30-degree caudal skull projection.

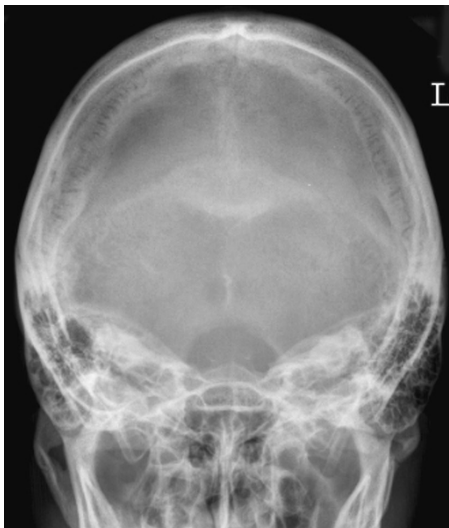

Fig. 2.76b Example of a fronto-occipital 30-degree caudal skull radiograph.

SKULL – LATERAL (SUPINE/TROLLEY)

Position of Patient and Image Receptor (Fig. 2.77a)

- The patient lies supine with the head raised and immobilised on a non-opaque skull pad. This will ensure that the occipital region is included on the image.
- The head is adjusted such that the median sagittal plane is perpendicular to the table/trolley and the inter-pupillary line is perpendicular to the image receptor.
- The image receptor is supported vertically against the lateral aspect of the head (region of interest) parallel to the median sagittal plane, with its edge 5 cm above the vertex of the skull.

Direction and Location of X-ray Beam

- The collimated horizontal beam is directed parallel to the inter-pupillary line such that it is at right angles to the median sagittal plane.
- The centring point is midway between the glabella and the external occipital protuberance at a point approximately 5 cm superior and posterior to the external auditory meatus.
- The long axis of a CR cassette, if used, should be coincident with the long axis of the skull.

Essential Image Characteristics (Fig. 2.77b)

- These are as for 'Skull – lateral erect' (see page 194).

Additional Considerations

- Skull imaging as previously mentioned is used to identify brain injury that cannot be assessed by skull radiography, so the prime modality currently used is a CT scan.
- The choice of which lateral to image will depend on the site of the suspected pathology. The side with the suspected pathology should be adjacent to the image receptor. This will ensure the pathology is shown at the maximum resolution possible as geometrical lack of sharpness will be minimised. This is the projection of choice for the majority of trauma patients on a trolley if CT has not been undertaken.

Expected DRL: ESD 1.1 mGy

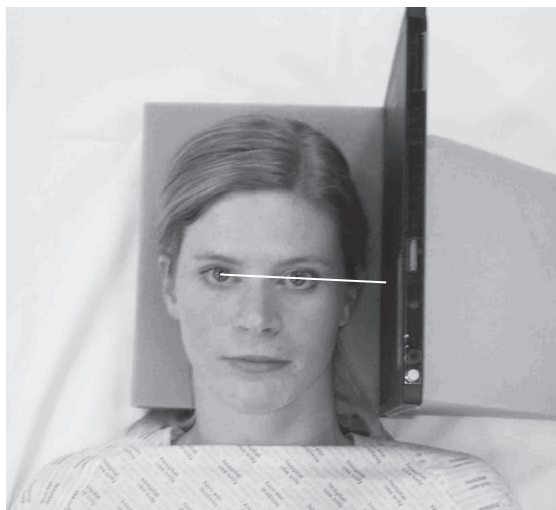

Fig. 2.77a Positioning for lateral supine skull (anterior aspect) projection.

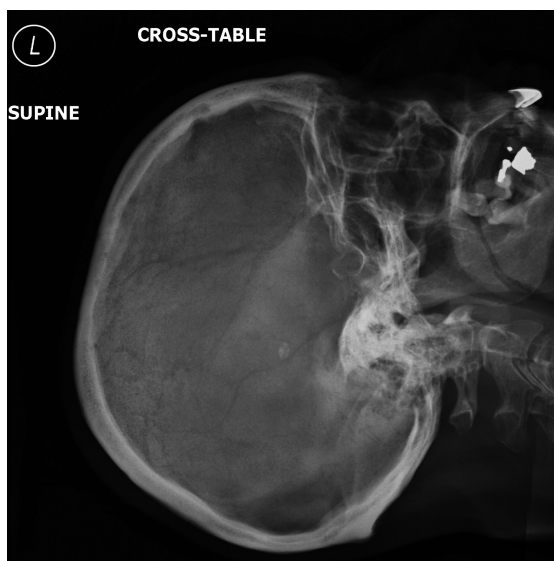


Fig. 2.77b Example of a lateral skull radiograph.

SKULL 'HEAD' – CT

Indications

- This projection is used with acute head trauma, a suspected intracranial bleed, stroke, tumour, metastases, shunt malfunctions and when MRI is contraindicated

Positioning of Patient and Imaging Modality (Fig. 2.78a)

- The patient lies supine on the scanner table with their head resting in the head support and their arms by their sides. Positioning is aided by the axial, coronal and sagittal laser lights to ensure that the patient is positioned in the central axis of the scanner.
- The orbito-meatal baseline is positioned parallel to the transverse alignment light, and the median sagittal plane is perpendicular to the table and coincident with the sagittal alignment light.
- To ensure that the skull is symmetrically positioned, the external auditory meatuses must be equidistant from the head support, and the inter-pupillary line parallel to the scan plane. The head is secured by Velcro straps.
- To commence the initial lateral 'localiser' scan, the patient is moved into the gantry of the scanner until the scan reference point is at the level of the symphysis menti.

Imaging Procedure

- Using the lateral scan 'localiser' image, CT acquisition is obtained, starting 5 cm below and ending 12 cm above the radiographic baseline, i.e. scanning from the base to the vertex of the skull.
- A typical protocol for a 64-slice scanner is collimation 0.6 mm, slice acquisition 4.8 mm/4.8 mm and reconstruction 1.2 mm/1.2 mm soft tissue and bone algorithms. Local protocols may, however, differ.
- If contrast enhancement is required, this will usually be given by hand injection and then the same examination protocol repeated.

Image Analysis (Figs 2.78b, c)

- The images are reviewed for space-occupying lesions, haemorrhage or hydrocephalus, normal basal ganglia and posterior fossa structures, major vessel vascular territory infarct, intra- or extra-axonal collections, patency of the basal cisterns and foramen magnum, status of air cells of the petrous temporal bone and the presence of any fractures.

Example of a protocol for contrast medium and injection data:

Volume	Concentration	Flow rate
50 mL	300 mg I/mL	by hand

Radiation Protection/Dose

Dose-reduction techniques include automatic exposure control (mA) and iterative slice reconstruction. To reduce or avoid exposure of the ocular lens, the patient's chin is tucked down, and the gantry may also be angled if the scanners permit.

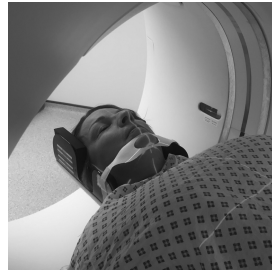

Fig. 2.78a Positioning for lateral CT of the head.

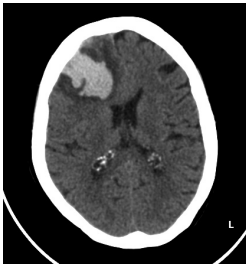


Fig. 2.78b Axial CT image demonstrating an intracerebral haemorrhage of the right frontal lobe with surrounding oedema causing a small mass effect.

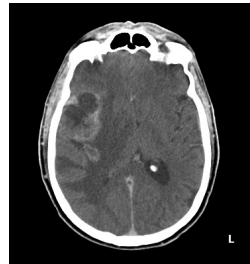


Fig. 2.78c Contrast-enhanced axial CT image demonstrating a large temporo-parietal space-occupying lesion with severe peritumoural oedema and mild shift of the midline.

STERNUM – LATERAL

Position of Patient and Image Receptor (Fig. 2.79a)

- A vertical Bucky DDR system is employed, or a 24 cm × 30 cm CR cassette is selected for use in the Bucky mechanism.
- The patient sits or stands, with either shoulder against a vertical Bucky or image receptor stand.
- The median sagittal plane of the trunk is adjusted parallel to the image receptor.
- The sternum is centred on the image receptor.
- The patient's hands are clasped behind the back, and the shoulders are pulled well back immediately before exposure.
- The image receptor is centred at a level 2.5 cm below the sternal angle.
- If the patient is standing, the feet should be separated to aid stability.
- An FRD of 120–150 cm is selected to reduce magnification.

Direction and Location of X-ray Beam

- The collimated horizontal beam is centred towards a point 2.5 cm below the sternal angle and should include the manubrium, body and xiphoid process of the sternum.
- Exposure is made on arrested full inspiration.

Essential Image Characteristics (Fig. 2.79b)

- This can be a difficult examination to interpret, especially in elderly patients, who often have heavily calcified costal cartilages.
- The image should demonstrate the full extent of the sternum, including the manubrium, body and xiphoid process.
- The contrast and density should be optimised to demonstrate the cortical margins of the sternum.

Additional Considerations

- This projection is usually taken in conjunction with a chest radiograph to search for a pneumothorax in trauma cases. Remember that the initial interpretation is often done in the emergency department by inexperienced observers; therefore, care should be exercised to ensure that the sternum is projected in the true lateral position as this is important for accurate interpretation.

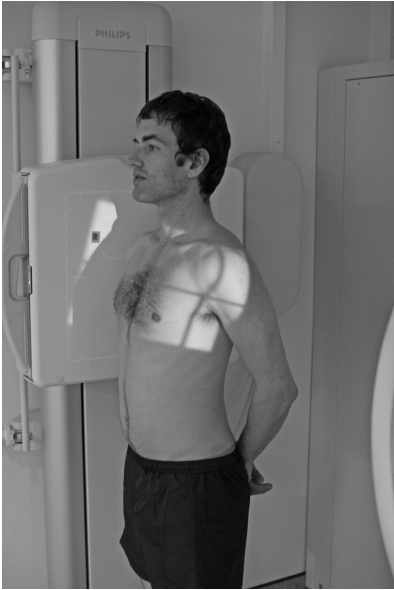


Fig. 2.79a Positioning for lateral sternum projection.

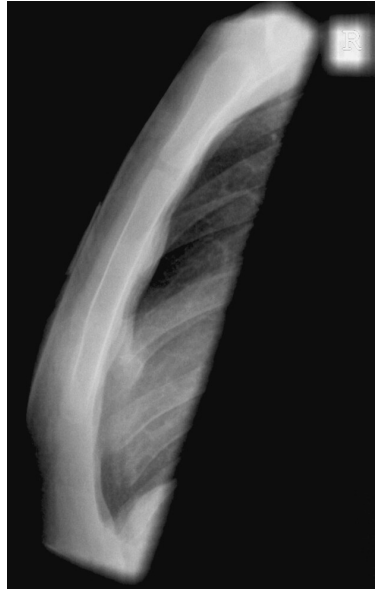

Fig. 2.79b Example of a lateral sternum radiograph.

THORACIC SPINE – ANTERO-POSTERIOR

Position of Patient and Image Receptor (Fig. 2.80a)

- The patient is positioned supine on the X-ray table, with the median sagittal plane perpendicular to the table top and coincident with the midline of the Bucky.
- The upper edge of the image detector or cassette (which should be at least 40 cm long for an adult), should be at a level just below the prominence of the thyroid cartilage to ensure that the upper thoracic vertebrae are included.
- Exposure is made on arrested inspiration. This will cause the diaphragm to move down over the upper lumbar vertebra, thus reducing the chance of a large difference in density appearing on the image from superimposition of the lungs.

Direction and Location of X-ray Beam

- Direct the collimated vertical central ray at right angles to the image receptor and towards a point 2.5 cm below the sternal angle.
- The beam is collimated tightly to the spine.

Essential Image Characteristics (Fig. 2.80b)

- The image should include the vertebrae from C7 to L1.
- The imaging factors should be sufficient to demonstrate bony detail for the upper as well as the thoracic lower vertebrae.

Additional Considerations

- The image receptor and beam are often centred too low, thereby excluding the upper thoracic vertebrae from the image.
- The lower vertebrae are also often not included. L1 can be identified easily by the fact that it will usually not have a rib attached to it.

Expected DRL: DAP 1.0 Gy·cm², ESD 3.5 mGy

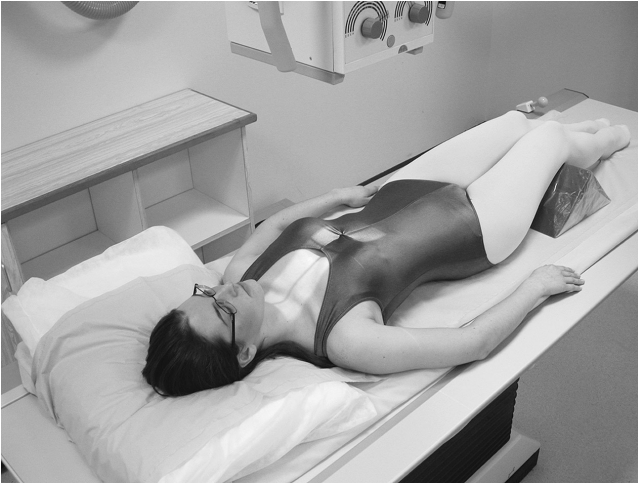

Fig. 2.80a Positioning for antero-posterior thoracic spine projection.

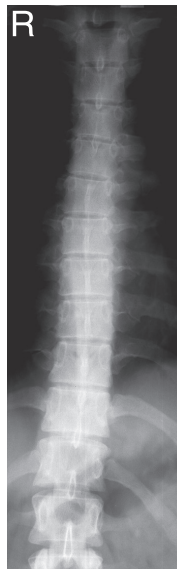

Fig. 2.80b Example of a normal antero-posterior thoracic spine radiograph.

THORACIC SPINE – LATERAL

Position of Patient and Image Receptor (Fig. 2.81a)

- The examination is usually undertaken with the patient in the lateral decubitus position on the X-ray table, although this projection can also be performed erect.
- The median sagittal plane should be parallel to the image receptor and the midline of the axilla coincident with the midline of the table or Bucky.
- The patient's arms should be raised well above the head.
- The head can be supported with a pillow, and pads may be placed between the knees for the patient's comfort.
- The upper edge of the image detector or cassette (which should be at least 40 cm in length) and should be positioned 3–4 cm above the spinous process of C7.

Direction and Location of X-ray Beam

- The collimated vertical beam should be at right angles to the long axis of the thoracic vertebrae. This may (rarely) require a caudal angulation.
- The collimated beam is centred on a point 5 cm anterior to the spinous process of T6/T7. This is usually found just below the inferior angle of the scapula (assuming the patient's arms are raised), which is easily palpable.

Essential Image Characteristics (Fig. 2.81b)

- The upper two or three vertebrae may not be demonstrated due to superimposition of the shoulders.
- Look for the absence of a rib on L1 at the lower border of the image. This will ensure that T12 has been included within the field.
- The posterior ribs should be superimposed, thus indicating that the patient was not rotated too far forwards or backwards.

Expected DRL: DAP 1.5 Gy·cm², ESD 7 mGy



Fig. 2.81a Positioning for lateral thoracic spine projection.

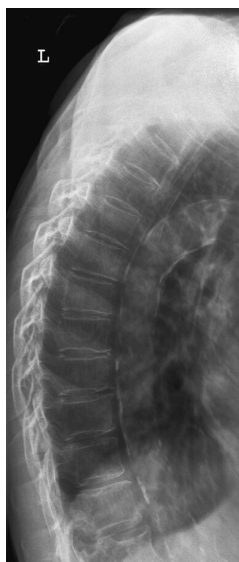

Fig. 2.81b Example of a normal lateral thoracic spine radiograph.

THUMB – ANTERO-POSTERIOR

Position of Patient and Image Receptor (Fig. 2.82a)

- The patient is seated facing away from the table with the arm extended backwards and medially rotated at the shoulder.
- The hand may be slightly rotated to ensure that the second, third and fourth metacarpals are not superimposed on the base of the first metacarpal.
- The patient leans forwards, lowering the shoulder so that the first metacarpal is parallel to the table top.
- The image receptor is placed under the wrist and thumb and oriented to the long axis of the metacarpal.

Direction and Location of X-ray Beam

- The collimated vertical beam is centred over the first metacarpophalangeal joint.

Essential Image Characteristics (Fig. 2.82b)

- Where there is a possibility of injury to the base of the first metacarpal, the carpo-metacarpal joint must be included on the image.

Additional Considerations

- The image should include the tip of the thumb and the distal third of the metacarpal bone.

Notes

- The postero-anterior projection increases the ORD and hence, potentially, the lack of sharpness, but it is sometimes easier and less painful for the patient.
- The use of the postero-anterior projection maintains the relationship between the adjacent bones, i.e. the radius and ulna, which is essential in cases of suspected foreign body in the thenar eminence.

Expected DRL: ESD 0.064 mGy

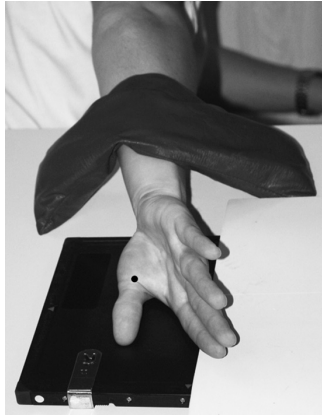

Fig. 2.82a Positioning for antero-posterior thumb projection.

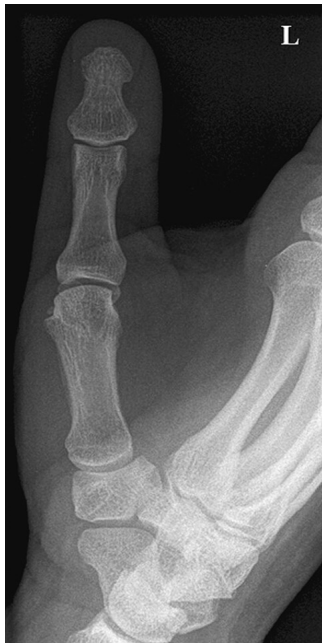

Fig. 2.82b Example of an antero-posterior thumb radiograph.

THUMB – LATERAL

Position of Patient and Image Receptor (Fig. 2.83a)

- The patient is seated alongside the table with the arm abducted, the elbow flexed and the anterior aspect of the forearm resting on the table.
- The thumb is flexed slightly and the palm of the hand is placed on the image receptor.
- The palm of the hand is raised slightly, with the fingers partially flexed and supported on a non-opaque pad, such that the lateral aspect of the thumb is in contact with the image receptor.

Direction and Location of X-ray Beam

- The collimated vertical beam is centred over the first metacarpophalangeal joint.

Essential Image Characteristics (Fig. 2.83b)

- Where there is a possibility of injury to the base of the first metacarpal, the carpo-metacarpal joint must be included on the image.
- The image should include the tip of the thumb and the distal third of the metacarpal bone.

Notes

- It is common practice to obtain two projections, a lateral and an antero-posterior.
- In the case of a suspected foreign body in the thenar eminence, a postero-anterior projection is used to maintain the relationship with the adjacent structures.

Expected DRL: ESD 0.064 mGy



Fig. 2.83a Positioning for lateral thumb projection.

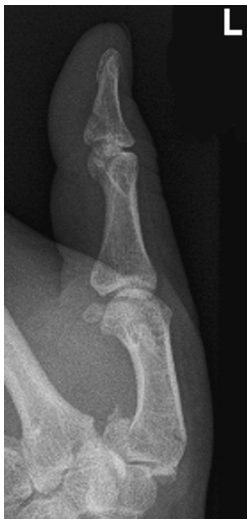

Fig. 2.83b Example of a lateral thumb radiograph.

TIBIA AND FIBULA – ANTERO-POSTERIOR

Position of Patient and Image Receptor (Fig. 2.84a)

- The receptor chosen should be large enough to accommodate the entire length of the tibia and fibula. This may require the leg to be positioned diagonally across the receptor to ensure the knee joint and ankle mortise are visualised on the image.
- The patient is either supine or seated on the X-ray table, with both legs extended.
- The ankle is supported in dorsiflexion by a firm 90-degree pad placed against the plantar aspect of the foot. The limb is rotated medially until the medial and lateral malleoli are equidistant from the receptor.
- The lower edge of the receptor is positioned just below the plantar aspect of the heel.

Direction and Location of X-ray Beam

- The collimated vertical beam is centred on the mid-shaft of the tibia, with the central ray at right angles to both the long axis of the tibia and an imaginary line joining the malleoli.

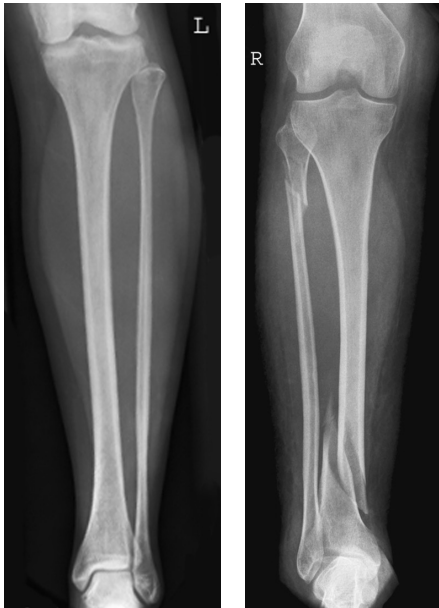Essential Image Characteristics (Figs 2.84b, c)

- The knee and ankle joints must be included, since the proximal end of the fibula may also be fractured when there is a fracture of the distal fibula or tibia or widening of the mortise joint (Maisonneuve fracture). If a fracture of either the tibia or fibula is seen, with overlap or shortening, the entire length of both bones must be demonstrated (because of the bony ring rule).

Expected DRL: ESD 0.15 mGy




Fig. 2.84a Positioning for antero-posterior projection of tibia and fibula.



Figs 2.84b, c Examples of antero-posterior tibia and fibula radiographs. Image (c) demonstrates proximal fibular and distal tibial fractures.

TIBIA AND FIBULA – LATERAL

Position of Patient and Image Receptor (Fig. 2.85a)

- From the supine/seated position, the patient rotates onto the affected side.
- The leg is rotated further until the malleoli are superimposed vertically.
- The tibia should be parallel to the image receptor.
- A pad is placed under the knee for support.
- The lower edge of the receptor is positioned just below the plantar aspect of the heel.
- The receptor chosen should be large enough to accommodate the entire length of the tibia and fibula. This may require the leg to be positioned diagonally across the receptor to ensure that the knee joint and ankle joint are included.

Direction and Location of X-ray beam

- The collimated vertical beam is centred on the mid-shaft of the tibia, with the central ray at right angles to the long axis of the tibia and parallel to an imaginary line joining the malleoli.

Essential Image Characteristics (Figs 2.85b, c)

- The knee and ankle joints should be included on the image.

Additional Considerations

- If it is impossible to include both joints on one image, two images should be exposed separately, one to include the ankle and the other to include the knee. Both images should include the middle third of the lower leg so the general alignment of the bones may be seen.
- If it is impossible for the patient to rotate onto the affected side, an adapted technique method should be used, with the receptor supported vertically against the medial side of the leg and the beam directed horizontally to the mid-shaft of the tibia.

Expected DRL: ESD 0.16 mGy



Fig. 2.85a Positioning for lateral tibia and fibula projection.

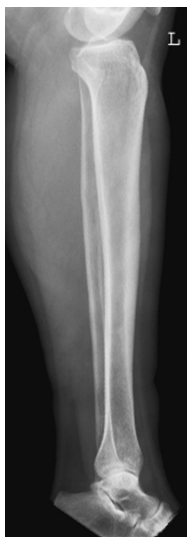

Fig. 2.85b Example of a normal tibia and fibula radiograph.

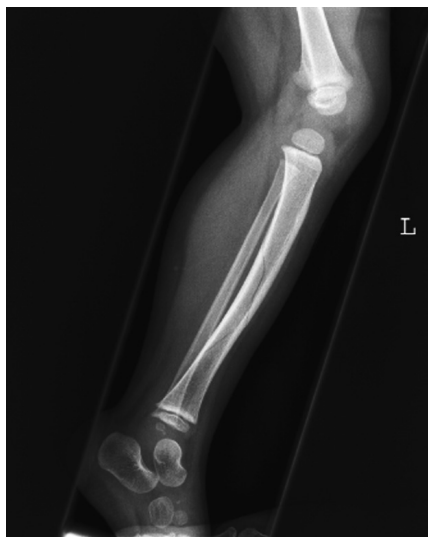

Fig. 2.85c Radiograph of a paediatric tibia and fibula, showing a fracture.

TOE – HALLUX – LATERAL

Position of Patient and Image Receptor (Fig. 2.86a)

- From the dorsi-plantar position, the foot is rotated medially until the medial aspect of the hallux is in contact with the receptor.
- A bandage is placed around the remaining toes (provided no injury is suspected) and they are gently pulled forwards by the patient to clear the hallux.
- Alternatively, they may be pulled backwards. This shows the metatarso-phalangeal joint more clearly.

Direction and Location of X-ray Beam

- The collimated vertical central beam is directed over the first metatarso-phalangeal joint.

Essential Image Characteristics (Fig. 2.86b)

- The distal and proximal phalanges, together with the distal two-thirds of the first metatarsal should be demonstrated.
- The first metatarso-phalangeal joint and interphalangeal joint should be seen clearly, with superimposition of the condyles of the head of the proximal phalanx.
- The use of this projection is important for hyperflexion (stubbing) injuries as an undisplaced avulsion fracture of the distal phalanx of the great toe can be missed on dorsi-plantar and dorsi-plantar oblique projections. It is important that the second to fifth toes are being pulled away sufficiently to prevent superimposition of the remaining toes on the base of the proximal phalanx.

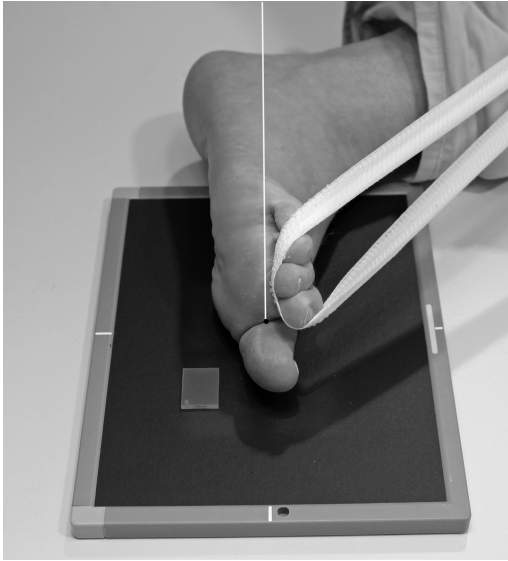


Fig. 2.86a Positioning for lateral projection of hallux.

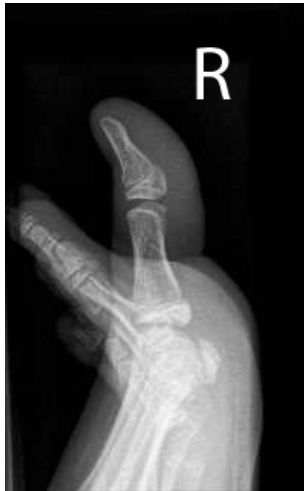

Fig. 2.86b Example of a lateral hallux radiograph.

TOES – DORSI-PLANTAR

Position of Patient and Image Receptor (Fig. 2.87a)

- The patient is seated on the X-ray table, supported if necessary, with the hips and knees flexed.
- The plantar aspect of the affected foot is placed on the receptor. The receptor may be raised by 15 degrees by using a pad (CR) or angling the receptor (direct digital radiography stand).
- The leg may be supported in the vertical position by the other knee.

Direction and Location of X-ray Beam

- The collimated vertical central beam is directed over the third metatarso-phalangeal joint, perpendicular to the receptor if all the toes are to be imaged.
- For single toes, the vertical ray is centred over the metatarso-phalangeal joint of the individual toe and collimated to include the toe either side.

Essential Image Characteristics (Fig. 2.87b)

- The image should demonstrate the full area of interest, including the distal phalanges and proximal metatarsal region.
- A uniform radiographic contrast across the area of interest is desirable.

Additional Considerations

- It is common practice to obtain two projections, a dorsi-plantar and a dorsi-plantar oblique.
- True lateral projections of the toes are generally not requested except in the case of the big toe, for which dorsi-plantar and lateral projections are the accepted standard.

Expected DRL: ESD 0.076 mGy

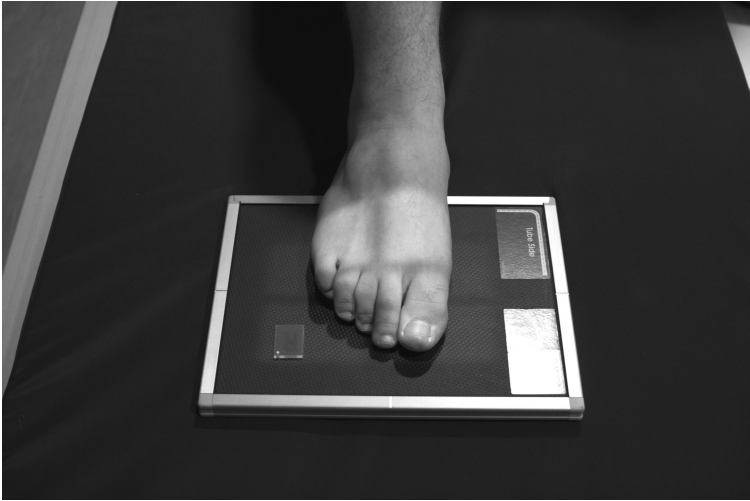


Fig. 2.87a Positioning for dorsi-plantar toe projection.

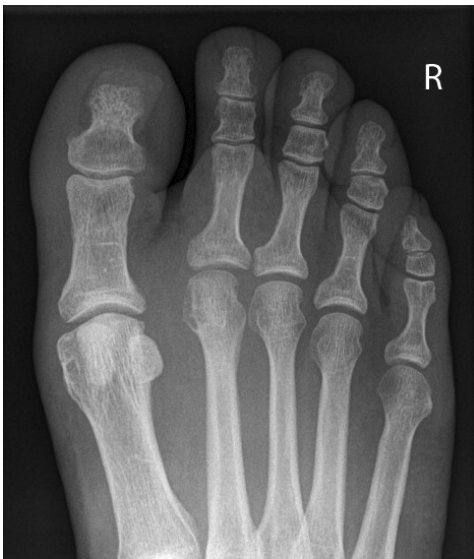

Fig. 2.87b Example of a normal dorsi-plantar toe radiograph.

TOES – SECOND TO FIFTH – DORSI-PLANTAR OBLIQUE

Position of Patient and Image Receptor (Fig. 2.88a)

- From the basic dorsi-plantar position, the affected limb is allowed to lean medially to bring the plantar surface of the foot into a position of approximately 45 degrees to the receptor.
- A 45-degree non-opaque pad is placed under the side of the foot for support, with the opposite leg acting as a support.

Direction and Location of X-ray Beam

- The collimated vertical central beam is centred over the first metatarso-phalangeal joint if all the toes are to be imaged and is angled sufficiently to allow the central ray to pass through the third metatarso-phalangeal joint.
- For single toes, the vertical ray is centred over the metatarso-phalangeal joint of the individual toe, perpendicular to the receptor. The collimated field should include the adjacent toe(s) to the toe in question.

Essential Image Characteristics (Fig. 2.88b)

- The image should demonstrate the full area of interest, including the distal phalanges and proximal metatarsal region.
- A uniform radiographic contrast across the area of interest is desirable.

Additional Considerations

- Ensure the foot is not over-rotated medially, which may result in the toes overlapping each other.

Expected DRL: ESD 0.076 mGy

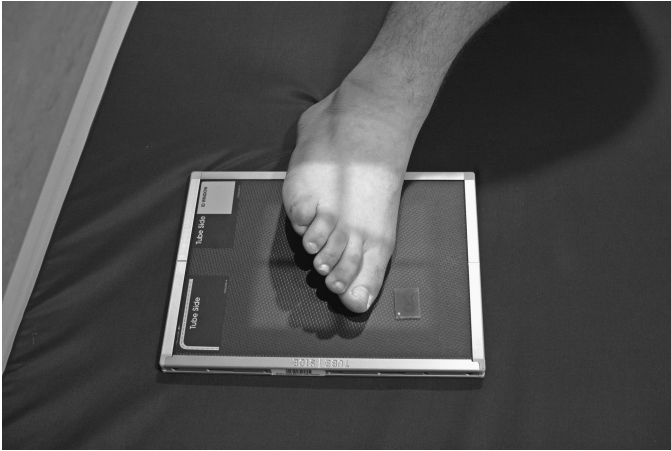


Fig. 2.88a Positioning for dorsi-plantar oblique toes projection.

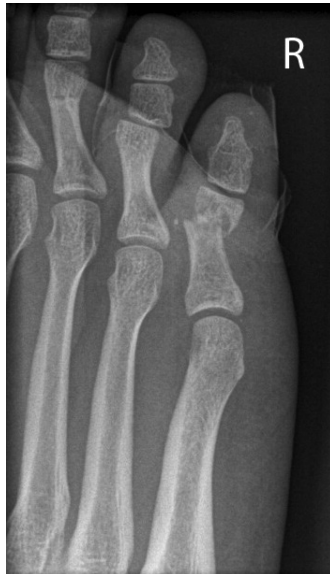

Fig. 2.88b Collimated dorsi-plantar oblique image of the fifth toe, showing a fracture of the proximal phalanx.

WRIST – POSTERO-ANTERIOR

Position of Patient and Image Receptor (Fig. 2.89a)

- The patient is seated alongside the table, with the affected side nearest to the table.
- The elbow joint is flexed to 90 degrees and the arm is abducted, such that the anterior aspect of the forearm and the palm of the hand rest on the image receptor.
- If the patient's mobility allows, the shoulder joint should be at the same height as the forearm.
- The wrist joint is placed central to the image receptor and adjusted to include the lower part of the radius and ulna and the proximal two-thirds of the metacarpals.
- The fingers are flexed slightly to bring the anterior aspect of the wrist in contact with the image receptor.
- The wrist joint is adjusted to ensure that the radial and ulnar styloid processes are equidistant from the image receptor.
- The forearm is immobilised using a sandbag.

Direction and Location of X-ray Beam

- The collimated vertical beam is centred on a point midway between the radial and ulnar styloid processes.

Essential Image Characteristics (Fig. 2.89b)

- The image should demonstrate the proximal two-thirds of the metacarpals, the carpal bones and the distal third of the radius and ulna.
- There should be no rotation of the wrist joint.

Notes

- When the image is undertaken for a scaphoid view, the wrist should be in ulnar deviation.

Expected DRL: ESD 0.072 mGy



Fig. 2.89a Positioning for postero-anterior wrist projection.

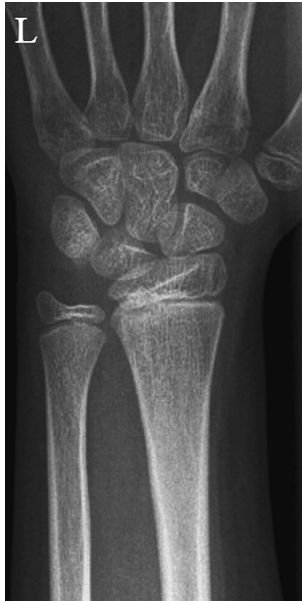

Fig. 2.89b Radiograph of a normal postero-anterior wrist radiograph.

WRIST – LATERAL

Position of Patient and Image Receptor (Fig. 2.90a)

- The patient is seated alongside the table with the affected side nearest to the table.
- The elbow joint is extended to bring the medial aspect of the forearm, wrist and hand in contact with the table.
- The wrist joint is positioned to include the lower part of the radius and ulna and the proximal two-thirds of the metacarpals on the image receptor.
- The hand is rotated slightly further externally to ensure that the radial and styloid processes are superimposed.
- The forearm is immobilised using a sandbag.

Direction and Location of X-ray Beam

- The collimated vertical beam is centred over the styloid process of the radius.

Essential Image Characteristics (Fig. 2.90b)

- The image should demonstrate the proximal two-thirds of the metacarpals, the carpal bones and the distal third of the radius and ulna.
- There should be no rotation of the wrist joint.

Notes

- If the elbow is extended rather than at right angles, it is often easier to rotate the wrist into a lateral position.

Expected DRL: ESD 0.082 mGy

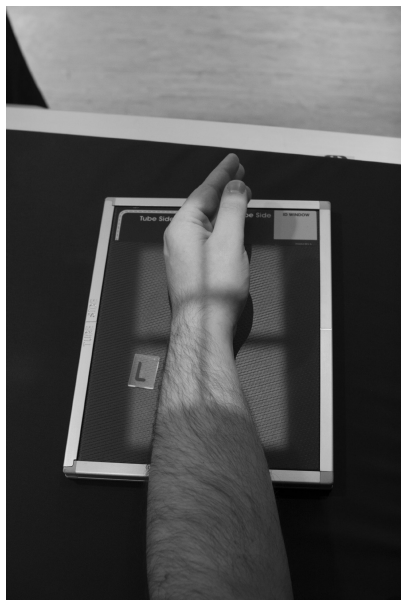

Fig. 2.90a Positioning for lateral wrist projection.

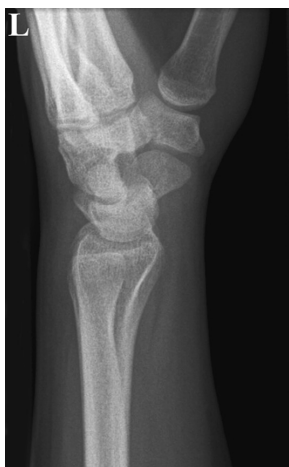

Fig. 2.90b Example of a lateral wrist radiograph.

ZYGOMATIC ARCHES – INFERO-SUPERIOR

This projection is essentially a modified submento-vertical projection. It is often referred to as the 'jug handle' projection of the zygomatic arch, which is demonstrated in profile.

Position of Patient and Image Receptor (Fig. 2.91a)

- The patient lies supine with one or two pillows under the shoulders to allow the neck to be fully extended.
- An 18 cm × 24 cm CR cassette is placed against the vertex of the skull such that its long axis is parallel to the axial plane of the body. It should be supported in this position with foam pads and sandbags.
- Neck flexion is then adjusted to bring the long axis of the zygomatic arches parallel to the CR cassette.
- The head is then tilted 5–10 degrees away from the side under examination. This allows the zygomatic arch under examination to be projected onto the image without superimposition of the skull vault or facial bones.

Direction and Location of X-ray Beam

- The central ray should be perpendicular to the CR cassette and long axis of the zygomatic arch. A centring point should be located such that the central ray passes through the space between the midpoint of the zygomatic arch and the lateral border of the facial bones. Close collimation should be applied to reduce scatter and avoid irradiating the eyes.

Essential Image Characteristics (Fig. 2.91b)

- The zygomatic arch injured should be fully demonstrated clear of the cranium.

Additional Considerations

- A depressed fracture of the zygoma can be missed clinically due to soft tissue swelling making the bony defect less obvious. Radiography has an important role in ensuring that potentially disfiguring depression of the cheek bones is not overlooked.

- If the patient can tolerate the position, this projection may be taken with the patient erect and their skull vertex resting against the erect Bucky.

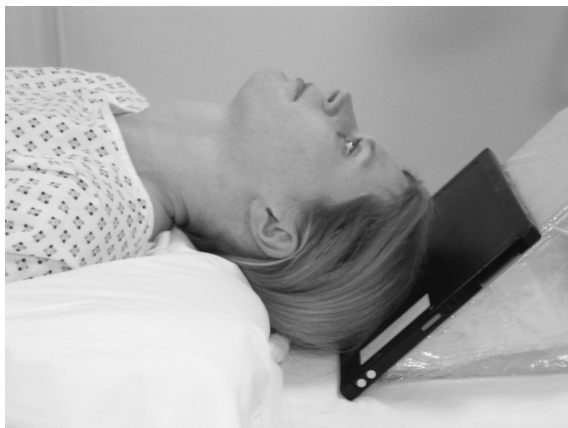

Fig. 2.91a Positioning for zygomatic arc projection.

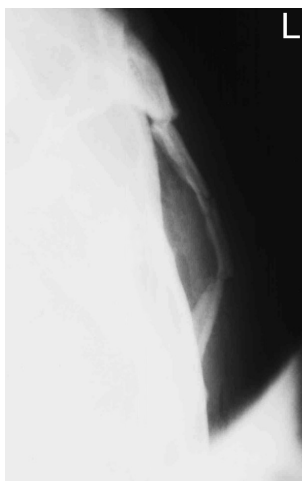

Fig. 2.91b Example of a zygomatic arch radiograph (localised), demonstrating a comminuted fracture.



Taylor & Francis

Taylor & Francis Group

<http://taylorandfrancis.com>

SECTION 3

USEFUL INFORMATION FOR RADIOGRAPHIC PRACTICE

Non-Imaging Diagnostic Tests	232
Medical Terminology	234
Medical and Radiographic Abbreviations	237

NON-IMAGING DIAGNOSTIC TESTS

The following blood tests are commonly performed as part of the diagnostic process. The results may have an impact upon the appropriateness of certain imaging procedures or raise suspicions of particular pathology. The reader should consult local departmental protocols for guidance in relation to some of these tests and their significance.

D-dimer

A test that measures the levels of products from the degradation of fibrin within blood clots. Raised D-dimer levels increase the suspicion of conditions such as pulmonary embolism and deep vein thrombosis. Low D-dimer levels can be used to exclude the possibility of these conditions and the need to perform expensive imaging tests.

INR: International Normalised Ratio

This is a measure of the time taken for the blood to clot. A normal result is approximately 1, but patients taking anticoagulant drugs may have values of 2.0–3.5. Invasive diagnostic tests, such as angiography, may be contraindicated with patients with a high INR due to the subsequent risk of haemorrhage (see local departmental protocols for guidance).

e-GFR: Estimated Glomerular Filtration Rate

This is used to measure renal function and the health of the kidneys. It takes into account variables such as age, sex and serum creatinine concentrations. Levels of greater than 90 mL/min/1.73 m² are considered normal. Levels below this value indicate impaired renal function.

ESR: Erythrocyte Sedimentation Rate

This non-specific test measures the time taken for red blood cells to settle in a thin tube of liquid. Various diseases affect the ability of the cells to do this and increase the time taken for the cells to settle. Examples include diseases causing inflammation, autoimmune diseases, cancers and myeloma. Typical normal values for adults are 10–20 mm/h. This value varies considerably with age. Values of over 100 mm/h are of significant concern.

Serum Creatinine

Creatinine is a metabolic waste product that is excreted from the blood plasma by the kidneys. A raised serum creatinine concentration indicates impaired renal function (normal levels typically being 0.6–1.2 mg/dL). Patients with raised serum creatinine levels may have an increased risk of renal failure if iodinated contrast agents are administered (see local departmental protocols for guidance).

LFTs: Liver Function Tests

This group of tests is used to assess the overall health of the liver and biliary system. Abnormal tests can give early indications of serious conditions. If the liver is diseased and the cells are damaged, various enzymes will be released into the blood stream, e.g. alanine transaminase (alanine aminotransferase) and alkaline phosphatase. Disease may also affect the ability of the liver to produce albumin. High levels of bilirubin in the blood indicate jaundice.

PSA: Prostate-specific Antigen

This is an enzyme produced by the prostate gland that can be measured in the blood. A raised PSA level can indicate the presence of prostate cancer, although the test can be misleading as some men with raised PSA values may not have cancer, and some with normal levels may actually have the disease. A value of 3.0–4.0 ng/mL or below is considered normal.

CA125: Cancer Antigen 125

CA125 is used to diagnose ovarian cancer. The normal range is 0–35 U/mL. Values above this do not always indicate the presence of a tumour but certainly indicate the need for further investigations.

hCG: Human Chorionic Gonadotropin

This hormone is produced by the placenta and can be measured in the blood or urine to confirm an early pregnancy. Raised levels of hCG in the absence of pregnancy may indicate a tumour.

MEDICAL TERMINOLOGY

The following list of common prefixes and suffixes can be employed to work out the meaning of complex disease terminology encountered on requests for radiological examinations.

Prefixes

A- or an-	absence of or without
Adreno-	relating to the adrenal glands
Angio-	relating to blood or lymph vessels
Ante-	in front or before
Arterio-	relating to arteries
Bi-	two
Brady-	slow
Bucc-	relating to the cheek
Burs-	relating to bursa within synovial joints
Cardi-	relating to the heart
Cephal-	relating to the head
Cebr-	relating to the brain
Cervic-	neck
Chol-	relating to the biliary system or bile
Crani-	relating to the skull
Cysto-	relating to the bladder or gall bladder
Dacro-	relating to tears and their associated glands or ducts
Dacry-	relating to tears
Demi-	half
Dorsi-	back
Dys	difficulty
Ec-	away from or not in the usual position
Endo-	inside or within
Ente-	relating to the intestine
Epi-	upon
Erythro-	reddening or flushing of
Ex-	out of
Gastr-	relating to the stomach
Gingiv-	relating to the gums

Haem-	relating to the blood
Hemi-	half
Hydro-	water
Hyper-	beyond normal limits
Hypo-	below normal limits
Hystro-	relating to the uterus
Idio-	relating to an individual or self
Infra-	below
Inter-	between
Intra-	within
Iso-	the same as
Lact-	relating to milk
Laparo-	relating to the abdominal wall
Leuco <i>or</i> leuko-	relating to white blood cells
Lingu-	relating to the tongue
Lipo-	relating to fat
Litho-	stone formation
Lympho-	relating to the lymphatic system
Lysis-	destruction of
Macro-	large
Mammo <i>or</i> masto-	relating to the breast
Mega-	enlargement of
Myo-	relating to muscle
Neo-	new
Nephro-	relating to the kidney
Neuro-	relating to the nervous system
Orchid-	relating to the testes
Osteo-	relating to the bones
Peri-	around
Phleb-	relating to the veins
Pneumo-	relating to the lungs
Poly-	many
Post-	after
Pyo-	relating to pus
Retro-	behind
Salpingo-	relating to the uterine tubes
Sial-	relating to the salivary glands
Spleno-	relating to the spleen

Useful Information for Radiographic Practice

Spondy-	relating to the spine
Sub-	beneath
Supra-	above, upper
Syn-	together
Tachy-	too fast
Trach-	relating to the trachea
Trans-	through
Urin- <i>or</i> uro-	relating to the urinary system or urine
Vesico-	relating to the bladder

Suffixes

-aemia	disease affecting the blood
-algia	pain
-ectasis	enlargement or widening of
-ectomy	surgical removal of
-itis	inflammation of
-oma	tumour
-oscopy	visual examination of
-ostomy	surgical opening of
-osis	disease of
-penia	lack of
-plasty	repair or reconstruction
-rrhoea	flow

MEDICAL AND RADIOGRAPHIC ABBREVIATIONS

AAA	abdominal aortic aneurysm
ACL	anterior cruciate ligament
AE	air entry
AF	atrial fibrillation
AFP	alpha-fetoprotein
ALL	acute lymphocytic leukaemia
AML	acute myelogenous leukaemia
AP	antero-posterior
ARDS	acute respiratory distress syndrome
ASD	atrial septal defect
AVM	arteriovenous malformation
AXR	abdomen X-ray
BE	barium enema
BI	bony injury
BMI	body mass index
BP	blood pressure
Ca	cancer
CT	computed tomography
CABG	coronary artery bypass graft
CAT	computed axial tomography
CBD	common bile duct
CN	cranial nerve
CO	complains of
COPD	chronic obstructive pulmonary disease
CPR	cardiopulmonary resuscitation
CSF	cerebrospinal fluid
CVA	cerebrovascular accident (stroke)
CVP	central venous pressure
CXR	chest X-ray

Useful Information for Radiographic Practice

D&V	diarrhoea and vomiting
D&C	dilation and curettage
DDx	differential diagnosis
DIP	distal interphalangeal (joint)
DNA	did not attend <i>or</i> deoxyribonucleic acid
DRL	diagnostic reference level
DVT	deep vein thrombosis
Dx	diagnosis
DXT	deep X-ray treatment
ECG	electrocardiogram
ECT	electroconvulsive therapy
EDD	estimated date of delivery
ENT	ear, nose and throat
ERCP	endoscopic retrograde cholangio-pancreatography
ESR	erythrocyte sedimentation rate
ET	endotracheal
FB	foreign body
FBC	full blood count
FH	family history
FO	fronto-occipital
FTT	failure to thrive
FUO	fever of unknown origin
GCS	Glasgow Coma Scale
GFR	glomerular filtration rate
GIT	gastrointestinal tract
GU	gastric ulcer <i>or</i> genitourinary
Hb	haemoglobin
HI	head injury
HIV	human immunodeficiency virus
Hx	history of
IAM	internal auditory meatus
ID	identification
IDDM	insulin-dependent diabetes mellitus

IDK	internal derangement of the knee
IM	intramedullary or intramuscular
IVC	inferior vena cava <i>or</i> intravenous cholangiogram
IVP	intravenous pyelogram
IVU	intravenous urogram
KUB	kidneys, ureters and bladder
LAO	left anterior oblique
LLL	left lower lobe
LMP	last menstrual period
LOC	loss of consciousness
LP	lumbar puncture
LUL	left upper lobe
LUQ	left upper quadrant
LVF	left ventricular failure
MCP	metacarpophalangeal
MI	myocardial infarction
MRI	magnetic resonance imaging
MRSA	methicillin-resistant <i>Staphylococcus aureus</i>
MS	multiple sclerosis <i>or</i> mitral stenosis
NAD	no abnormality detected
NBI	no bony injury
NBM	nil by mouth
NFR	not for resuscitation
NFS	no fracture seen
NG	nasogastric growth <i>or</i> new growth
NIDDM	non-insulin-dependent diabetes mellitus
NMR	nuclear magnetic resonance
NSAID	non-steroidal anti-inflammatory drugs
OA	osteoarthritis
OE	on examination
OF	occipito-frontal
OM	occipito-mental
ORIF	open reduction and internal fixation

Useful Information for Radiographic Practice

PA	postero-anterior
PACS	picture archiving and communication system
PE	pulmonary embolus
PID	prolapsed intervertebral disc <i>or</i> pelvic inflammatory disease
PIJ	proximal interphalangeal joint
PNS	postnasal space
POP	plaster of Paris
PR	per (via) the rectum
PRN	as often as needed
PTCA	percutaneous transluminal coronary angioplasty
PUO	pyrexia of unknown origin
PV	per (via) the vagina
RA	rheumatoid arthritis
RAO	right anterior oblique
RBC	red blood cell
RIS	radiology information system
RLL	right lower lobe
RML	right middle lobe
ROI	region of interest
RPA	radiation protection advisor
RPS	radiation protection supervisor
RT	radiotherapy
RTC	road traffic collision
RUL	right upper lobe
RUQ	right upper quadrant
Rx	prescription
SAH	subarachnoid haemorrhage
SBE	subacute bacterial endocarditis
SLE	systemic lupus erythematosus
SMV	submento-vertical
SOB	shortness of breath
SOL	space-occupying lesion
STD	sexually transmitted disease
STI	sexually transmitted infection
Sx	symptoms
SXR	skull X-ray

TB	tuberculosis
TFT	thyroid function test
THR	total hip replacment
TIA	transient ischaemic attack
TKR	total knee replacement
TMJ	temporo-mandibular joint
TPR	temperature, pulse and respiration
TURP	transurethral resection of prostate
Tx	treatment
U&E	urea and electrolytes
UC	ulcerative colitis
URTI	upper respiratory tract infection
US	ultrasound
UTI	urinary tract infection
VF	ventricular fibrillation
V/Q	lung perfusion/ventilation scan
VSD	ventricular septal defect
VT	ventricular tachycardia
WBC	white blood cell count
YO	years old
0	not present
+	present
++	significantly present
+++	substantially present
↑/↓	increase/decrease
#	fracture
1/7	1 day
2/52	2 weeks
3/12	3 months



Taylor & Francis

Taylor & Francis Group

<http://taylorandfrancis.com>

INDEX

- abdominal X-ray projections
 - antero-posterior supine 47–9
 - left lateral decubitus 50–1
- acromio-clavicular joint X-ray projection 52–3
- aftercare 15
- alternative imaging modalities 22
- anatomical side marker 17, 30
- anatomical terminology 2–5
 - anatomical position 2, 3
 - landmarks 4, 5
 - lines 4, 5
 - patient aspect 2, 3
 - planes of the body 2, 3
- ankle, inversion injury 54
- ankle X-ray projections
 - antero-posterior/mortise joint 54–5
 - lateral 56–7
- anthropological baseline 4, 5
- apophyseal joint 152
- apophysis, unfused, of the base of the fifth metatarsal 110
- artefacts 32
 - foreign body 160
 - grid ‘cut off’ 70
- aspect, patient 2, 3
- atlanto-occipital joint 64, 72
- atlas 62, 64
- automatic exposure control 48, 171, 203
- avulsion fractures 110, 124, 218
- barrier nursing 44
- beam energy, optimum 23
- bony ring rule 35, 214
- bowel
 - gas 48, 50
 - obstruction 50
 - pattern 47
- boxer’s fracture 122
- calcaneum 54, 56, 58–9, 112
 - fracture 59
- calcaneum X-ray projection
 - axial 58–9
- cancer antigen 125 (CA125) 233
- carpal bones 118, 120, 226
 - fracture 174
- carpo-metacarpal joint 118, 210, 212
- caudal angulation 10, 76, 94, 191, 208
- central ray 10, 12
- cervical spine X-ray projections
 - antero-posterior C1–C2
 - ‘open mouth’ 62–3
 - antero-posterior C3–C7 60–1
 - extension and flexion 72–3
 - lateral erect 64–5
 - lateral supine 68–9
 - lateral ‘swimmers’ 66–7
 - posterior oblique 70–1
- chest X-ray projections
 - antero-posterior erect 76–7
 - antero-posterior mobile/trolley 82–3
 - antero-posterior supine 80–1
 - lateral 78–9
 - postero-anterior 74–5
- chip fracture 104, 106
- clavicle, fracture 87

Index

- clavicle X-ray projections
 - infero-superior 86–7
 - postero-anterior 84–5
- clinical history 14, 19, 23, 33, 34
- clinical report 16, 34, 42
- Clostridium difficile* 43
- collimation 28, 32, 60
- comment system 34
- contra-coup fracture 159
- coracoid process 180, 182, 184, 186
- costo-phrenic angles 50, 75, 78
- cranial bones 190

- D-dimer 232
- dens 62
- diagnostic reference levels (DRLs) 23, 24, 25, 26–7, 32
 - adult recommended national reference doses 27
 - dose expression 26
- digital image acquisition systems 31
- dislocation 34, 35
 - fracture, C5–C6 69
 - shoulder 187
- dorsiflexion
 - ankle 54, 214
 - foot 9, 140

- elbow
 - flexion and extension 8
 - joint effusion 35
- elbow X-ray projections
 - alternate antero-posterior projections for trauma 90–1
 - antero-posterior 88–9
 - lateral 92–3
- erythrocyte sedimentation rate (ESR) 232
- estimated glomerular filtration rate (e-GFR) 232

- evaluating images ('10-point plan') *see* [image evaluation](#)
- external auditory meatus 4, 5
- external occipital protuberance 4, 5

- facial bones X-ray projections 96
 - occipito-mental 94–5
 - occipito-mental 30-degree caudal 96–7
 - see also* [mandible X-ray projections](#); [zygomatic arch X-ray projection](#)

- femur
 - fracture 98, 126, 127, 128
 - and hip projections 124, 126, 130, 132
 - and knee projections 138
- femur X-ray projections
 - antero-posterior 98–9
 - lateral 100–1

- fibula
 - and ankle projections 54, 56
 - fracture 214, 215
 - and knee projections 138, 140
 - rotation 56, 140
- fibula X-ray projections
 - antero-posterior 214–15
 - lateral 216–17

- film/screen systems 31, 108, 124
- filter 127
 - wedge 108

- finger
 - fracture 104, 106
 - and hand projections 118, 120
 - index 103
 - mallet 104, 106
- fingers X-ray projections
 - dorsi-palmar 102–3
 - lateral index and middle 104–5, 106, 107
 - lateral ring and little 106–7

- finger tip 102, 104, 106
 - soft tissue 118, 120
- flexion
 - cervical spine 72–3
 - defined 8, 9
 - knee 142, 146
 - neck 228
- foot, fracture 110
- foot X-ray projections
 - dorsi-plantar 108–9
 - dorsi-plantar oblique 110–11
 - lateral erect 112–13
 - see also toe X-ray projections*
- foramen magnum 192, 198, 203
- forearm X-ray projections
 - antero-posterior 114–15
 - lateral 116–17
- foreign body
 - in hand 122, 123
 - markers 122, 123
 - in orbit 160, 161
 - in thenar eminence 210, 212
- fracture
 - dislocation of C5–C6 69
 - flagging of 34
 - indirect signs 35
 - second 35
 - see also under named bones*
- glabella 4, 5, 194, 200
- glenohumeral joint 182, 184
- glenoid cavity 180, 182, 184, 186
- gonads 6, 124, 133, 147, 165, 166, 178
- Grashey projection 182–3
- hallux
 - lateral X-ray projection 218–19
- hand
 - and abdomen projections 50
 - and cervical spine projections 64
 - and chest projections 74
- hand (*continued*)
 - and elbow projections 88, 92
 - and finger projections 102, 104, 106
 - and forearm projections 114, 116
 - and lumbar spine projections 152
 - and lumbo-sacral junction projections 154
 - and sacrum projections 170
 - and scaphoid projections 172, 174, 176
 - and skull projections 190, 192
 - and sternum projections 204
 - and thumb projections 210, 212
 - washing 37, 43, 44
 - and wrist projections 224, 226
- hand X-ray projections
 - dorsi-palmar 118–19
 - dorsi-palmar oblique 120–1
 - lateral 122–3
- heart 75, 76, 78
- hip
 - and femur projections 98, 100, 126–7
 - and foot projections 108
 - fracture 130
 - and knee projections 142
 - and lumbar spine projections 148, 150, 152
 - and lumbosacral junction 154
 - prosthesis 101
 - and sacrum projections 170
 - and toe projections 220
- hip X-ray projections
 - antero-posterior, single hip 124–5
 - ‘frog’s leg’ lateral, both hips 132–3
 - lateral air-gap technique 128–9
 - posterior oblique (Lauenstein’s) 130–1

Index

- human chorionic gonadotropin (hCG) 233
- humerus
 - and cervical spine
 - projections 66
 - and elbow projections 88, 92
 - and forearm projections 114, 116
 - fracture 92, 134, 135, 137
 - and shoulder girdle projections 180, 182
 - and shoulder projections 184, 186
- humerus X-ray projections
 - antero-posterior 134–5
 - lateral 136–7
- iliac
 - crests 47, 126, 154, 164, 170
 - spines, anterior superior 47, 124, 130, 132, 148, 154, 164, 166, 168
 - spines, posterior superior 154, 166, 170
- image evaluation ('10-point plan') 14, 30–3
 - anatomical variations and pathological appearances 33
 - area of interest 30
 - artefacts 32
 - collimation 32
 - correct exposure 31–2
 - correct projections 30–1
 - markers and legends 30
 - optimum definition 32
 - patient identification 30
 - repeat radiographs or further projections 32–3
- image interpretation, guidelines 34–5
- immobilisation collars 72
- infection
 - control 39, 43–4
 - prevention of 41
- infra-orbital line 4, 5
- infra-orbital margin 4
- inspiration
 - and abdomen X-rays 47
 - and chest X-rays 74, 75, 76, 78
 - and sternum X-rays 204
 - and thoracic spine X-rays 206
- international normalised ratio (INR) 232
- inter-orbital (inter-pupillary) line 4, 5
- inverse square law 38, 42
- Ionising Radiation (Medical Exposure) Regulations (IR(ME)R) 22, 24, 26, 42
- isolation nursing 44
- kidneys 232, 233
- knee
 - and ankle projections 54, 56
 - and femoral projections 98, 99, 100, 101
 - and foot projections 108
 - and hip projections 126, 128, 130, 132
 - loose bodies 144
 - and lumbar spine projections 148, 150, 152
 - and lumbo-sacral projections 154
 - retropatellar joint 146
 - and sacral projections 168, 170
 - and thoracic spine projections 208
 - and tibia/fibula projections 214, 216
 - and toe projections 220
 - see also patella
- knee X-ray projections
 - antero-posterior 138–9
 - horizontal beam lateral 142–3
 - joint effusion 143
 - lateral 140–1

- knee X-ray projections (*continued*)
 'skyline' patellar
 (supero-inferior) 146–7
 tunnel/intercondylar notch
 144–5
- legends 16, 30
- legislation 16, 21–22, 24
- lines used in skull radiography
 anthropological baseline 4, 5
 infra-orbital 4, 5
 inter-orbital
 (inter-pupillary) 4, 5
 orbito-meatal (radiographic)
 baseline 4, 5
- lipohaemarthrosis 35, 142
- liver function tests (LFTs) 233
- loose bodies, knee 144
- lower orbital margin 94, 96, 188
- lumbo-sacral junction (L5–S1)
 lateral X-ray projection 154–5
- lumbar spine X-ray projections
 anteroposterior 148–9
 lateral 150–1
 and lumbo-sacral junction 150
 oblique 152–3
- lumbar vertebra 78, 148,
 206, 208
 'Scottie dog' appearance 152
- lung 50, 74, 75, 76, 148, 206
 apices 76, 80
 bases 80
 margins 78, 80
 and nasogastric tube 42
 tissues 78
- Maisonneuve fracture 214
- malleolus 54, 56
 fracture 56
- mandible
 and cervical spine
 projections 64, 70
 fracture 156, 158
- mandible X-ray projections
 postero-anterior 156–7
 lateral oblique 30-degree cranial
 (supine) 158–9
- marker
 anatomical side 17, 30
 foreign body 122, 123
 red dot 34
- mastoid process 62, 64, 68
- maxillary sinus 94, 95, 96, 160,
 188, 189
- medical and radiographic
 abbreviations 237–41
- medical terminology
 prefixes 234–6
 suffixes 236
- metacarpals
 boxer's fracture 122
 and finger projections 102,
 104, 106
 fracture, fifth 123
 and hand projections 118,
 120, 122
 hot-spot 35
 and scaphoid projections 172,
 174, 176
 and thumb projections 210, 212
 and wrist projections 224, 226
- metacarpo-phalangeal (MCP) joint
 and hand projections 118
 and thumb projections 210, 212
- metatarsals
 and ankle projections 54, 56
 and calcaneum projections 58
 and foot projections 108,
 110, 112
 fracture, fifth 56
 hot-spots 35
 and toe projections 218, 220, 222
- mobile radiography 36, 38, 40,
 41, 42
 and chest projections 82–3
- MRSA 37, 43

Index

- nasion 4, 5
- neck
 - flexion and extension 8
 - soft tissues 64, 65, 72
 - see also* cervical spine X-ray
 - projections
- noise (image) 18, 32, 100
- non-imaging diagnostic tests 232–3
 - cancer antigen 125
 - (CA125) 233
 - D-dimer 232
 - estimated glomerular filtration rate (e-GFR) 232
 - erythrocyte sedimentation rate (ESR) 232
 - human chorionic gonadotropin (hCG) 233
 - international normalised ratio (INR) 232
 - liver function tests (LFTs) 233
 - prostate-specific antigen (PSA) 233
 - serum creatinine 232, 233
- olecranon, fracture 90
- optimum factors/results 18, 23, 24, 31, 32, 42, 84
- orbits 160, 192, 196
 - blow-out fracture 160
 - floors 94, 96, 160
 - orbital margins 96, 188
 - and skull projections 196
- orbito-meatal/radiographic baseline 4, 5
 - patient position 96, 156, 160, 188, 190, 191, 192, 196, 197, 198, 199, 202
- orbit X-ray projection
 - occipito-mental (modified) 160–1
- orthopantomography/dental panoramic tomography (OPG/DPT) 156, 162–3
- outer canthus of the eye 4
 - patient position 94, 96
- pars interarticularis 152
- patella
 - and femur projections 98
 - fracture 142, 143
 - and knee projections 138, 140, 142, 143, 144, 146, 147
- patello-femoral joint 146
- patient
 - clinical history 14, 19, 23, 33, 34
 - consent 14, 19–20
 - examination timeline 14–16
 - identity 14, 19, 30, 37, 38, 41, 82
 - communicating with 14, 15, 17, 24
 - request card 19, 21, 30
 - journey 14–16
- patient aspect
 - anterior 2, 3
 - lateral 2, 3
 - medial 2, 3
 - posterior/dorsal 2, 3
- pattern recognition 35
- pelvis
 - and abdomen projections 47
 - and chest projections 80
 - and femur projections 100
 - and hip projections 124, 126, 128, 132
 - protection 28
 - and sacrum projections 168
 - second fracture 35
- pelvis X-ray projection
 - antero-posterior 164–5
- petrous ridge 94, 95, 160, 188, 190, 197
- picture archiving and communication system (PACS) 18, 34, 37, 38, 41, 42

- planes of the body
 - coronal 2, 3
 - median sagittal 2, 5
 - parasagittal 2
 - and positioning 6
 - sagittal 2, 3
 - transverse/axial 2, 3
- pleural effusion 80, 83
- pneumothorax 75, 80, 204
- positioning terminology 6–9
 - abduction 8, 9
 - adduction 8, 9
 - decubitus 6, 7
 - erect 6, 7
 - eversion 9
 - extension 8, 9
 - flexion 8, 9
 - inversion 9
 - lateral decubitus 6, 7
 - pronation 8, 9
 - prone 6, 7
 - rotation 8
 - semi-recumbent 6
 - supination 8, 9
 - supine 6, 7
- pregnancy
 - minimising radiation risks in 28
 - 'pregnancy rule' 29
- projection terminology
 - anterior oblique 12, 13
 - antero-posterior 10, 11
 - beam angulation 10
 - lateral 10
 - lateral oblique 12, 13
 - latero-medial 10
 - left lateral 7, 10
 - medio-lateral 10
 - oblique 12
 - oblique using beam angulation 12, 13
 - posterior oblique 12, 13
 - postero-anterior 10, 11
 - right lateral 7, 10, 11
- prostate-specific antigen (PSA) 233
- protocols
 - department 17, 19, 37, 64, 232, 233
 - and isolation/barrier nursing 44
 - local 16, 21, 27, 43, 72, 133, 202
 - patient identification 41
- radial head, fracture 90
- radiation dose
 - and collimation 17, 28, 32, 38, 129
 - and gonads 6, 124, 133, 147, 165, 166, 178
 - high-dose procedures 29, 78, 170, 196
 - low-dose procedures 29, 193
 - minimising 23–4, 28
 - and mobile X-rays 42
 - optimisation 24, 26
 - and pregnancy 28–9
 - protection 23–5, 28, 36, 38–9, 40, 42, 82, 124, 133, 147, 165, 203
 - recording 18, 39
 - reducing 38, 48, 129, 166, 203
 - reference doses on adults 27
 - and regulations 22, 24, 39
 - risks 21, 22
 - quantities 25
 - see also* diagnostic reference levels (DRLs)
- radiology information system (RIS) 41
- radius
 - and elbow projections 32, 88, 92
 - and forearm projections 114, 116
 - and hand projections 118, 120, 122
 - and scaphoid projections 172, 174, 176
 - and thumb projections 210
 - and wrist projections 224, 226

Index

- Raynaud's disease 104, 106
- receptor size 17
- red blood cell 232
- red dot, use of 34
- region of interest 66, 148, 187, 200
- regulations *see* Ionising Radiation (Medical Exposure) Regulations (IR(ME)R)
- renal function 232, 233
- repeat radiographs 16, 32
- request card/forms 14, 19, 21, 23, 30
- rib
 - and chest projections 75
 - and clavicle projections 86
 - and humerus projections 136
 - and shoulder projections 186, 187
 - and thoracic spine projections 206, 208
- risk of X-rays 22, 24, 28, 32, 39
- sacro-iliac joints X-ray projection
 - postero-anterior 166–7
- sacrum, fracture 170
- sacrum X-ray projections
 - antero-posterior 168–9
 - lateral 170–1
- scaphoid
 - delayed avascular necrosis of the distal pole 178
 - fracture 172, 178
 - joint space 172
- scaphoid X-ray projections
 - anterior oblique with ulnar deviation 174–5
 - posterior oblique 176–7
 - postero-anterior, ulnar deviation and 30-degree cranial 178–9
 - postero-anterior with ulnar deviation 172–3
- second fracture 35
- serum creatinine 232, 233
- shoulder
 - and cervical spine
 - projections 66, 68, 70, 72
 - and chest projections 74
 - and clavicle projections 84, 86
 - dislocation 187
 - and elbow projections 92
 - and forearm projections 114
 - and humerus projections 134, 136
 - and orthopantomography 162
 - and sacrum projections 168
 - and scaphoid projections 172
 - and skull projections 194
 - and sternum projections 204
 - and thoracic spine
 - projections 208
 - and thumb projections 210
 - and wrist projections 224
 - and zygomatic arch
 - projections 228
- shoulder girdle X-ray projections
 - antero-posterior (15-degree) 180–1
 - antero-posterior (glenohumeral joint), modified (Grashey projection) 182–3
- shoulder X-ray projections
 - anterior oblique ('Y' projection) 186–7
 - supero-inferior (axial) 184–5
- sinuses X-ray projection
 - occipito-mental 188–9
- skull
 - fracture 192, 198, 203
 - lines and landmarks 5–6
 - and zygomatic arch projection 228, 229
- skull X-ray projections
 - fronto-occipital 30-degree caudal (Towne's projection) (supine/trolley) 198–9

- skull X-ray projections (*continued*)
 fronto-occipital (supine/trolley)
 196–7
 ‘head’ – CT 202–3
 lateral erect 194–5
 lateral (supine/trolley) 200–1
 occipito-frontal 190–1
 occipito-frontal 30-degree
 cranial (reverse Towne’s)
 192–3
see also zygomatic arch X-ray
 projection
- spine
 unstable 72
see also cervical spine X-ray
 projections; lumbar
 spine X-ray projections;
 thoracic spine X-ray
 projections
- sterile procedures 39
- sternoclavicular joint 180
- sternum X-ray projection
 lateral 204–5
- subtalar joint 58
- supracondylar 90, 92, 134
- symphysis menti 60, 96, 156,
 158, 202
- talus, and ankle X-rays 54, 56
- tarsal joint 108
- tarsometatarsal joint 108, 110
- theatre radiography 36–9
 effective communication 36–7
 effective use of equipment 36
 key skills 36
 personal preparation 37
 sterile procedures/infection
 control 39
 time out 37
see also picture archiving and
 communication system
 (PACS); radiation dose
- thenar eminence 210, 212
- thoracic spine X-ray projections
 antero-posterior 206–7
 lateral 208–9
- thoracic vertebrae 206, 208
 and cervical spine
 projections 64, 66, 68, 70
 and chest projections 74
 and lumbar spine projections
 148
- thumb X-ray projections
 antero-posterior 210–11
 lateral 212–13
- tibia, fracture 214, 215
- tibia X-ray projections
 antero-posterior 214–15
 lateral 216–17
- toe fractures
 fifth 223
 great 218
- toe X-ray projections
 dorsi-plantar 220–1
 hallux – lateral 218–19
 second to fifth, dorsi-plantar
 oblique 222–3
see also foot X-ray projections
- trauma cases
 ankle 54
 assessment guidelines 34–5
 cervical spine 68, 70, 72
 elbow 90–1
 fingers 104, 106
 foot 108
 forearm 116
 hip 126–7
 knee 142–3
 mandible 156
 pelvic 165
 shoulder 184
 skull 200, 202
 sternum 204
 trochanter 124, 126, 127, 164

Index

- ulna
 - and elbow projections 88, 92
 - and forearm projections 114, 115, 116
 - and hand projections 118, 120, 122
 - and scaphoid projections 172–3, 174–5, 176, 178–9
 - and thumb projections 210
 - and wrist projections 224, 226
- underexposure 31, 32, 48, 122, 170, 171
- unstable spine 72
- vertebral column 148, 150, 154
 - see also* lumbar spine X-ray projections; lumbo-sacral junction X-ray projections
- wedge
 - filter 108
 - use of 54, 158
- wrist
 - and elbow projections 92
 - wrist (*continued*)
 - and finger projections 102
 - and forearm projections 114, 115, 116
 - and hand projections 118, 122
 - and scaphoid projections 172, 174, 176, 178
 - and thumb projections 210
 - wrist X-ray projections
 - lateral 226–7
 - postero-anterior 224–5
- X-ray examinations
 - general considerations 17
 - justification 21–22
 - preparation 14, 17, 24, 37
 - stages 14
 - timeline/checklist 14, 16
 - X-ray room 14, 16, 17, 23, 24, 26
- zygomatic arch, fracture 95, 228, 229
- zygomatic arch X-ray projection
 - infero-superior 228–9